

# Sternal Fixation With Synthes® Titanium Sternal Fixation System Using Preoperative 3-Dimensional Planning and a Patient-Specific Surgical Guide.

Filip Haenen<sup>1</sup>, Roemer Vos<sup>1</sup>, and Edgar Daeter<sup>1</sup>

<sup>1</sup>Sint Antonius Ziekenhuis

May 6, 2020

## Abstract

Sternal refixation or reconstruction of a median sternotomy can be indicated after treatment of deep sternal wound infection or bony non-union. Synthes® Titanium Sternal Fixation System is routinely used for sternal refixation. To perform a stable reconstruction, the titanium plates need to be bent to the anatomical shape of the sternum and adjacent ribs. The procedure offers good results, but can be, especially in the case of a complex non-union or a complex anatomy, time-consuming. Based on pre-operative CT-scan a 3D model of the sternum was printed (Materialise, Belgium). The operation was simulated using 3D software (Materialise, Belgium) and the two parts were aligned. The titanium plates were bent to fit the anatomical shape of the 3D model pre-operatively. During surgery the plates were fitted and if necessary additional bending was performed. Case 1: Total pre-operative bending time for the relative simple anatomic shape and mal-union was 53 minutes. Total operative time was 1 hour 19 minutes. Case 2: Total pre-operative bending time for a complicated non-union and anatomy was 1 hour 21 minutes. Total operative time was 1 hour 43 minutes. Because of pre-operative bending, total operative time could be reduced by approximately 40-45%. Additional bending was rarely necessary. This case series demonstrates that the use of 3-dimensional planned patient-specific guides and preoperative preparations can help reduce operating time with satisfactory preliminary results.

## Introduction

A secondary sternal fixation or reconstruction of a medial sternotomy can be indicated after median sternotomy infection or bony non-union. Although rare, they go accompanied with significant morbidity(1). In our centre we routinely use Synthes® Titanium Sternal Fixation System for a secondary sternal reconstruction after bony non-union or after healing of median sternotomy infection. The procedure offers good results (1), but can be, especially in the case of a complex non-union, or a complex anatomy, time-consuming. To perform a good reconstruction the titanium plates need to be bent to the anatomical shape of the sternum and adjacent ribs, to ensure stable refixation, this part of the perioperative procedure is very time-consuming. Working with Materialise (Leuven, Belgium), we developed a technique using 3-dimensional planning and patient specific surgical 3D-printed guide to simplify and quicken the procedure.

Using preoperative 3-dimensional planning and patient-specific surgical guides to aid in surgical procedures isn't something new, it has been in use since a few years, mostly used in orthopedic procedures (2,3).

We describe how we perform a secondary sternal refixation after non-union of a medial sternotomy using a preprinted 3D model of the patient's sternum to achieve reduction in operating time. We were able to reduce operating time by almost fifty percent. We could bend the titanium fixation plates in almost perfect anatomical shape before the procedure itself took place.

We describe two patients where we were able to use this technique.

Three-dimensional planning based on computed tomography images of the mal-united and non-united sternum enabled us to produce a patient-specific 3D printed sternum, and enabled us to custom pre-bend the titanium plates. This article will describe how we do it.

## METHODS:

Two patients were included with indication for sternal refixation or reconstruction following sternal dehiscence after cardiac surgery.

All patients undergo a high-density computed tomography (CT) of the chest to achieve optimal image quality.

Then, pre-operatively, the procedure was simulated through software (Materialise, Belgium), including emulated reduction of both sternal halves into anatomical position. The resulting 3-dimensional image was then used to print the patient specific anatomical model.

On this real-life representable sternal model the titanium sternal plates were bent, in anatomical position, removing the necessity for bending them perioperatively.

The actual perioperative procedure remained unchanged. Reuse of the old incision, removing of the old stainless steel wires, if in situ, debridement of the sternal edges, obtainment of hemostasis. Mobilizing of the pectoralis major muscles to expose the ribs, and reduction of the sternal halves.

After reduction the plates are fitted in place and fixated on the sternum, rarely additional bending is necessary, and if needed, the additional bend is minimal.

## RESULTS:

Case 1: Total bending time for a relative simple anatomic shape and mal-union was 53 minutes (figure 1, figure 2). Total operative time was 1 hour 19 minutes.

Case 2: Total bending time for a complex non-union and anatomy was 1 hour 21 minutes (figure 3, figure 4). Total operative time was 1 hour 43 minutes.

One year follow-up yielded good clinical and cosmetic results.

## DISCUSSION:

Both cases have shown a reduction in operative time, in our centre, as in previous experience without the pre-bent titanium plates, more than double the amount of time would have been spent in the described cases.

Attention to the exact same reduction as performed during the emulation of the procedure is critical to achieve good reduction of the sternal halves, without the exact same reduction, there could be more time needed to adjust the titanium plates, eliminating some advantage of using the preprinted model.

A possible reduction in length of stay or reduced use of analgesia when using the preoperative 3-dimensional planning and patient-specific surgical guide is out of scope of this pilot project and is subject to more research.

## CONCLUSIONS:

This pilot study demonstrates that 3-dimensional planned patient-specific guides and preoperative preparations can help reduce operating time with satisfactory preliminary results.

## Declarations:

Ethics approval and consent to participate: Consent acquired, Ethical committee not applicable.

Consent for publication: Consented

Availability of data and material: Available

Competing interests: none to declare

Funding: Research Grant Sint Antonius Hospital Nieuwegein

Authors' contributions:

Haenen F., M.D.: author, design

Vos R.J., M.D.: co-author, pre-operative support

Daeter E.J., M.D.: supervisor, surgeon, design

Acknowledgements: Materialise, Leuven, Belgium

Reference:

1. Sternal plate fixation for sternal wound reconstruction: initial experience (retrospective study). *Fawzy H<sup>1</sup>, Osei-Tutu K, Errett L, Latter D, Bonneau D, Musgrave M, Mahoney J. J Cardiothorac Surg.* 2011 Apr 29;6:63. doi: 10.1186/1749-8090-6-63.
2. *Corrective Osteotomy for Malunited Diaphyseal Forearm Fractures Using Preoperative 3-Dimensional Planning and Patient-Specific Surgical Guides and Implants.* Byrne AM, Impelmans B, Bertrand V, Van Haver A, Verstreken F. *J Hand Surg Am.* 2017 Jul 11. pii: S0363-5023(17)30928-0. doi: 10.1016/j.jhsa.2017.06.003. [Epub ahead of print] PMID:28709790
3. Corrective osteotomy of distal radius malunions using three-dimensional computer simulation and patient-specific guides to achieve anatomic reduction. *Michielsen M, Van Haver A, Bertrand V, Vanhees M, Verstreken F. Eur J Orthop Surg Traumatol.* 2018 Jun 20. doi: 10.1007/s00590-018-2265-0. [Epub ahead of print]

Figures

Figure legend:

Figure 1: a: frontal view of a non-complex sternal mal-union, with pre-bent titanium fixation plates. b: sideview of the patient specific 3D model with appreciation of the anatomical shaping of the Synthes® titanium fixation plates.

Figure 2: a: pre-operative 3-dimensional model of a complex sternal anatomy with non-union. b: peroperative result after relatively easy implantation of the fixation plates.



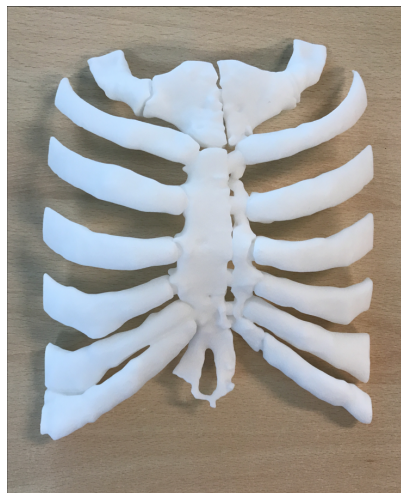


Figure 2a

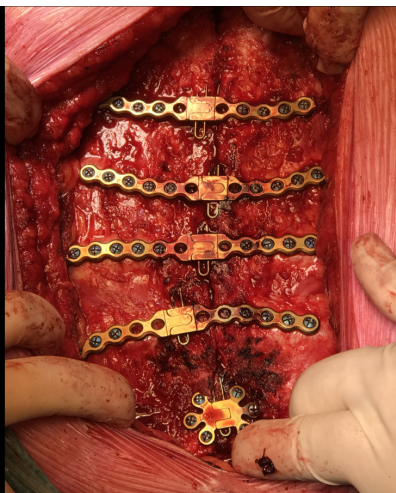

Figure 2b