

A Stuck Colonoscope in the Chest Cavity: An Uncommon Complication

Muhammad Usman Shah¹, Ahmed Eissa², Vincenzo Caruso³, and Sudhir Bhusari¹

¹Basildon and Thurrock University Hospitals NHS Foundation Trust

²Southampton University Hospitals NHS Trust

³Guy's and Saint Thomas' Hospitals NHS Trust

May 26, 2020

Abstract

Colonoscopy is generally considered a safe procedure, with a low rate of complications. Although rare, the migration of the colonoscope may represent a life-threatening event, requiring emergency treatment. We herein describe the case of an elective colonoscopy complicated by an irretrievable colonoscope that migrated, through a previous traumatic diaphragmatic hernia, in the chest cavity. This hernia was likely a chronic complication of a previous abdominal trauma. Several attempts to retrieve the scope were unsuccessful. After further investigations and collegial discussion, a left thoracotomy was performed, with the aim to retrieve the colonoscope and to reduce the hernia.

INTRODUCTION

Although the colonoscopy is a routine and safe procedure, performed widely for diagnostic and therapeutic purposes, rare complications are possible, and they vary from minor abdominal symptoms to more serious complications¹.

The event of an irretrievable or stuck colonoscope is a very rare complication of colonoscopy, that requires an urgent treatment^{2,3}, often related to anatomic variations on the abdominal viscera.

A previous abdominal surgery may increase the risk of this complication: in this scenario, the traumatic diaphragmatic hernia (TDH) is, as well, a rare complication of abdominal trauma which can remain occult and stay undiagnosed for a long time⁵. The case of a stuck colonoscope in a THD is rare and should highlight the importance of undiagnosed abdominal pre-existent conditions.

CASE REPORT

A 76-year-old patient presented with bloating and abdominal pain, with no history of weight loss. He was booked for an elective Colonoscopy.

He had a history of blunt abdominal trauma in a road traffic accident many years back; this was complicated by splenic, bladder and urethral's rupture, closed pelvic fracture and multiple rib fractures. At that time, the patient underwent explorative laparotomy with splenectomy; he further required surgeries for bladder and urethral reconstruction.

The colonoscopy was initially performed with no complications, up to the terminal ileum; biopsies were taken for diagnostic purpose.

Upon withdrawal of the scope, a suddenly hard resistance was encountered by the operator. Despite multiple attempts, including inserting a pediatric scope along the colonoscope to dislodge it, the scope was irretrievable.

An emergency fluoroscopy revealed that the scope was inside the chest cavity (Figure 1.A); a computed tomography scan showed a chronic left sided TDH; the colonoscope was observed inside a bowel loop, which was incarcerated in the TDH (Figure 1.B). This was, most likely, a chronic result from the blunt abdominal trauma decades earlier.

After a collegial discussion, between general and cardiothoracic surgeons and the gastroenterologist team, the decision was made for a left thoracotomy to reduce the TDH and to retrieve the scope. The surgical approach was chosen in view of two factors: first, as the scope was being stuck in the thoracic cavity, it carried the potential risk of perforating the colon soiling the chest; second, due to the presence of abdominal adhesions, exploring the abdomen would have carried a significant increased risk. The thoracotomy approach was considered a safer approach in this case.

A left posterolateral thoracotomy was performed at the level of the fifth intercostal space; this allowed easy entry to the chest cavity. The hernia's sac was identified abutting on the lower lobe of the left lung (Figure 2); after blunt dissection, the adhesions between the lung and the sac were dissolved. The scope was palpable inside the sac; this was opened, showing herniated colon (Figure 3.A). No flogosis was observed at the level of the sac's neck, with no strangulation.

It was decided to perform a manual reduction of the sac (Figure 3.B); this was temporary, and it allowed an easy retraction of the scope per rectally with no resistance.

A thorough and careful examination of the colon revealed no evidence of perforation or injury.

Despite the initial reduction of the sac, later it was noted a very limited space for the hernial contents to be reduced into the abdominal cavity, likely due to the marked adhesions from previous abdominal surgeries. After an intraoperative collegial discussion, it was felt that any further attempts at reducing the hernia in the abdomen and repairing the diaphragmatic defect, would may result in a colonic ischemia.

A conservative strategy was then performed. The diaphragmatic hernial orifice was enlarged to prevent any future strangulation: this was performed with a partial resection, extended for not more than 0.5 cm circumferentially. The colon was then reduced to the abdominal cavity as much as possible.

The procedure was then completed with no further complications.

The patient was closely monitored for signs of intestinal obstruction; he was then discharged home, on third post-operative day, after an uneventful recovery.

DISCUSSION

An irretrievable colonoscope secondary to looping is an exceedingly rare complication of colonoscopy; the presence of previous abdominal surgery is a risk factor for procedural difficulty and incompleteness¹⁻³. Significant looping and angulations are reported to cause the colonoscope to be difficult to advance or retrieve, requiring a laparotomy to withdraw it²⁻⁴.

In this case report, the rare complication of colonoscope's migration in the chest cavity was associated to the presence of a late TDH. The TDH is more commonly associated with blunt abdominal injury like road traffic accident and fall from height when compared with penetrating abdominal injuries and has higher tendency to increase in size and include abdominal organs as the increasing abdominal pressure causes the abdominal content to herniate into the pleural cavity which has relatively lower pressure⁵.

It is not uncommon for the TDH to remain asymptomatic and have a delayed presentation with potentially serious consequences, as demonstrated by this case.

The literature shows few cases reported of colonoscopes stuck in incarcerated hernias which required surgical management and none of the reported cases were diaphragmatic hernias²⁻⁴.

In these cases, a meticulous planning is essential, and it involves a collegial team discussion with different specialist. The surgical strategy should focus on the retrieval of the colonoscope with simultaneous reduction

of the TDH; this may represent a challenging situation in view of the previous abdominal adhesions.

In this case report, despite the colonoscope was easily withdraw per rectum, after temporary reduction of the hernial sac, the TDH could not fully be reduced in the abdomen., for the hard adhesion on the abdominal versant. A limited enlargement of the hernial orifice was performed respecting the hernial contents in a view to avoid any future strangulation; this enlargement was also limited to prevent future progression of the herniation process.

ACKNOWLEDGEMENTS

No acknowledgements

AUTHOR CONTRIBUTION:

Dr Shah, Dr Eissa, Dr Caruso and Dr Bhusari: They equally have made substantial contributions to conception and design and acquisition of data; they have been involved in revising the manuscript critically for important intellectual content and they have given final approval of the version to be published.

They agreed to be accountable for all aspects of the work in ensuring that questions related to the accuracy or integrity of any part of the work are appropriately investigated and resolved.

REFERENCE

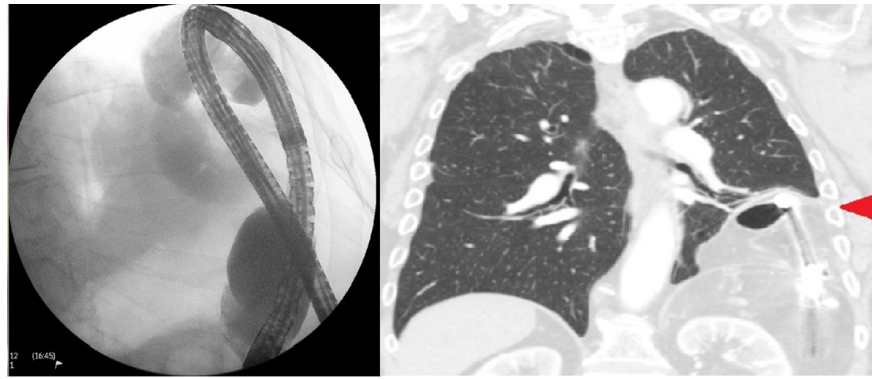
1. Ko CW, Dominitz JA. Complications of colonoscopy: magnitude and management. *Gastrointest Endosc Clin N Am.* 2010 Oct;20(4):659-71.
2. Hammerschlag J, Ackerman T, Hodgkins B. The unusual case of the irretrievable colonoscope. *Clin Case Rep.* 2017 Oct 23;5(12):1970-71.
3. Lee SK, Kim TI, Shin SJ, Kim BC, Kim WH. Impact of prior abdominal or pelvic surgery on colonoscopy outcomes. *J Clin Gastroenterol.* 2006 Sep;40(8):711-16.
4. Tan VP, Lee YT, Poon JT. Incarceration of a colonoscope in an inguinal hernia: Case report and literature review. *World J Gastrointest Endosc.* 2013 Jun 16;5(6):304-7.
5. Lu J, Wang B, Che X, Li X, Qiu G, He S, Fan L. Delayed traumatic diaphragmatic hernia: A case-series report and literature review. *Medicine (Baltimore).* 2016 Aug;95(32):e4362.

FIGURES LEGEND:

Figure 1: A: Fluoroscopy revealing the scope inside the chest cavity; B: Computed tomography scan shows a left sided diaphragmatic hernia; the colonoscope is observed inside a bowel loop (red arrow).

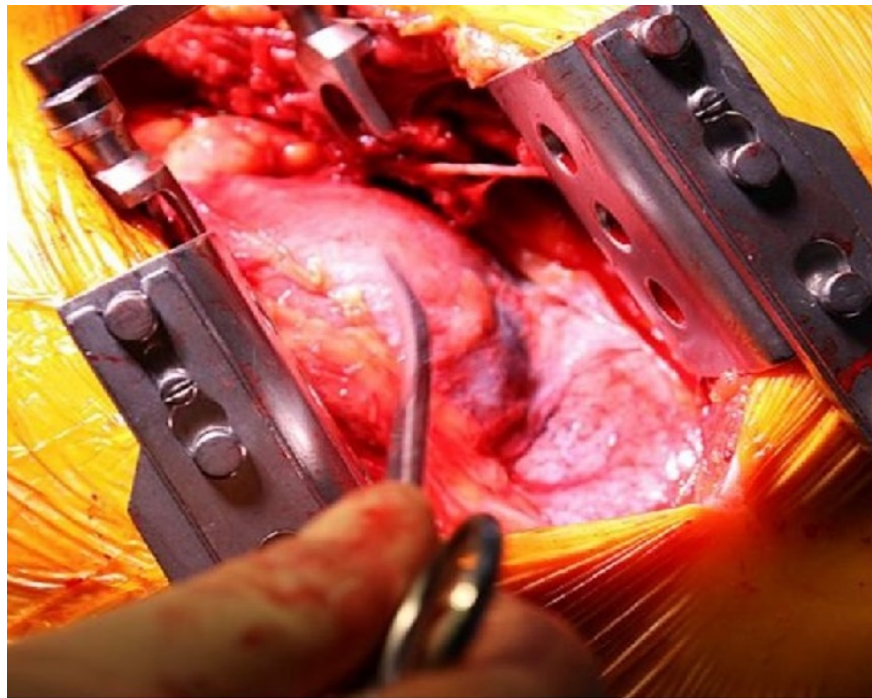
Figure 2: Herniated sac (as indicated by scissor) identified after left thoracotomy.

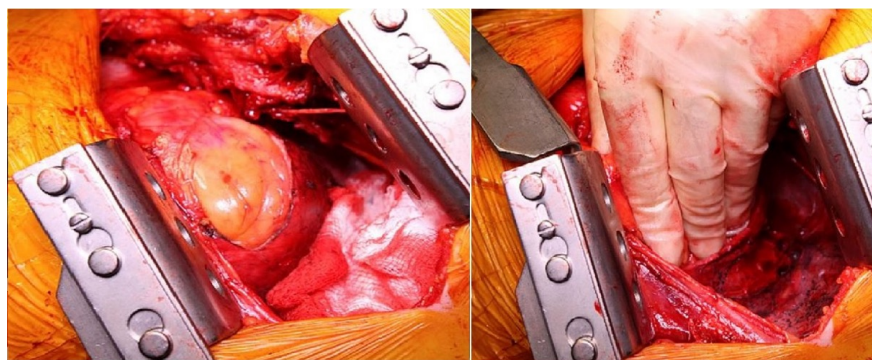
Figure 3: A. The sac is opened, showing intact herniated colon; B. Manual reduction of the hernia, allowing retrieval of the colonoscope (not showed).



A

B





A

B