

# Scapular Free Flap Reconstruction of Pharyngoesophageal Defects

Shaum Sridharan<sup>1</sup>, Vaibhav Ramprasad<sup>1</sup>, Robert Keller<sup>2</sup>, Terry Day<sup>2</sup>, Eric J. Lentsch<sup>3</sup>, and Judith Skoner<sup>2</sup>

<sup>1</sup>University of Pittsburgh Medical Center

<sup>2</sup>Medical University of South Carolina

<sup>3</sup>Med Univ S Carolina

June 4, 2020

## Abstract

**Objective:** Scapular and parascapular free tissue transfer (SFTT) is a well described reconstructive option for the head and neck. Majority of reported outcomes are of reconstruction of oromandibular and midface defects. The aim was to describe one institution's experience with SFTT for reconstruction of PE defects. **Design:** Retrospective review of patients undergoing SFTT for head and neck defects between 2009 and 2014 at a tertiary medical center. The cohort included patients undergoing reconstruction of PE defects with at least 6 months follow up. **Setting:** Tertiary medical center **Participants:** Patients undergoing SFTT for PE defects. Seventeen patients (13 male and 4 female) met inclusion criteria. **Main outcomes and Measures:** Surgical outcomes, speech, voice outcomes, swallowing outcomes, enteral feeding and tracheoesophageal puncture usage. **Results:** Seventeen patients met criteria – 4 female, average age at time of surgery 64.5 (SD 9.1). Thirteen patients were Caucasian and remaining four African American. Two of 17 patients developed pharyngocutaneous fistulas (PCF) as inpatients. There was one major medical complication (pulmonary embolism) and 7 minor complications. Mean hospital length of stay was 15.7 days (SD 8.2). In post-operative setting, only one patient remained PEG-dependent, 11 patients supplemented oral intake with PEG feeds and 5 patients took nutrition solely by mouth. Four patients utilized written communication exclusively, 6 patients pursued TEP placement and 7 utilized electrolarynx. **Conclusion:** The SFTT is a viable option for hypopharyngeal reconstruction. All SFTT remained viable for the duration of our review. Post-operative PCF rate were comparable to that reported after laryngectomy.

## INTRODUCTION

Scapular/Parascapular free tissue transfer (SFTT) has become a powerful and versatile tool in the armamentarium of the head and neck reconstructive surgeon. Free flaps based off the subscapular system allow the surgeon to harvest a combination of soft tissue, bone, and muscle with limited donor site morbidity. Blood supply to the skin paddle is composed of numerous skin perforators from the vascular pedicle allowing safe manipulation and contouring of the skin paddle during flap inset. Fascio-cutaneous skin paddles can be created as large as 25 cm in length safely with high likelihood for primary donor site closure.

The majority of published papers using SFTT report outcomes of patients who underwent reconstruction of massive oromandibular and midface defects.<sup>1,2</sup> Limited data has been published on pharyngoesophageal (PE) reconstruction using SFTT with many studies focusing on radial forearm or anterolateral thigh free flap reconstruction.<sup>3,4</sup> Though gaining popularity, SFTT for head and neck defects is discarded by some due to claims of increased operative time and the need to reposition the patient.

Complications from failed PE reconstruction can often be life threatening and delay adjuvant cancer treatment initiation. Patients who develop pharyngocutaneous fistula experience increased duration of hospital stay, are prone to infectious complications, and risk carotid blowout. Moreover, many who develop fistula, even after healing, have resultant stricture and are gastrostomy tube (Gtube) dependent.<sup>5</sup>

Scapula/Parascapular free flaps have the potential to avoid some of these complications due to the abundant soft tissue and skin capable of reconstructing circumferential PE defect. In addition to addressing PE defects, fasciocutaneous (FC) flaps can be designed to fill cervical skin defects and protect the great vessels. This is especially important in patients who have failed non-surgical treatment measures and suffer from post-radiation changes to skin elasticity and vascularity

The objective of this study is to describe our institution's experience with SFTT for the reconstruction of PE deficits. This review will focus on surgical outcomes of PE defect closure, donor site morbidity, and post-op speech and swallowing function.

## METHODS

### Patients:

A retrospective review was conducted of all patients undergoing SFTT for head and neck defects between 2009 and 2014. The cohort was then narrowed to only those patients who had reconstruction of PE defects. All reconstructive procedures were performed by the senior author (JMS). Patients were only included if they had documented follow up for at least 6 months post-operatively. Moreover, patients were excluded if they lacked pre-operative and post-operative speech and language pathology evaluation with documentation of functional outcomes.

### Data Collection and statistical analysis:

The following data elements were collected for each patient in the cohort: basic demographics, social history, defect classification (partial vs. circumferential), previous treatment, ablative procedure, donor site morbidity, salivary bypass tube use, and functional outcomes. In addition, basic lab work results and nutritional status was also recorded for each patient. Also, skin paddle dimensions, recipient blood vessels, and venous coupler sizing was collected. Surgical outcomes and complications were documented for each patient both from the flap donor site and reconstructive site.

Lastly, speech and language pathology data were reviewed including voice outcomes, swallowing outcomes, enteral feeding usage, and tracheoesophageal puncture usage. Descriptive statistics were utilized after review of pertinent charts.

## RESULTS

After review of a database of over 200 scapula free tissue transfer reconstructions conducted by the senior author (JMS) at our institution, 17 patients (13 male, 4 female) met criteria to be included in the study (Table 1). All patients were left with total laryngopharyngectomy defects after oncologic ablation necessitating free tissue transfer reconstruction. Average age of the cohort at the time of surgery was 64.5 (SD 9.1, range 46.4-76.3). There were 13 Caucasian patients and the remaining four were African American. Of all patients, 88.2% were primary chemoradiation (n=9) or radiation-alone (n=6) failures undergoing salvage surgery. Only two patients had not received any prior treatment.

All patients had a preoperative diagnosis of head and neck squamous cell carcinoma—the majority of patients had tumors involving the glottis (n=6) and supraglottis (n=5) with the remaining tumors being of the oropharynx(n=2), nasopharynx (n=2), hypopharynx (n=1), or oral cavity (n=1). Mean follow-up after surgery was 19.1 months with all patients followed for at least 6 months.

Operative notes dictated by the primary operative surgeon (JMS) of all reconstructions were reviewed. All patients underwent microvascular reconstruction with a fasciocutaneous scapular free tissue transfer in a circumferential/tubed (n=11) or non-circumferential, partially-tubed (n=6) fashion. All patients were positioned in lateral decubitus position for flap harvest (Figure 1), and donor sites were closed primarily in all cases (Figure 2). Flap pedicles were based off the subscapular or circumflex scapular artery and veins in all cases. Recipient arteries varied based off availability of healthiest vessels in the neck, specific defect location, and pedicle length, but the most commonly used were the facial (n=5), superior thyroid (n=4) and transverse cervical (n=6) arteries. In regard to veins, the external jugular vein (n=7) or branches off the internal jugular

vein (n=9) were used in all cases. An implantable doppler was coupled to the recipient vein in all-cases for continuous monitoring capability in the postoperative period. Mean skin paddle size was 152.2cm<sup>2</sup> (SD 56.2cm<sup>2</sup>, range 67.5-242cm<sup>2</sup>) and average ischemia time was approximately 4 hours (range 2:57-4:50). It should be noted, that the senior author prefers to complete a majority of the hypopharyngeal reconstruction before starting on construction of the microvascular anastomosis. This results in long ischemia times, which would be modified by starting the microvascular component of the case immediately after repositioning the patient. Salivary bypass tubes were placed in the vast majority of cases at the time of surgery (n=14). There were no significant documented intra-operative complications.

Post-operatively, all patients were admitted to the surgical-trauma ICU for every-1-hour nursing flap checks. Within the patient cohort, there were no partial or total flap losses, resulting in a flap survival rate of 100%. Donor site morbidity was also excellent, with only two post-operative back hematoma requiring bedside drainage and placement of a wound vac. There were no donor site wound infections or dehiscences. Further surgical complications post-operatively included two hematomas (one neck, one chest) and two cases of wound dehiscence (one at flap edge, one at stoma).

Two patients developed pharyngocutaneous fistulas as inpatients (11.7%). One fistula was closed with pectoralis flap successfully, and the other closed after aggressive packing and the use of a wound vacuum device. There was one major medical complication (pulmonary embolism) and 7 minor complications including pneumonia, minor respiratory events, arrhythmias, acute blood loss anemia, delirium, and electrolyte disturbances (Table 2). Mean hospital length of stay was 15.7 days (SD 8.2, range 8-36 days). Adjuvant therapy (chemoradiation, chemotherapy- or radiation-alone) was carried out in 10 of the 17 patients post-operatively.

Speech outcomes in the outpatient setting were reviewed (Table 3). Pre-operatively, nutritional status was generally poor with only 7 patients able to fulfill all nutritional needs via oral intake. The remaining patients were either supplementing with PEG feeds (n=8) or PEG-dependent (n=2). In the postoperative setting, only one patient remained PEG-dependent, 11 patients continued to supplement their oral intake with PEG feeds, and 5 patients were taking solely by mouth at last documented follow-up. Four patients required esophageal dilation in the operating room as part of their swallowing rehabilitation. In many cases, swallowing outcomes were affected by pre-operative swallowing dysfunction including trismus and multi-level swallowing difficulty. Moreover, swallowing outcomes often worsened after adjuvant treatment with chemotherapy, radiation therapy, or both.

Voice outcomes varied significantly among patients in the cohort (Table 3). Four patients remained with only text/written speech for communication, 6 patients pursued TEP placement and were progressing with voice rehabilitation, and 7 patients were utilizing an electrolarynx with varying degrees of success.

## DISCUSSION

Since Dos Santos published on the anatomy of the subscapular system and introduced the scapula free flap<sup>6</sup>, much has been written on the versatility and applicability of the scapula/parascapular free flap in head and neck reconstruction. Large series have been published regarding single-institution experiences with the scapula flap. Few series focus on the fasciocutaneous iteration of the SFTT. Yoo et. al. detailed their experience with SFTT in 60 patients with only 29 of these requiring fasciocutaneous free flaps<sup>7</sup>. Of those, only one patient required hypopharyngeal reconstruction. In this review, further details of functional outcomes in this patient were not described. Another large series of 130 patients was also recently published but had only four patients requiring fasciocutaneous flaps<sup>8</sup>. Again, there was only one person with hypopharyngeal reconstruction. The fasciocutaneous SFTT was most often used in other small series for reconstruction of skin and scalp defects.

In the era of chemoradiation, the utilization of non-radiated, vascularized tissue for closure of post-laryngectomy defects has become the standard of care. Our study demonstrates that the scapular/parascapular free flap is a safe and reliable option for hypopharyngeal reconstruction. Eighty-eight percent of our patients had failed non-surgical treatment with the majority of these patients having had

chemoradiation therapy (n=9). As with most patient cohorts requiring laryngectomies, nearly all patients had a significant smoking history and significant comorbidities. Of the 17 patients included, 11 patients required a complete hypopharyngeal reconstruction and the remaining 6 needed partial PE closure. Lastly, it should be noted that two patients required cervical skin reconstruction as well which was accomplished with the creation of a second flap skin paddle. Often, this determination cannot be made until the time of reconstruction making the SFTT an ideal reconstruction option due to its versatility and durability.

All scapula free tissue transfers remained viable for the duration of this review. This flap survival rate is comparable to the large retrospective series of radial forearm and anterolateral thigh free flap reconstruction post-laryngectomy<sup>9,10</sup>. Pharyngocutaneous fistulas developed in two patients in the immediate post-operative setting. These fistulas were initially managed conservatively with washout and wound packing. Closure was achieved after wound vac placement in one patient, while the other patient required a pectoralis major flap. It should be noted that the patient who required the pectoralis flap had undergone an esophagectomy for cervical esophageal cancer recurrence after previous total laryngectomy and radiation therapy. Published pharyngocutaneous fistula (PCF) rates after laryngectomy vary widely amongst authors. Recently, Yu et. al. reported a 8.8% PCF rate for PE defect reconstruction<sup>11</sup>. The majority of patients underwent free tissue reconstruction (92%) with higher rates of fistula in patients with circumferential vs. partial defects (11% vs. 6%). These figures are comparable to our PCF rate of 11.7%.

Few patients had major or minor events during the inpatient hospital stay. Despite pharmacologic venous thromboembolism prophylaxis, one patient developed bilateral deep venous thrombosis and subsequent pulmonary embolism. The patient was treated with therapeutic anticoagulation without further complications. Seven patients had minor hospital complications ranging from cardiac arrhythmias to pneumonia (Table 2). All minor complications responded to conventional treatments and did not require invasive measures. There were no immediate post-operative deaths in our patient cohort. These complications do not vary greatly from other published papers dealing with PE defect reconstruction or SFTT<sup>11,12</sup>.

Swallowing and speech outcomes were followed closely pre- and post-operatively in our cohort of patients. Speech and language pathologist (SLP) evaluations were performed independently, and these results were used as outcome measures. A majority of these evaluations were conducted via functional endoscopic evaluation of swallowing (FEES) exam. Modified barium swallow exams were conducted serially if needed. Oral intake was reestablished in 94.1% of patients with five of these patients not requiring gastrostomy tube (G tube) feeding for supplementation. Though supplementation via G tube is not ideal, several patients required supplemental nutrition due to multilevel swallowing dysfunction, debilitation due to adjuvant treatment, and cancer recurrence. Two patients who required supplemental G tube feeding suffered from debilitating trismus while having a patent neopharynx. Only one patient could not re-establish any oral intake requiring total enteral nutrition. This patient required surgery after previous laryngectomy with stomal recurrence extending into the esophagus. Six patients were able to undergo tracheoesophageal puncture, and all of these patients had excellent voice outcomes as determined by SLP evaluation. The remaining patients are currently using electrolarynx or text/written communication at the moment. A small cohort of these patients are awaiting possible TEP placement in the future.

Donor site morbidity was minimal in our patient population. All back wounds were closed primarily after wide undermining at the time of flap harvest. In addition to placing large Jackson-Pratt drains in the surgical bed, incisional negative pressure wound therapy was employed as previously described.<sup>13</sup> Two patients developed back hematomas. Both were treated successfully at the bedside with partial opening of the incision and twice daily packing. Both wounds eventually healed by secondary intention. Similarly, two other patients had minor wound dehiscence along a small portion of the back closure that eventually closed secondarily. All patients participated in inpatient physical therapy after surgery with no limits on weight bearing. Lastly, no patient experienced range of motion limitations post-operatively. Other authors' experiences with SFTT donor site morbidity have also been quite favorable<sup>12,14</sup>. Most papers cite minor wound complications and no significant muscle weakness or range-of-motion limitations even when performing osteocutaneous SFTT.

We acknowledge the pros and cons of SFTT use for hypopharyngeal closure. The ALT flap has become to gold standard in many regards for its ability to harvest large fasciocutaneous flaps capable of having multiple skin islands. Also, concurrent harvest of the ALT flap during ablative surgery much easier when compared to SFTT. Despite these advantages, they SFTT has some benefit over the ALT flap. Scapular flaps are capable of creating much large skin paddles when compared to ALT flaps without the concern for closing under extreme tension or causing a compartment syndrome. The SFTT also has much more reliable anatomy with a pristine vascular pedicle not affected by atherosclerotic changes. Moreover, since the blood supply to the skin paddle is not based on perforator dissection, the SFTT is a very robust flap often capable of being manipulated with impunity. Lastly, several institutions position the patient in partial lateral decubitus to harvest the flap concurrently with head and neck surgery. Pedicle length is usually increased in ALT flap, but since the SFTT can be oriented in various ways, this advantage is limited in the neck.

Though our outcomes using SFTT are encouraging there are some limitations to this study. Drawbacks include the retrospective nature of this review and the small sample size. Also, our study lacks a control group and our outcomes are only measured against published studies using other reconstructive options. Further studies will aim to prospectively compare outcomes between SFTT and other commonly used free flaps in PE defect reconstruction.

This study presents SFTT as a viable option for reconstruction of PE defects. Much like other microvascular free tissue transfer options, it provides adequate soft tissue coverage with a reliable, large caliber vascular pedicle. Moreover, even in circumstances where large skin paddles are required such as reconstruction of cervical skin defects, the SFTT provides abundant soft tissue with minimal donor site morbidity. Lastly, functional outcomes regarding speech and swallowing with SFTT for post-laryngectomy defects are comparable to other reconstructive options. Though this flap may not be the first option for reconstructive surgeons, it should be part of the armamentarium in complicated hypopharyngeal reconstruction.

## REFERENCES

1. Dowthwaite SA, Theurer J, Belzile M, et al. Comparison of fibular and scapular osseous free flaps for oromandibular reconstruction: a patient-centered approach to flap selection. *JAMA Otolaryngol Head Neck Surg.* 2013;139(3):285-92.
2. Valentini V, Gennaro P, Torroni A, et al. Scapula free flap for complex maxillofacial reconstruction. *J Craniofac Surg.* 2009;20(4):1125-31.
3. Morrissey AT, O'connell DA, Garg S, Seikaly H, Harris JR. Radial forearm versus anterolateral thigh free flaps for laryngopharyngectomy defects: prospective, randomized trial. *J Otolaryngol Head Neck Surg.* 2010;39(4):448-53.
4. Welkoborsky HJ, Deichmüller C, Bauer L, Hinni ML. Reconstruction of large pharyngeal defects with microvascular free flaps and myocutaneous pedicled flaps. *Curr Opin Otolaryngol Head Neck Surg.* 2013;21(4):318-27.
5. Hanasono MM, Lin D, Wax MK, Rosenthal EL. Closure of laryngectomy defects in the age of chemoradiation therapy. *Head Neck.* 2012;34(4):580-8.
6. Dos santos LF. The vascular anatomy and dissection of the free scapular flap. *Plast Reconstr Surg.* 1984;73(4):599-604.
7. Moukarbel RV, White JB, Fung K, Franklin JH, Yoo JH. The scapular free flap: when versatility is needed in head and neck reconstruction. *J Otolaryngol Head Neck Surg.* 2010;39(5):572-8.
8. Mitsimponas KT, Iliopoulos C, Stockmann P, et al. The free scapular/parascapular flap as a reliable method of reconstruction in the head and neck region: a retrospective analysis of 130 reconstructions performed over a period of 5 years in a single department. *J Craniomaxillofac Surg.* 2014;42(5):536-43.

9. Yu P, Hanasono MM, Skoracki RJ, et al. Pharyngoesophageal reconstruction with the anterolateral thigh flap after total laryngopharyngectomy. *Cancer*. 2010;116(7):1718-24.
10. Scharpf J, Esclamado RM. Reconstruction with radial forearm flaps after ablative surgery for hypopharyngeal cancer. *Head Neck*. 2003;25(4):261-6.
11. Selber JC, Xue A, Liu J, et al. Pharyngoesophageal reconstruction outcomes following 349 cases. *J Reconstr Microsurg*. 2014;30(9):641-54.
12. Gibber MJ, Clain JB, Jacobson AS, et al. Subscapular system of flaps: An 8-year experience with 105 patients. *Head Neck*. 2015;37(8):1200
13. Schmedes GW, Banks CA, Malin BT, Srinivas PB, Skoner JM. Massive flap donor sites and the role of negative pressure wound therapy. *Otolaryngol Head Neck Surg*. 2012;147(6):1049-53.
14. Ferrari S, Ferri A, Bianchi B, Varazzani A, Perlangeli G, Sesenna E. Donor site morbidity after scapular tip free flaps in head-and-neck reconstruction. *Microsurgery*. 2015;35(6):447-50

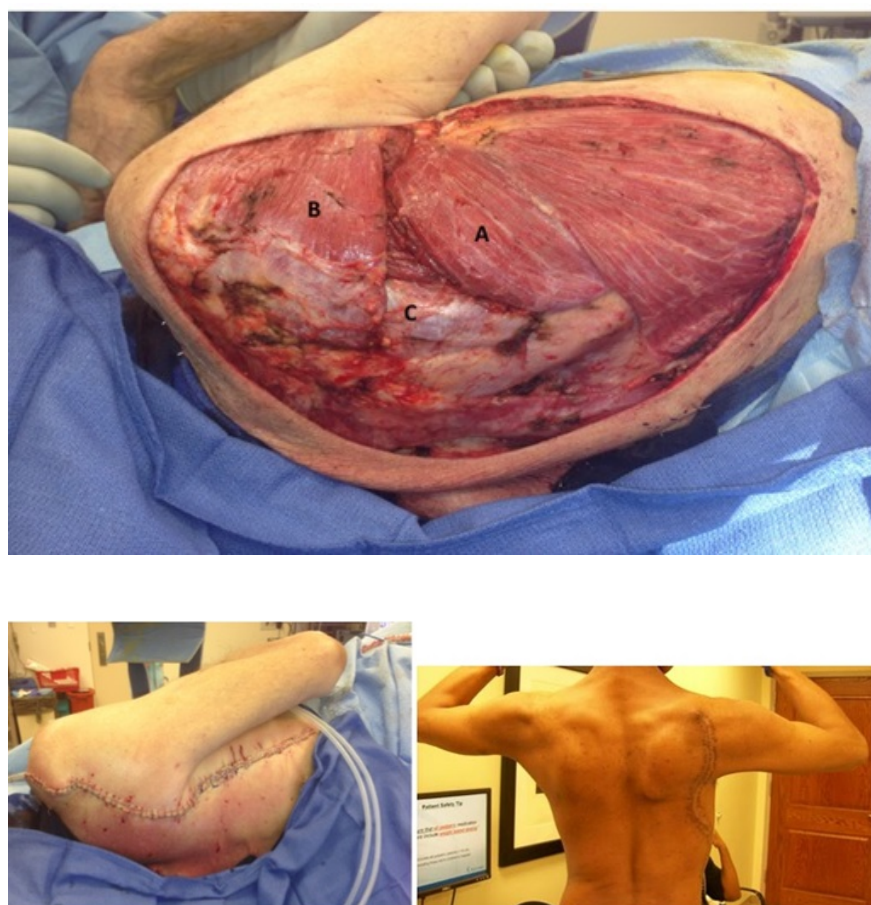
## FIGURE LEGENDS

Figure 1: Scapular flap harvest - Positioning and Post-Dissection Anatomy

Teres Major Muscle B. Triceps Muscle C. Teres Minor Muscle

Figure 2: Donor Site Primary Closure

Left: Intra-operative photo Right: First post-operative visit photo



## Hosted file

Tables.docx available at <https://authorea.com/users/329769/articles/456691-scapular-free-flap-reconstruction-of-pharyngoesophageal-defects>