

# Huffing and Twist: Fatal Torsade de Pointes Associated with Tetrafluoroethane Inhalation.

Joseph Burke<sup>1</sup>, Mark Haigney<sup>2</sup>, Morteza Farasat<sup>1</sup>, Philip Mehler<sup>1</sup>, and Mori Krantz<sup>1</sup>

<sup>1</sup>Denver Health and Hospital Authority

<sup>2</sup>Uniformed Services University of the Health Sciences

July 1, 2020

## Abstract

A patient presented with torsade de pointes after inhaling tetrafluoroethane, a volatile gas propellant used to clean keyboards. She had a prior hospitalization for cardiac arrest without rhythm documentation after inhaling a similar product. Urine toxicology revealed methamphetamine. We are unaware of previous descriptions of torsade de pointes associated with volatile hydrocarbon inhalation or “huffing.” Although sudden death is associated with “huffing,” an arrhythmic mechanism has not been elucidated. Tetrafluoroethane, however, is chemically similar to chlorophorm (trichloromethane), which blocks the delayed rectifier potassium ion current (I<sub>kr</sub>). Thus, we postulate that delayed repolarization with methamphetamine triggering may account for this arrhythmia.

## CASE REPORT

A 38 year-old female with a past medical history of huffing-associated cardiac arrest, was standing at the bus stop when she was witnessed to experience tonic-clonic seizure activity followed by collapse. Emergency Medical Services arrived on the scene shortly thereafter and she was found to be in ventricular fibrillation. Epinephrine 3mg and Amiodarone 450mg were administered as bolus therapy and she was defibrillated three time for persistent ventricular tachycardia. The patient had return of spontaneous circulation, but in the emergency department (ED) developed torsade de pointes (**Figure, Panel A**), which degenerated into ventricular fibrillation requiring defibrillation. According to acquaintance reports, the patient was huffing volatile chemicals just prior to her arrest.

In the ED, her physical examination was unrevealing. Her laboratory analysis was notable for a critically low serum potassium concentration of 2.6 mEq/L (normal range 3.5-4.5), high sensitivity troponin-I of 2,406 ng/L (reference range < 34 ng/L), and elevated serum lactate at 6.3 mmol/L (reference range 0.3-2.0 mmol/L); consistent with acidosis from resuscitated sudden cardiac death and resultant systemic hypoperfusion. The patient was intubated and transferred to the intensive care unit and during transit, torsade de pointes recurred (**Figure, Panel B**), resolving spontaneously. She was admitted with a primary diagnosis of cardiac arrest secondary to tetrafluoroethane inhalation. Electrocardiography (ECG) revealed a rate-corrected QT interval (QTc) of 502 ms. Emergent transthoracic echocardiography revealed normal left ventricular systolic function with an ejection fraction of 60% by Simpson’s biplane method without segmental wall motion abnormalities. Therefore, coronary angiography was deferred despite elevated biomarkers. Urine toxicology was positive for amphetamines (1,000 ng/ml cutoff for detection), but negative for cocaine. Serum toxicology was negative for ethanol (<10 ng/ml). Toxicology for volatile petrochemicals was not available in our laboratory. Unfortunately, the patient had severe anoxic brain injury with marked autonomic dysfunction and supportive care was ultimately withdrawn.

## DISCUSSION

Our patient presented with a fatal ventricular arrhythmia in the setting of volatile hydrocarbon inhalation, potentially compounded by concomitant catecholaminergic stimulation due to methamphetamine use. To our knowledge, this represents the first clinical description of torsade de pointes associated with volatile hydrocarbon inhalation, though sudden death has been associated with this practice. Despite prior reports of sudden death, no definitive rhythm documentation has been published (1-3). Tetrafluoroethane is used as a propellant for wine cork removers and gas dusters, whose intended use is to remove debris and dust particles from computer keyboards. These products are not FDA regulated and are widely available. Volatile inhalant abuse is performed by sniffing (e.g. sniffing glue), bagging, or huffing. Bagging is performed by breathing the vapor directly from a plastic or paper bag to augment the concentration of inhaled fumes. Huffing is perhaps the most potent form of abuse as it is performed by soaking a cloth in the hydrocarbon and holding it over the nose and mouth in order to maximize the intoxicant concentration (4). These inhalants are abused as an inexpensive alternative to typical drugs of abuse. Most inhalants affect the central nervous system and lead to euphoria, often accompanied by slurred or distorted speech, lack of coordination, dizziness, and hallucination.

While the use of volatile inhalants is associated with both cardiotoxicity and sudden death (1), less is known about the cardiovascular properties of these agents. The air conditioning gas, Freon, for example, has been associated with sudden death, but an arrhythmic etiology has not been described (3). However, a few cases of ventricular fibrillation occurring with trichloroethylene (4) and butane (5) suggest that these agents may promote malignant ventricular arrhythmias. Specifically, cardiac sensitization to catecholamines is a recognized result of exposure to halogenated hydrocarbons solvents, including aerosol propellant (6), which was the putative culprit in the present case. Commercially available volatile chemicals are analogous to the general anesthetics. At physiologically relevant concentrations they interact with the primary repolarizing cardiac potassium ion channel, known as the human cardiac ether a' go-go-related gene (hERG), which encodes  $I_{kr}$ , the delayed-rectifier potassium ion current. At higher concentrations, these chemicals may also interact with the slowly activating delayed rectifier potassium channels (IKs), as well as calcium and sodium channels (6).

The compound used in the current case, tetrafluoroethane, has not been extensively studied with regard to electrophysiologic properties. Nevertheless, the molecule is structurally similar to trichloromethane (aka, Chlorophorm) which is an archetypical volatile anesthetic. Chlorophorm is a colorless, sweet-smelling, dense liquid infamously associated with sinister criminal actions whereby a chloroform-soaked rag is applied to the nose and mouth to render victims unconscious. Arrhythmogenesis is presumed secondary to  $I_{kr}$  blockade with an inhibitory concentration required to block 50% (IC50) approximately 5 mmol/L (7). Other anesthetics such as halothane and sevoflurane exhibit only modest  $I_{kr}$  blockade at supratherapeutic concentrations, yet may lead to IKs blockade (8). In the present case, we speculate that volatile hydrocarbon inhalation led to delayed repolarization given prolonged QTc on admission. This coupled with enhanced automaticity and triggered activity (early afterdepolarizations) created the substrate for arrhythmia (6) whereby we speculate that concurrent amphetamine use represented the trigger.

Amphetamines are well known to increase catecholamine concentrations, both centrally and peripherally, by stimulating their release, blocking their reuptake, and inhibiting their metabolism by monoamine oxidase (9). Clinically, this results in tachycardia, vasoconstriction, and hypertension (10). The most common clinical presentations in amphetamine users include chest pain, tachyarrhythmias, palpitations, elevated blood pressure, and myocardial injury, mediated through a confluence of increased myocardial oxygen demand secondary to enhanced chronotropy, wall stress, and afterload, with a simultaneous reduction in coronary blood flow due to intense vasoconstriction. The clinical scenario in the present case, however, was not consistent with a primary ischemic etiology, given normal global and segmental left ventricular systolic function.

In the case of our patient, amphetamines likely served as the catalyst for fatal arrhythmia as they are known to be associated with sudden cardiac death due to malignant ventricular arrhythmias in susceptible individuals (10), but are not definitively known to prolong the QTc-interval in humans. Although one

study found an association between methamphetamine use and QTc-prolongation (11), confounding factors may have contributed. Nonetheless, studies in rats suggest that this effect may be due to the inhibition of transient outward potassium current and the inward rectifying potassium current via its effects on the L-type calcium channel (12). This effect, in conjunction with volatile hydrocarbons that block  $I_{Kr}$ , may be synergistically cardiotoxic.


The present case reveals a fatal malignant ventricular arrhythmia, which occurred in the setting of concomitant methamphetamine and inhalational hydrocarbon intoxication. We concede that a causal connection between huffing and torsade de pointes cannot be definitively made given concomitant methamphetamine use. Moreover, because this patient only recovered brainstem reflexes, serial ECG was not performed, which precludes a diagnosis of congenital long QT syndrome.

Nevertheless, there are no reports of torsade de pointes clearly and directly related to amphetamines, or the medications used to treat attention deficit disorder (13). In support of this, methamphetamine is not considered a potent  $I_{Kr}$ -blocker and was more likely a triggering factor rather than a QTc-prolonging drug (14). Amphetamines, therefore, have a theoretical risk of causing arrhythmias in predisposed patients given their inherent sympathomimetic properties. Nonetheless, using a validated score for drug-associated adverse events, the association between huffing and torsade de pointes is considered probable (15), particularly in light of the temporal association with sudden cardiac death. Importantly, although isolated “huffing” intoxication is rare in the developed world, it may be used to augment the physiologic high associated with more expensive drugs of abuse in certain low-income patient populations.

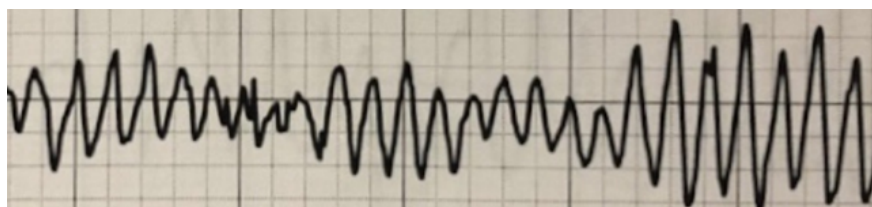
In summary, this case highlights the fatal synergistic effects of increased catecholamines in the setting of prolonged QTc due to blockade of the delayed potassium rectifying channel ( $I_{Kr}$ ). In the appropriate setting, clinicians should consider this compound in the differential diagnosis of patients with idiopathic ventricular fibrillation or torsade de pointes in the setting of intoxication. A prompt search for key historical clues such as paper bags or canisters may be helpful. In addition, an assiduous effort to rapidly correct underlying metabolic abnormalities associated with prolonged QTc has the potential to improve patient outcomes.

### Figure. Torsade de Pointes after Tetrafluoroethane Inhalation

A.



B.



**Figure legend.** Telemetry strip from presentation (A) and upon transfer to the medical intensive care unit.

### REFERENCES

1. Sakai K , Maruyama-Maebashi K , Takatsu A , et al . Sudden death involving inhalation of 1,1-difluoroethane (HFC-152a) with spray cleaner: Three case reports . Forensic Sci. Int 2011 ; 206 : e58 – e61 .

2. Williams DR, Cole SJ. Ventricular fibrillation following butane gas inhalation. *Resuscitation*. 1998;37(1):43-5
3. Brady WJ, Stremski E, et al. Freon inhalational abuse presenting with ventricular fibrillation. *Am J Emerg Med* 1994;12(5): 533-536.
4. Tormoehlen LM, Tekulve KJ, Nañagas KA. Hydrocarbon toxicity: A review, *Clinical Toxicology*, 2014;52:5, 479-489.
5. Waters EM, Gerstner HB, Huff JE. Trichloroethylene. I. An overview. *J Toxicol Environ Health*. 1977;2(3):671-707.
6. Himmel HM. Mechanisms Involved in Cardiac Sensitization by Volatile Anesthetics: General Applicability to Halogenated Hydrocarbons? *Critical Reviews in Toxicology* 2008;38:773–803.
7. Scholz, E.P., Alter, M., Zitron, E., et al. In-vitro modulation of hERG channels by organochlorine solvent trichloromethane as potential explanation for proarrhythmic effects of chloroform. *Toxicol. Lett.* 20026;165:156–166.
8. Shibata, S., Ono, K et al, T. Sevoflurane inhibition of the slowly activating delayed rectifier K<sup>+</sup> current in guinea-pig ventricular cells. *J. Pharmacol. Sci.* 2004;95:363–373.
9. Fleckenstein, A. E., Volz, T. J., Riddle, et al.. New insights into the mechanism of action of amphetamines. *Annual Review of Pharmacology and Toxicology* 2007;47, 681–698.
10. Carvalho, M., Carmo, H., Costa, V. M., Capela, J. P., Pontes, H., Remiao, F, Bastos M. de L. Toxicity of amphetamines: an update. *Archives of Toxicology* 2012; 86(8), 1167–1231.
11. Paratz ED, Cunningham NJ, MacIsaac AI. The Cardiac Complications of Methamphetamines. *Heart, Lung and Circulation* 2016;(25):325–332.
12. Liang, R., Zhou, Y., Wu, F., Zhou, C., Zhao, X., Zhang, M. Effect of methamphetamine on potassium and L-type calcium currents in rat ventricular myocytes. *Toxicology Mechanisms and Methods* 2010;20(8), 458–465.
13. Martinez-Raga J, Knecht C, Szerman N, Martinez MI. Risk of serious cardiovascular problems with medications for attention-deficit hyperactivity disorder. *CNS Drugs*. 2013;27(1):15-30.
14. Credible Meds. QT drugs categorized by their potential to cause QT prolongation and/or torsades de pointes (TdP). Available at: <https://crediblemeds.org/>. Accessed on June 17 2020.
15. Naranjo CA, Busto U, Sellers EM, Sandor P, Ruiz I, Roberts EA, et al. A method for estimating the probability of adverse drug reactions. *Clin Pharmacol Ther.* 1981;30:239-45.