

# Primary Lung sarcoma mimicking left atrial myxoma

Amitabh Satsangi<sup>1</sup>

<sup>1</sup>Department of Orthopaedics AIIMS New Delhi

September 2, 2020

## Abstract

A 32 yr female was referred for surgery for Left atrial myxoma based on symptoms of dyspnea on exertion , palpitations and echocardiography revealing a left atrial mass , mostly likely a left atrial myxoma. On chest X ray , there was right lower lobe white out which instigated the need to perform a CT chest. On CT Chest a 10.9x14.2x13.6 cm (APxTRxCC) cm heterogenously hypodense mass was seen along the posterior and inferior aspect of right hemithorax. It showed multiple vascular channels within it and broad base towards posterior pleura. It had ill defined planes with left atrium and extension into the left atrium through right inferior pulmonary vein. It was causing compression of right descending pulmonary artery and right lower lobe bronchus with collapse of right lower lobe. Likey etiology was sarcomatous/malignant vascular mass. Patient was transferred to oncology department for further management

## Primary lung sarcoma mimicking left atrial myxoma

Amitabh Satsangi<sup>1</sup>

### Author information:-

**1 Amitabh Satsangi M.S(Gen Surgery) Resident , Department of Cardiothoracic and vascular surgery All India Institute of Medical Sciences, New Delhi 10029, India, Email-amoeba418@gmail.com**

**Corresponding author:- Amitabh Satsangi M.S(Gen Surgery) Resident , Department of Cardiothoracic and vascular surgery All India Institute of Medical Sciences, New Delhi 10029, India, Email-amoeba418@gmail.com**

**Abstract- 145 words**

**Key word: left atrial myxoma, Pulmonary sarcoma ,Primary lung tumor entering heart**

**Abstract:** A 32 yr female was referred for surgery for Left atrial myxoma based on symptoms of dyspnea on exertion , palpitations and echocardiography revealing a left atrial mass , mostly likely a left atrial myxoma. On chest X ray , there was right lower lobe white out which instigated the need to perform a CT chest. On CT Chest a 10.9x14.2x13.6 cm (APxTRxCC) cm heterogenously hypodense mass was seen along the posterior and inferior aspect of right hemithorax. It showed multiple vascular channels within it and broad base towards posterior pleura. It had ill defined planes with left atrium and extension into the left atrium through right inferior pulmonary vein. It was causing compression of right descending pulmonary artery and right lower lobe bronchus with collapse of right lower lobe. Likey etiology was sarcomatous/malignant vascular mass. Patient was transferred to oncology department for further management.

## Case summary

A 32 yr female was referred for surgery for Left atrial myxoma based on symptoms of dyspnea on exertion , palpitations and echocardiography revealing a left atrial mass , mostly likely a left atrial myxoma. On chest

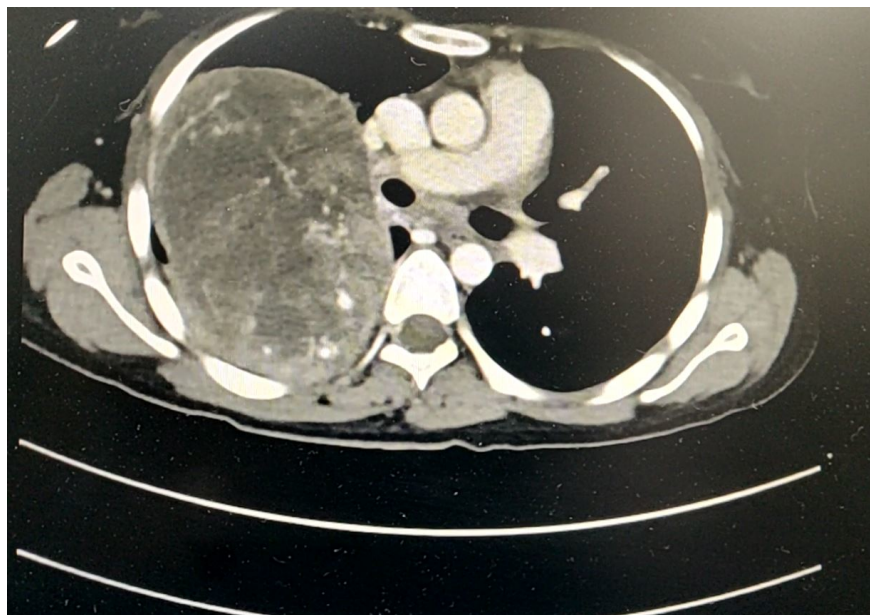
X ray , there was right lower lobe white out which instigated the need to perform a CT chest. On CT Chest a 10.9x14.2x13.6 cm (APxTRxCC) cm heterogenously hypodense mass was seen along the posterior and inferior aspect of right hemithorax. It showed multiple vascular channels within it and broad base towards posterior pleura. It had ill defined planes with left atrium and extension into the left atrium through right inferior pulmonary vein. It was causing compression of right descending pulmonary artery and right lower lobe bronchus with collapse of right lower lobe. Likey etiology was sarcomatous/malignant vascular mass. Patient was transferred to oncology department for further management.

Metastatzation of pulmonary neoplasm to the left atrium has been well documented, particularly in patients with primary lung cancer.(1) (2)

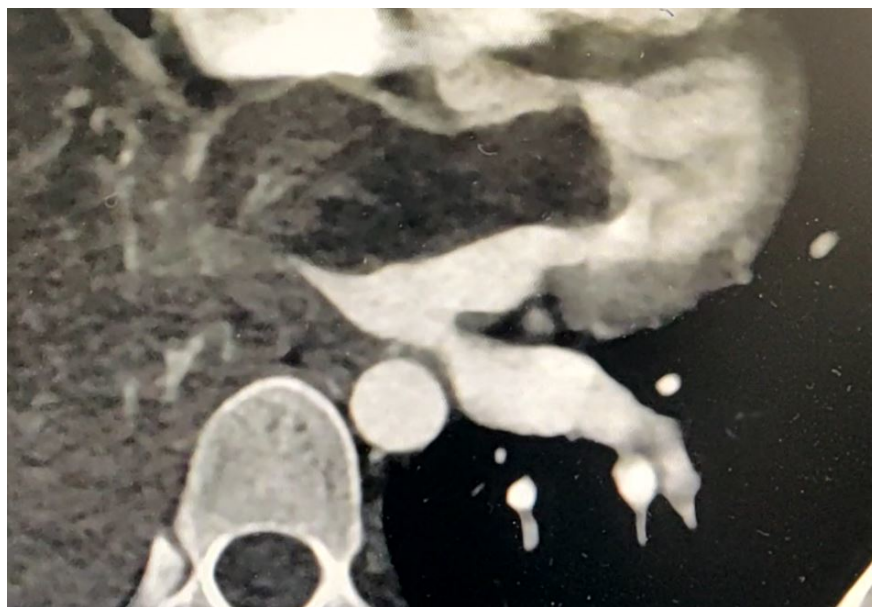LA invasion usually occurs by two main mechanisms, including direct infiltration of myocardial tissue by contiguity and extension into the left atrium via the lymphatics and/or the pulmonary veins .(3)

In our case there is LA invasion via the pulmonary veins of right lung sarcoma.

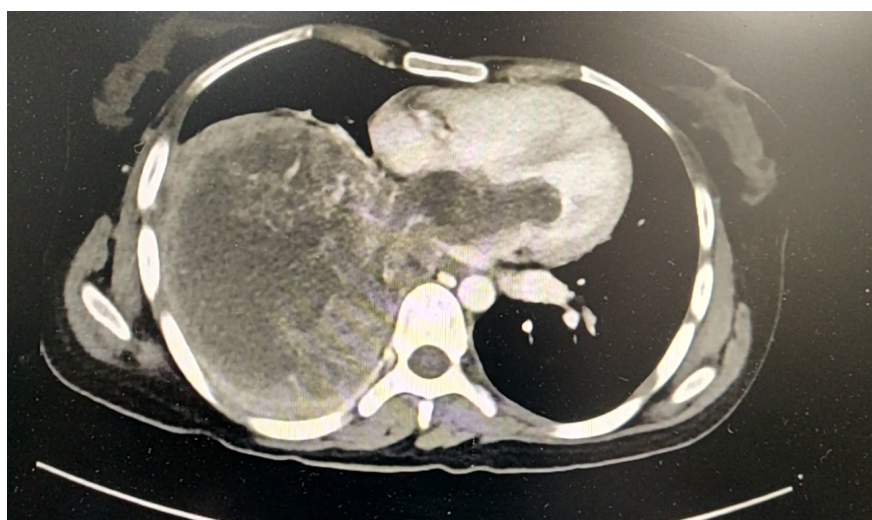
1. Chuah KL, Yap WM, Loh HL, Lim KH, Tan HW, Lim CH. Intravenous extension of sarcomatoid carcinoma of the lung to the left atrium. *Pathology (Phila)*. 2006;38(4):359–61.
2. Stella F, Dell'Amore A, Caroli G, Dolci G, Cassanelli N, Luciano G, et al. Surgical results and long-term follow-up of T4-non-small cell lung cancer invading the left atrium or the intrapericardial base of the pulmonary veins. *Interact Cardiovasc Thorac Surg*. 2012;14(4):415–9.
3. Shimizu J, Ikeda C, Arano Y, Adachi I, Morishita M, Yamaguchi S, et al. Advanced lung cancer invading the left atrium, treated with pneumonectomy combined with left atrium resection under cardiopulmonary bypass. *Ann Thorac Cardiovasc Surg*. 2010;16(4):286–90.



**Figure 1 . CT CHEST image showing right lung lower lobe mass**



**Figure 2 :CT Chest image showing right lung lower lobe mass entering the left atrium through pulmonary vein**



**Figure 3 : CT CHEST image showing right lung lower lobe mass and left atrial mass mimicking a left atrial myxoma**

- Funding : No funding source
- Conflict of interest : No conflict of Interests.
- Ethical approval : Not applicable
- Human rights : Not applicable

Statement of informed Consent -Written informed consent was obtained from the patient(s) for their anonymized information to be published in this article'

