

Computer-assisted planning with 3D printing for mandibular reconstruction caused by secondary osteomyelitis: A Case Report.

Mauricio Hale¹, Pablo Romero², Macarena Herrera², Daniela Espinoza¹, Joaquin Bravo², Nicolás Arturo Adams², and Guillaume Sérandour²

¹Hospital Del Salvador

²Universidad Austral de Chile

September 11, 2020

Abstract

A final Computer-assisted planning with 3D printing jaw reconstruction after two previous unsuccessful surgical reconstructions which led to pain, osteomyelitis and severe mandibular bone loss. The conjunction of actions used in this case allowed a successful and predictable outcome.

INTRODUCTION

Mandibular reconstruction after trauma or pathology is one of the cornerstones of oral and maxillofacial surgery¹. This reconstruction is needed in cases with a large amount of bone loss, comminuted fractures, severe traumas and infections leading to multiple bone sequestrations².

In the case of infections of the bone, different risk factors may enhance the speed in which the bone is lost, such as age, sex, poor oral hygiene, comorbidities (diabetes, hyperlipemia, autoimmune diseases) and drug abuse (cocaine, cannabinoid, tobacco smoking, hepatic cirrhosis due alcoholism)^{3, 4, 5, 6, 7-8}.

The four basic principles of successful reconstruction are: (1) establish an ideal orthognathic relationship; (2) a flush bone to graft/flap contact; (3) stable bony fixation; and (4) adequate, well-vascularized soft tissue coverage¹.

To achieve the previously established principles, the maxillofacial literature describes different surgical treatment plans. One temporary option is the use of external fixation of the mandible. It is considered a closed reduction type and provides semi-rigid fixation for fractured segments². One of its main advantages is to minimize the possible complications when compared to open surgical treatment for reduction and stabilization of fractures⁹.

Sometimes the fractured bone contact cannot be achieved due to the level of damage. In such cases grafts may work as a bridge to achieve fusion. Oral reconstruction is a difficult task because of the anatomical, functional and esthetics aspects that have to be taken into account in the surgery. Autogenous bone is the only graft material that possesses osteoconductive, osteoinductive, and osteogenic potential²⁻¹⁰.

This kind of surgical treatment is widely performed in cases such as the reviewed on this case study. Technology has allowed maxillofacial dentists to improve surgical processes over the last few years¹. Virtual surgical planning, computer-aided manufacturing and 3D printing gives the surgeon multiple advantages such as mirror the anatomy of the unaffected side, plan osteotomies, manipulate bony segments, fabricate surgical resection guides and create reconstruction plates¹.

This case study reports a jaw reconstruction in a 52-year-old male after a previous surgical reconstruction due to trauma that led to a case of osteomyelitis with severe bone loss on the body of the mandible.

CASE HISTORY

In July 2018, a 51-year-old male was referred to the Department of Oral & Maxillofacial Surgery of the Salvador Hospital, Santiago, Chile. In the clinical history the patient did not present any comorbidities or prescribed drugs, however a long history of substance abuse like alcohol, cocaine, cannabinoids, crack and tobacco was present. About his surgical history, in 2016 the patient suffered a mandible fracture which was surgically fixated.

When he arrived into the Salvador Hospital, he presented an active submandibular cutaneous fistula and left deviation of the jaw. Intraorally, poor hygiene, severe maxillo-mandibular discrepancy and malocclusion were found. Both, posterior crossbite and the dental midline deviation were on the left side due to a shortening of the mandibular body in the premolar area. In maximal intercuspation, only left posterior molars were in contact (Figure 1. A-E). A Computed Tomography (CT) was requested, where an extended bone loss was observed around the left canine and molars. Also a non-fixated plate could be seen in the same area (Figure 2. A-C).

The diagnosis was a suppurative osteomyelitis that went from the left mandibular canine to the second molar of the same side. An extensive surgical cleaning, together with the extraction of the affected bone, teeth and plate were performed. Two new reconstruction plates, 2.0 and 2.4 profile (Trauma One, ZimmerBiomet, Santiago, Chile), were used to stabilize the remaining mandibular segments (Figure 3. A-C).

The patient returned in August 2019 complaining of mandibular pain. He reported self removal of a loose metallic fragment inside his oral cavity. The patient presented a loosen reconstruction plate that broke through the oral mucosa and the skin of the chin. Also alteration of the mandibular dynamics was observed, caused by a lack of stabilization between the remaining mandibular fragments. (Figure 4. A-B) A new CT showed that only the distal part of the broken 2.0 plate remains and only the posterior part of the 2.4 plate was fixed to the bone. Loss in the contour of the mandible was evidenced both clinically and radiographically. (Figure 4. C-D)

Due to the extensive bone loss, instability of the mandible and acute symptoms of the patient, it was decided to remove both reconstruction plates, perform surgical cleaning and placement of four external fixations for two months (Kanhui, Empresa Tecnomedical, Santiago, Chile). Two external fixations were placed in the mandibular body of the unaffected side and the remaining two in the left side, more specifically in the condyle and ramus. (Figure 5. A-B)

During these two months, the DICOM file of a new Computed Tomography (TC) was transformed to a SLT archive in the free access software for virtual surgical planning 3DSlicer version 4.10.2. The metallic artefacts (external fixators) were virtually removed and the bone defect was virtually reconstructed. Within the software, the bone anatomy was mirrored to the unaffected side, allowing a virtual reconstruction of the bone loss segment. Also, the affected ramus was mesially repositioned into the glenoid fossa and segments were modified to reestablish the dental midline (Figure 6. A-C). The final virtual model was materialized in the 3D printer (Form 2, Formlabs, Somerville-Massachusetts, USA) to allow the extraoral preformation of a 2.4 surgical plate (Kanhui, Empresa Tecnomedical, Santiago, Chile) and estimate precisely the measure of the iliac crest graft. (Figure 6. D-I)

Following the virtual surgical planning, the patient was hospitalized and prepared for surgery. Both procedures, anterior iliac crest graft removal and the mandibular reconstruction were performed in one operatory step. (Figure 7.A) For the mandible reconstruction, skin incisions in the base of the mandible and osteomy-ocutaneous flaps were made to expose the remaining mandibular bone. Limited resection of the irregular bony margins of the defect were made to provide an optimal graft-mandible interface. (Figure 7.B). The already preformed surgical plate was placed and fixed in sequence for optimal adaptation. (Figure 7.C). The preformed iliac crest graft combined with Adbone TCP 3 – 4 mm particulate Xenograft (Kanhui, Empresa

Tecnomedical, Santiago, Chile) were placed in the defect and fixed to the plaque with pins located 1.5 cm apart from each other (Figure 7.D-E).

After the surgery, the patient stayed in the hospital 10 days, with strict hygiene of the skin in the postoperative period and pharmaceutical therapy of 600mg Clindamycin each 8h and 1g Ceftriaxone every 24h, both intravenous for the first 4 days and only 300mg oral Clindamycin every 8h for the next 14 days. He was called for control two weeks after leaving the hospital but he did not attend and returned after 3 months instead, where a clinical examination was performed and a control CT was requested. In the extraoral exam there was still some residual post-surgical inflammation, nevertheless a tendency to facial symmetry is appreciated and the scar and soft tissue are healthy and esthetically suitable (Figure 8. A-B). Intraorally no signs of periodontal disease, halitosis, erythema or suppuration were found, the oral mucosa was healthy, symmetrical dental midline, Angle's molar Class I with Class I canine relationship in the left side was achieved (Figure 8. C-D). The mandibular dynamic was asymptomatic with acceptable mandibular range movement and suitable oral functions according to the patient. Regarding the control CT, the graft was successfully preserved and the plaque maintained the proper mandibular arch relationship. (Figure 9. A-D)

DISCUSSION

In any type of bone trauma and fracture, there are different factors that must be taken into account for a successful intervention. In mandibular fractures, the reconstruction must be focused to maximize function and to produce an aesthetically pleasing appearance following primary or secondary surgery²⁻¹¹.

Particularly in this case, the first surgical approach was not successful, deriving in a case of Osteomyelitis with uncomfortable symptoms and complications for the patient, in addition to the need of a secondary surgical process. Postsurgical Osteomyelitis of the mandible is rare and appears to affect more men than women. The caseload of jaw osteomyelitis seems to have decreased considerably over the last fifty years thanks to the progress made in the field of oral hygiene, the appearance and the use of antibiotics, and early screening¹².

In this case, the patient had multiple risk factors for mandibular fracture which should have been identified in order to prevent the later Osteomyelitis. One of them was the smoking habit. Research shows that smoking may have detrimental effects on the skeletal system, leading to lower bone mass and mineral density. Furthermore, smokers submitted to orthopedic surgery have an increased risk of delayed fracture healing, complications (e.g., infections and non-union fractures), and longer hospital stays⁸. Also the patient had alcohol induced hepatic cirrhosis that tends to deteriorate both trabecular and cortical bone microarchitecture increasing the susceptibility to low-trauma fractures. The cannabinoid and cocaine abuse must be emphasized. Studies have shown that the central nervous system, including neurons and glial cells, plays an important role in regulating bone metabolism and therefore in the pathology of osteoporosis through cannabinoid receptors (CB1 and CB2), which are involved in pain modulation⁶. Cocaine causes both local anesthesia and vasoconstriction. The vasoconstriction may lead to necrosis, chemical irritation, mechanical trauma, bacterial infection, immunosuppression, and osteoblast inhibition. The combination of decreased oxygen tension, inflammation, irritation, and open wounds creates an ideal environment for infection with common⁴⁻¹³.

The abuse of multiple drugs and comorbidities in this case may have increased the susceptibility from the patient to the osteomyelitis after his first intervention and later poor osseointegration of the surgical plates after the second surgery.

In this case a two-step surgery with external fixations was chosen, due to the conditions in which the patient arrived at the Hospital. The research on the field of external fixations shows that the main indications for its use are large bone loss caused by tumor resections, infections leading to multiple bone sequestration, comminution and severe trauma with substance loss²⁻¹⁴⁻¹⁵. In cases such as this one, where large bone defects are present, a first approach with internal fixation surgery has an inherent high risk of nonunion and infections. The aim of the external fixators is to maintain the best patient anatomy and reduce pain, before they can benefit from optimal secondary reconstructive surgical procedure¹⁴. It must be also taken

into account that, because of the general nature and severity of the mandibular fractures treated by external fixation, a high complication rate of up to 35% has been reported. Postoperative infections, cellulitis around the pins, nonunions, malocclusions, and pin loosening are potentially frequent with this fixation technique. External fixation remains a quick, safe, and simple method to treat mandible fractures in selected clinical situations¹⁵.

Recently, computer-assisted navigation technology has become common in many medical fields. Its advantages include improvements in the accuracy of maxillofacial bone surgery, avoiding injury to vital structures, shortening of the operation time reducing flap ischemia duration and is cost-effective, despite the expensive technology^{1, 15-16}. Maxillofacial reconstructive surgery requires a high standard of surgical precision and dimensional errors are low in 3D printing, with discrepancies between STL models and 3D-printed models typically smaller than an imaging voxel (< 1 mm), being highly accurate in the surgical planification, compared with conventional surgery¹⁶. Also, Computer-assisted surgery (CAS) offers the ability to plan osteotomies, mirror the unaffected mandible, evaluate the bone plate relationships for positioning of dental implants, create surgical resection guides and fabricate patient-specific reconstruction plates¹⁻¹⁶.

In cases of large bone loss like as the one seen in this case report, the use of VSP and CAS could be beneficial for predictive outcomes and high standard esthetic and functionality in the maxillofacial area.

The non-vascularized iliac crest graft was chosen for this case for multiple reasons. The main reason being the severe compromise of blood vessels due to previous surgeries, restricting the chances of a successful anastomosis in a vascularized graft¹⁰⁻¹⁷. In this case the facial skin envelope and soft tissue volume was preserved, so no soft tissue graft was needed¹. Given the size of the bone loss (6cm) iliac crest graft was used because of the high success rate in less than 7cm defects, presentation of a high quality bone bulk, large amounts of bone marrow and resemblance with the curved lateral surface of the mandible¹⁰. Iliac crest donor site can be the first choice in isolated, short segment bone defects of mandible without soft tissue defect, which are resulted from trauma or tumor resection¹⁰⁻¹⁷. Also non-vascularized iliac crest bone grafts used to reconstruct defects of 7 cm or less have an 83% success rate¹.

In conclusion, multiple factors can be extrapolated from this case like habits, comorbidities and personal adhesion to therapy may be important in the prognosis of the final treatment. External fixations could be a good intermediate alternative for patients that require complex surgery, which may be previously planned due to virtual surgical planning with 3D printing. The aforementioned in conjunction with the correct graft choice, could aid to a predictable, aesthetically and functionally successful treatment.

REFERENCES

1. Foley BD, Thayer WP, Honeybrook A, McKenna S, Press S, et al. Mandibular Reconstruction Using Computer-Aided Design and Computer-Aided Manufacturing: An Analysis of Surgical Results. *J Oral Maxillofac Surg* . 2013;**71** :111-119.
2. Mendes de Alencar MG, De Bortoli MM, Gomes da Silva TC, Oliveira e Silva ED, Filho JR, et al. Suitability of Wrist External Fixator for Treatment of Mandibular Fracture. *J Craniofac Surg* . 2018;**00** (00).
3. Suei Y, Taguchi A, Tanimoto K, et al. Diagnosis and classification of mandibular osteomyelitis. *Oral Surg Oral Med Oral Pathol Oral Radiol Endod*. 2005;**100** :207-214
4. Rubin K. The manifestation of cocaine-induced midline destructive lesion in bone tissue and its identification in human skeletal remains. *Forensic Sci. Int* . 2013;**231** :408.e1-11.
5. Aspera-Werz RH, Chen T, Ehnert S, Zhu S, Fröhlich T, Nussler AK, et al. Cigarette Smoke Induces the Risk of Metabolic Bone Diseases: Transforming Growth Factor Beta Signaling Impairment via Dysfunctional Primary Cilia Affects Migration, Proliferation, and Differentiation of Human Mesenchymal Stem Cells. *Int. J. Mol. Sci* . 2019;**20** :2896-2915.
6. Wanga JJ, Hong-xia L, Wangc J, et al. Cannabinoid receptors in osteoporosis and osteoporotic

pain: a narrative update of review. *J Pharm Pharmacol*.2019;**71** :1469-1474.

7. Wakolbinger R, Muschitz C, Scheriau G, Bodlaj G, Kocijan R, Feichtinger X, Schanda JE, Haschka J, Resch H, Pietschmann P, et al. Bone microarchitecture and bone turnover in hepatic cirrhosis. *Osteoporos. Int*. 2019;**30** : 1195–1204.

8. Al-Bashaireh AM, Haddad LG, Weaver M, Chengguo X, Kelly DL, Yoon S, et al. The Effect of Tobacco Smoking on Bone Mass: An Overview of Pathophysiologic Mechanisms. *J. Osteoporos* . 2018;**2018** : 12062325.

9. Carvalho PH, Da Hora Sales PH, Sombra da Rocha S, Moura AM, Cavalcanti4 & Mello MJ, Junior JM, et al. Treatment of comminutive fractures by firearm projectiles with adapted wrist external fixator. *Oral Maxillofac Surg* . 2019;**23** :501-505.

10. Akbay E, Aydogan F, et al. Reconstruction of isolated mandibular bone defects with non-vascularized corticocancellous bone autograft and graft viability. *Auris Nasus Larynx* . 2014;**41** :56–62.

11. Wu J, Sun J, Shen SG, Xu B, Li J, Zhang S, et al. Computer-assisted navigation: its role in intraoperatively accurate mandibular reconstruction. *Oral Surg Oral Med Oral Pathol Oral Radiol* . 2016;**122** : 134-42.

12. Andre CV, Khonsari RH, Ernenwein D, Goudot P, Ruhin B, et al. Osteomyelitis of the jaws: A retrospective series of 40 patients. *J Stomatol Oral Maxillofac Surg* . 2017;**118** :261-264.

13. Shuster A, Reiser V, Trejo L, Lanculovici C, Kleinman S, Kaplan I, et al. Comparison of the histopathological characteristics of osteomyelitis, medication-related osteonecrosis of the jaw, and osteoradionecrosis. *Int. J. Oral Maxillofac. Surg*.2019;**48** : 17-22.

14. Marti-Flich L, Schlund M, Raoul G, Maes JM, Ferri J, Wojcik T, Nicot R, et al. Twenty-four years of experience in management of complex mandibular fractures with low cost, custom-made mandibular external fixation: A 65-patient series. *J Stomatol Oral Maxillofac Surg* . 2019;**121** :242-247.

15. Braid FH, Ziccardi VB, et al. External Fixation for Mandible Fractures. *Atlas Oral Maxillofacial Surg Clin N Am* . 2009;**17** :45–53.

16. Van Baara JC, Forouzanfara T, Libertona NP, Wintersb HA, Leusinka FK, et al. Accuracy of computer-assisted surgery in mandibular reconstruction: A systematic review. *Oral Oncol* . 2018;**84** :52-60.

17. Moura LB, Carvalho PH, Xavier CB, Post LK, Torriani MA, Santagata M, Chagas OL, et al. Autogenous non-vascularized bone graft in segmental mandibular reconstruction: a systematic review. *Int. J. Oral Maxillofac. Surg*. 2016;**45** : 1388–1394.

LIST OF FIGURES LEGENDS.

Figure 1. (A-C) Patient on admission, extraoral view. **(D-E)** Intraoral view of the patient with Osteomyelitis associated to mandibular fracture.

Figure 2. (A-C) Computed Tomography on admission, with bone loss of the left mandibular body.

Figure 3. (A-C) First surgery postoperative Computed Tomography, with reconstruction plates.

Figure 4. (A-B) Patient after 1 year of first surgery, intra and extraoral view. **(C-D)** Computed Tomography with broken 2.0 plate and lack of anterior fixation of the 2.4 plate.

Figure 5. (A-B) Postoperative view with external fixations.

Figure 6. (A-C) Computer-assisted Planning. **(D-I)** Epoxi resin 3D Printing model, extraoral preformation of the surgical plate.

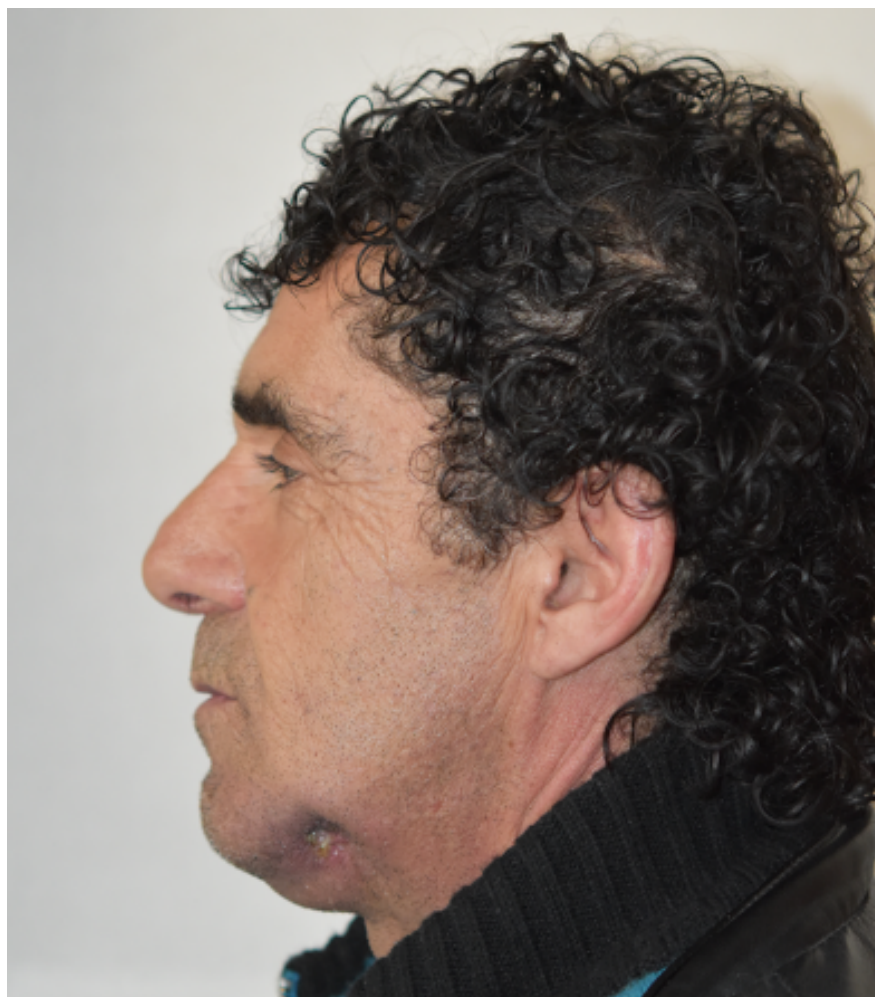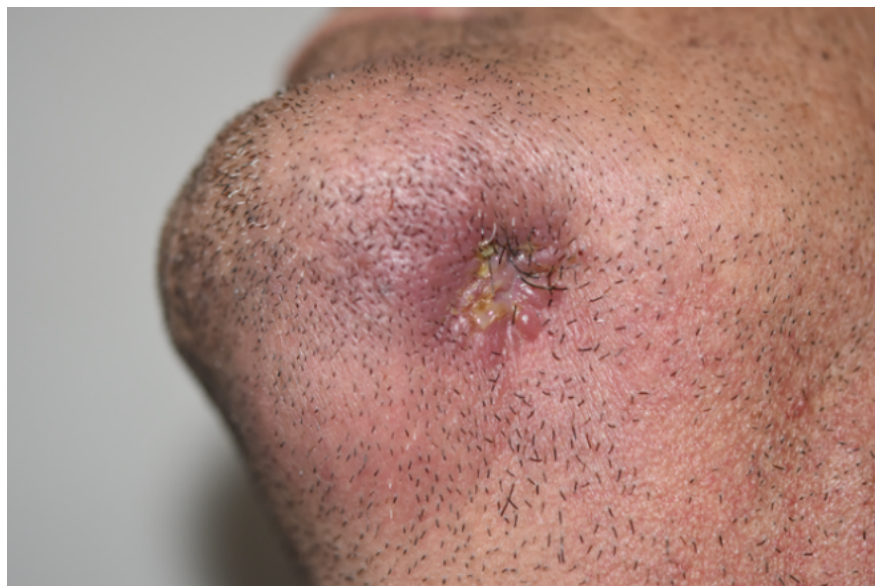Figure 7. (A) Non-vascularized iliac crest graft. **(B)** First approach of the final surgery. **(C)** Preformed reconstruction plate fixed to the mandibular segments. **(D-E)** Non-vascularized iliac crest graft with Xenograft fixed to the plate.

Figure 8. (A-B) 3-months control after final surgery, extraoral view. **(C-D)** 3-months control after final surgery, intraoral view.

Figure 9. (A-B) 3-months after final surgery, control CT.**(C-D)** 5-months after final surgery, isolated mandible.

FIGURES





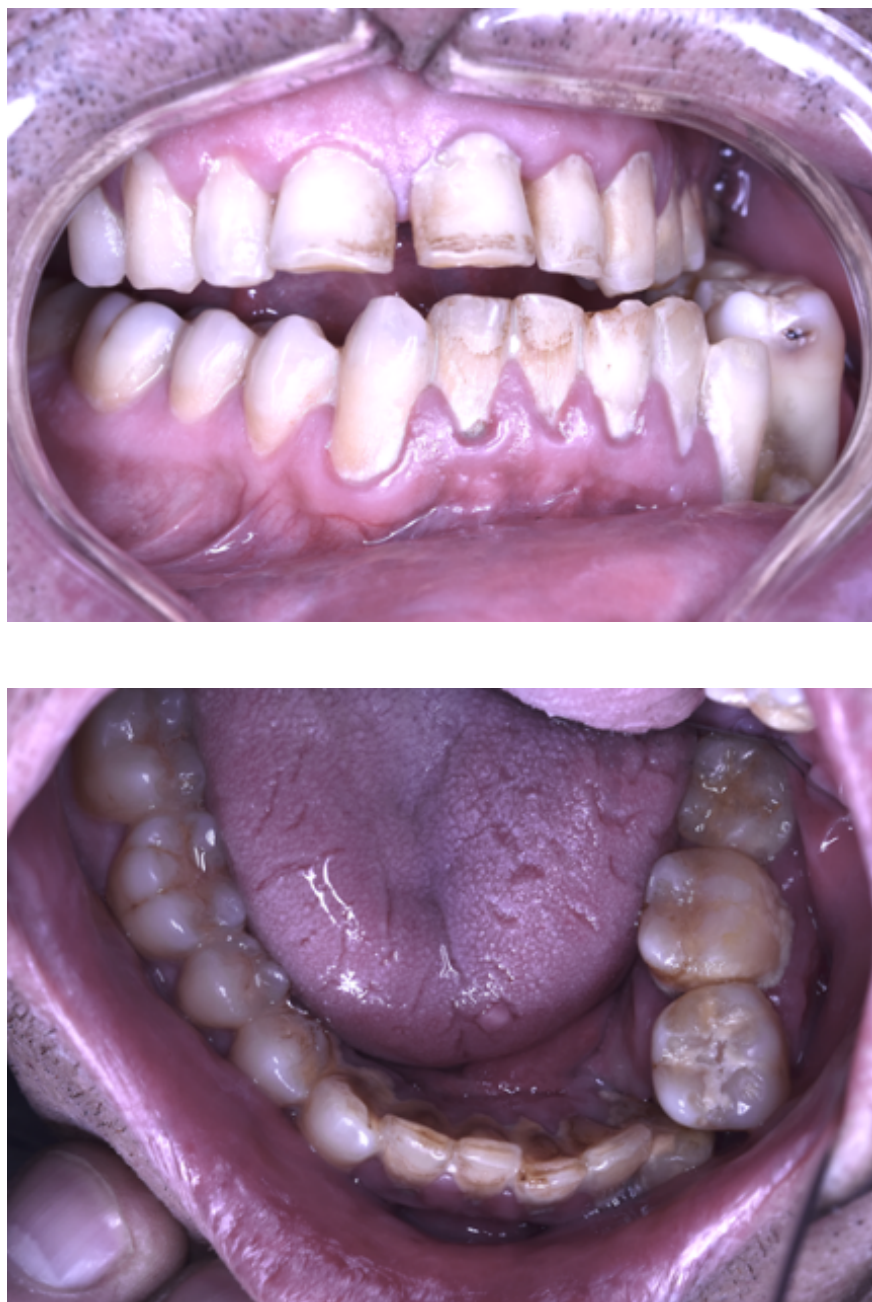
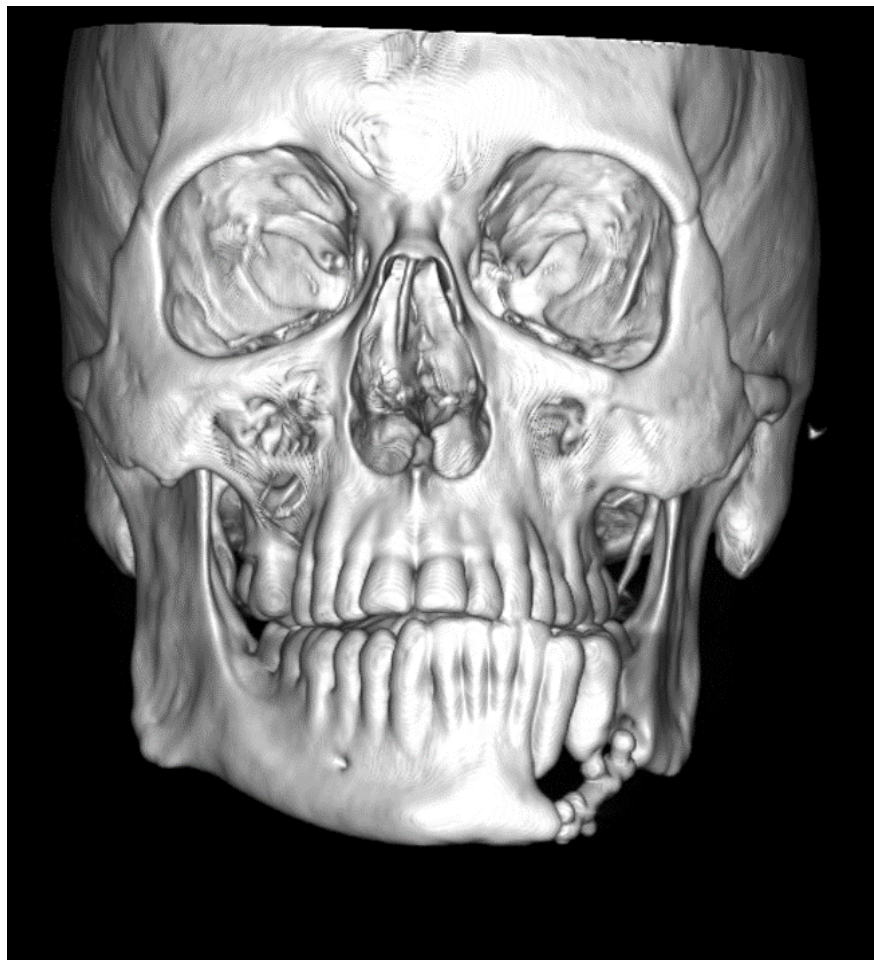
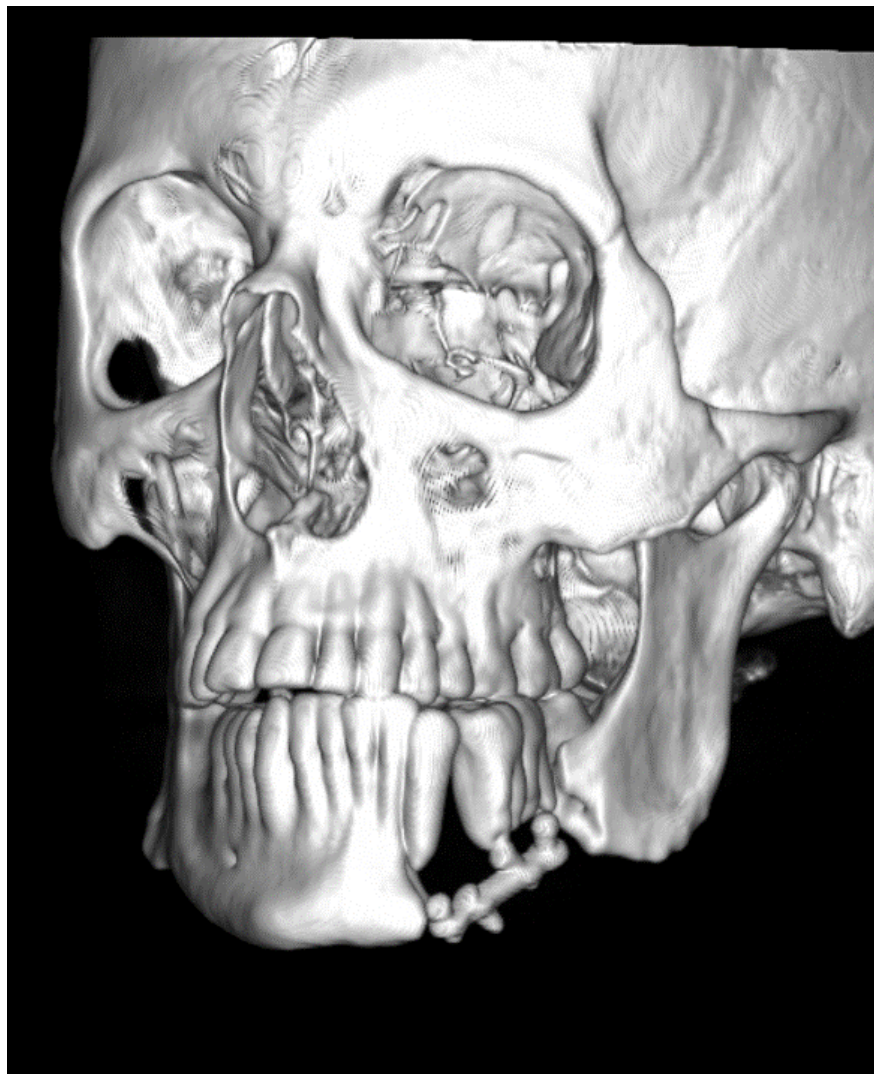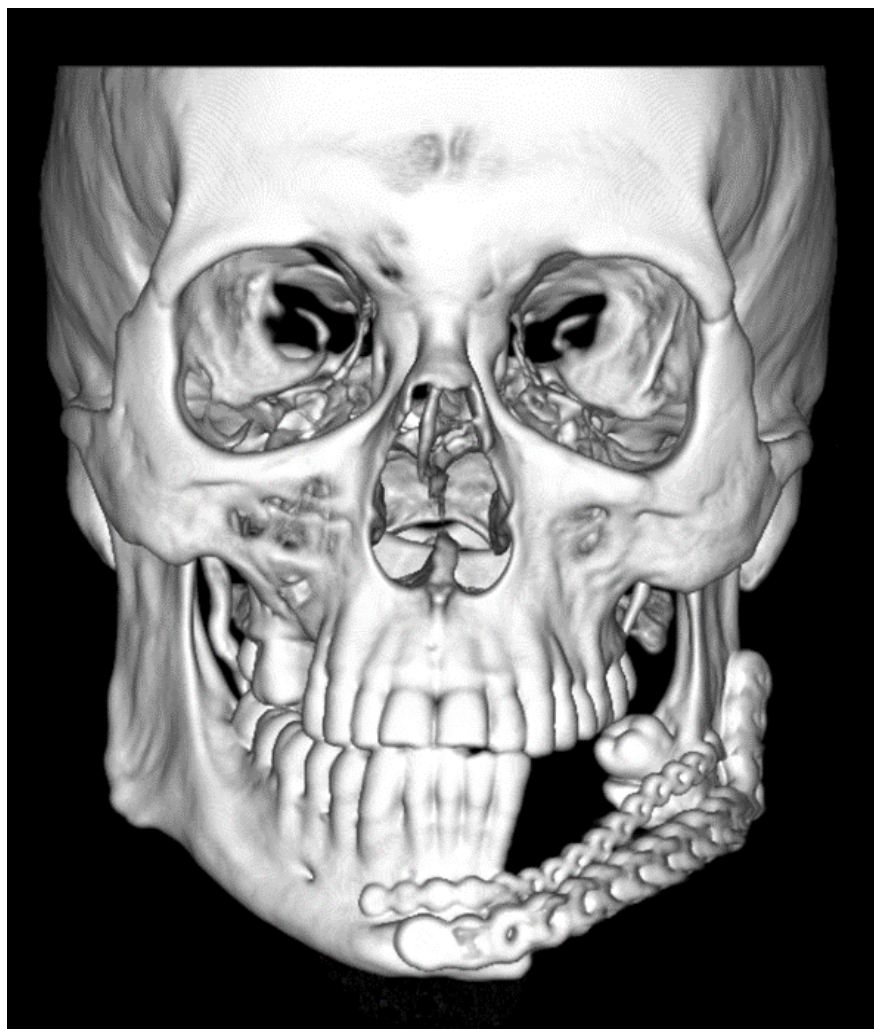
Figure 1.





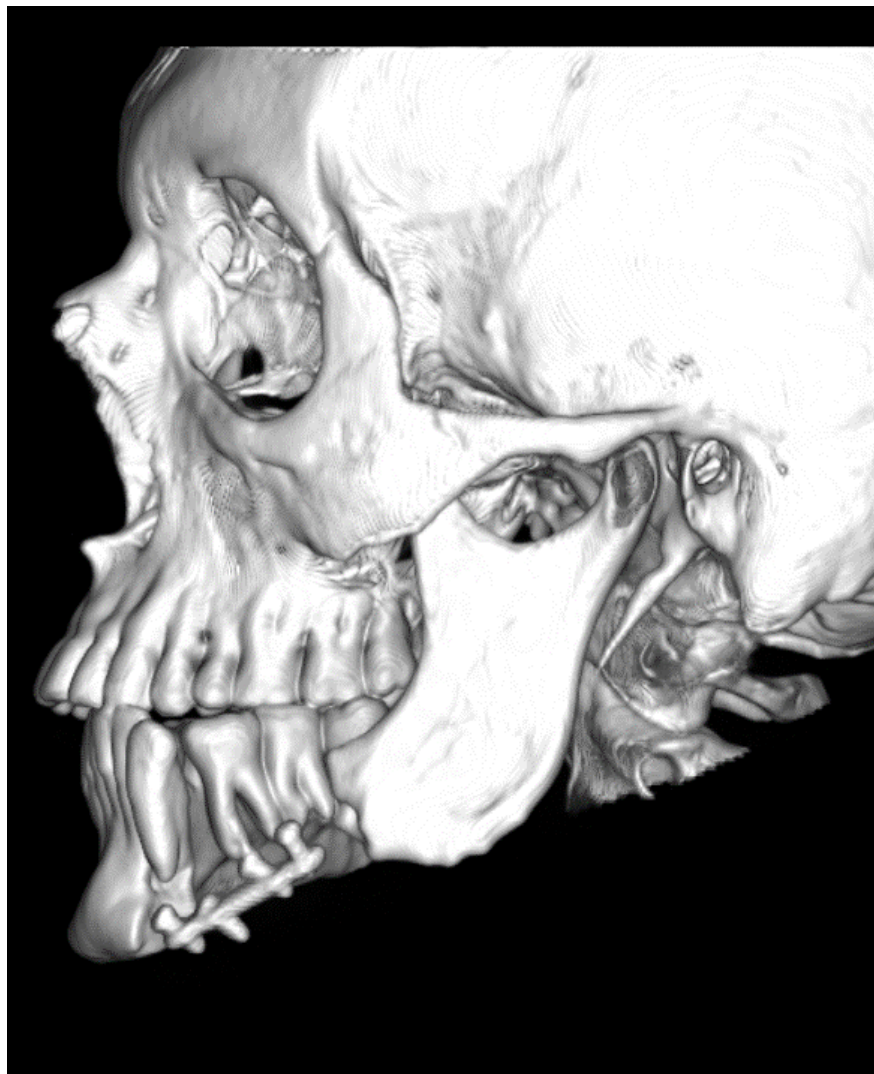

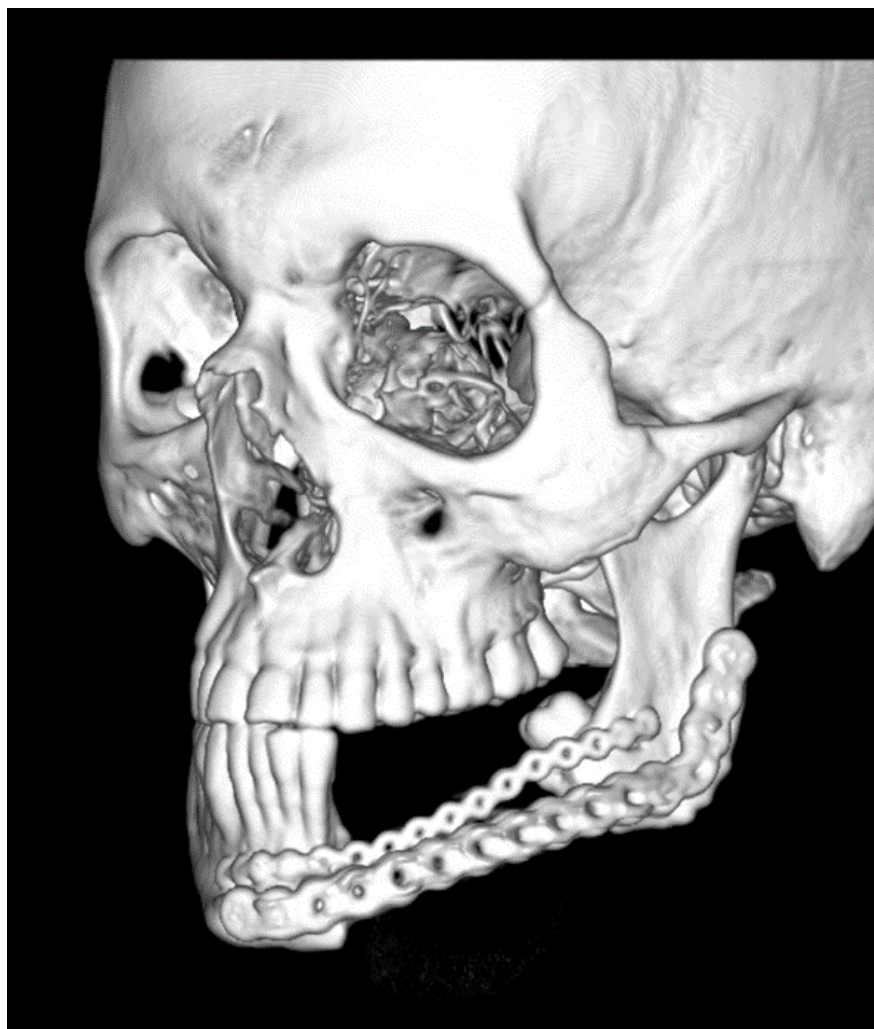Figure 2.





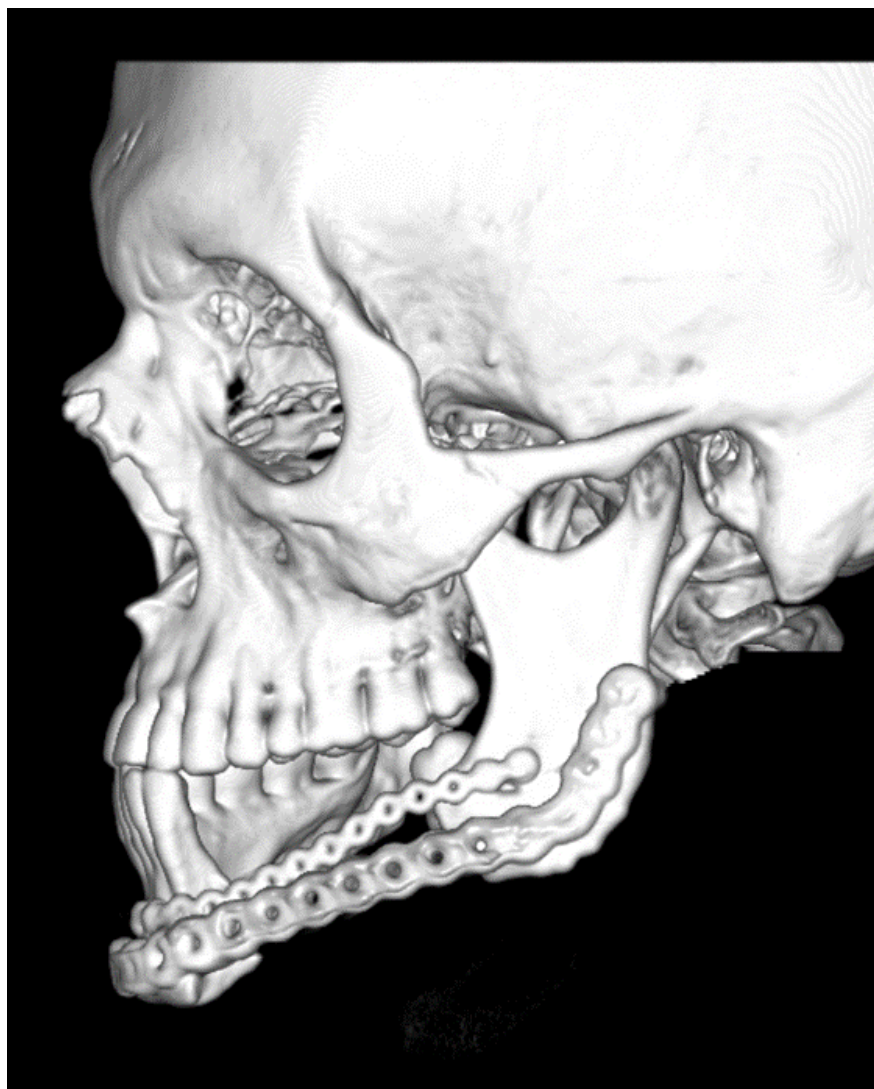
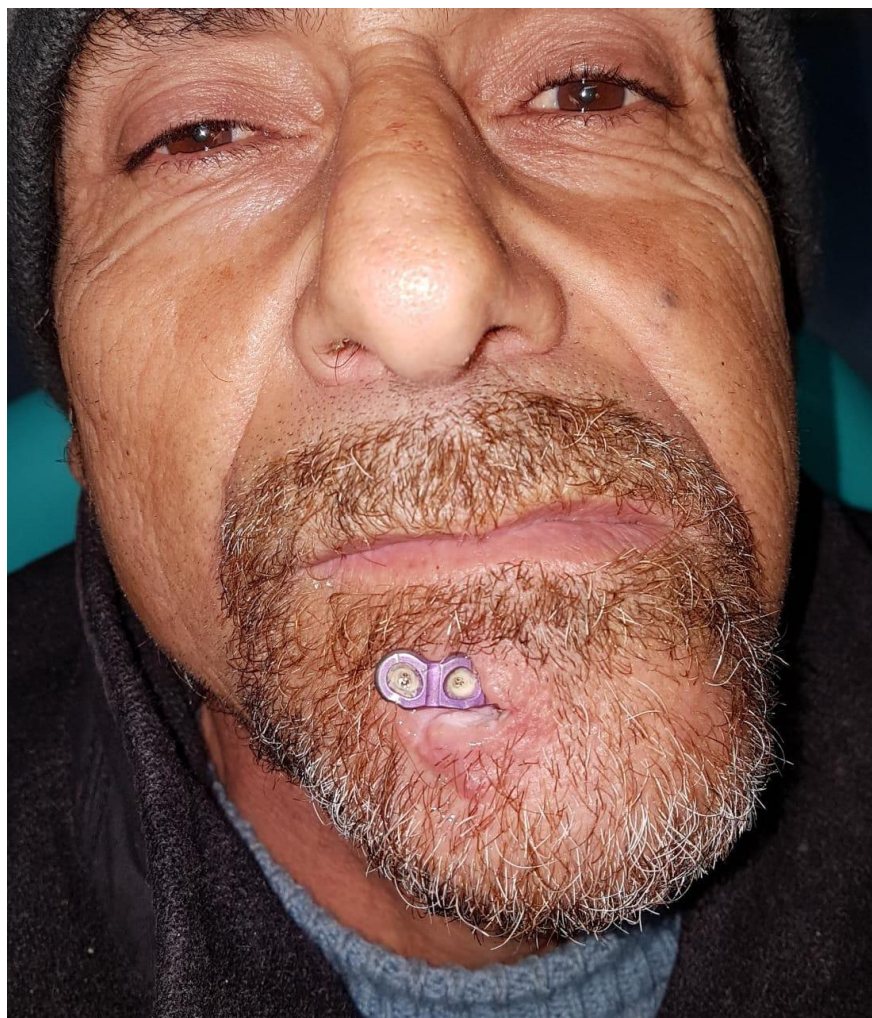
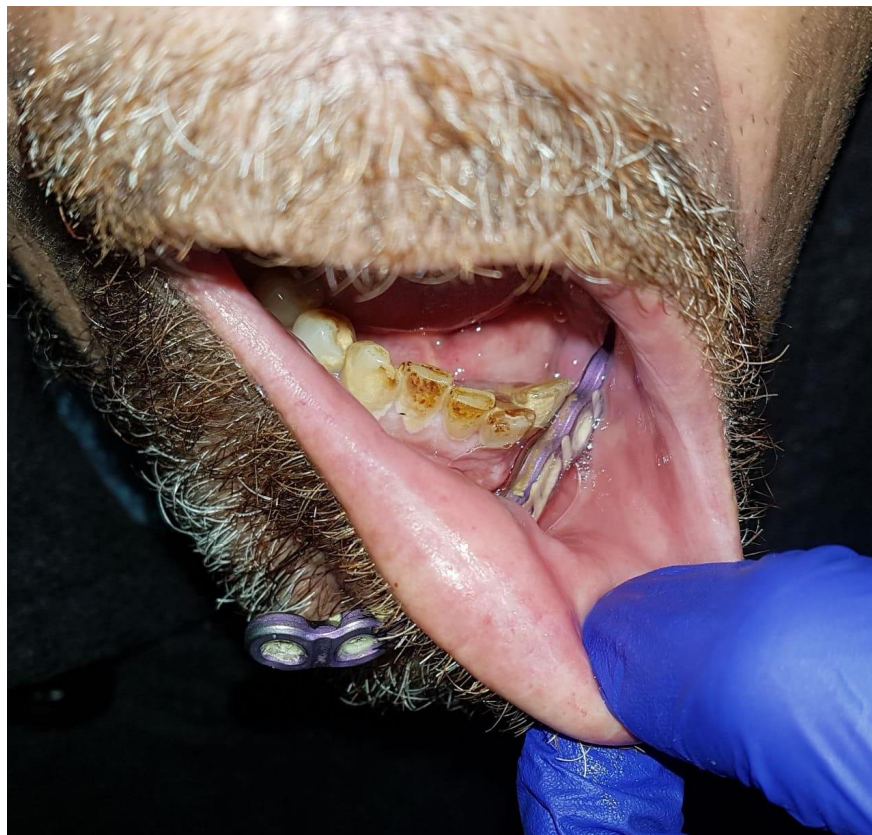
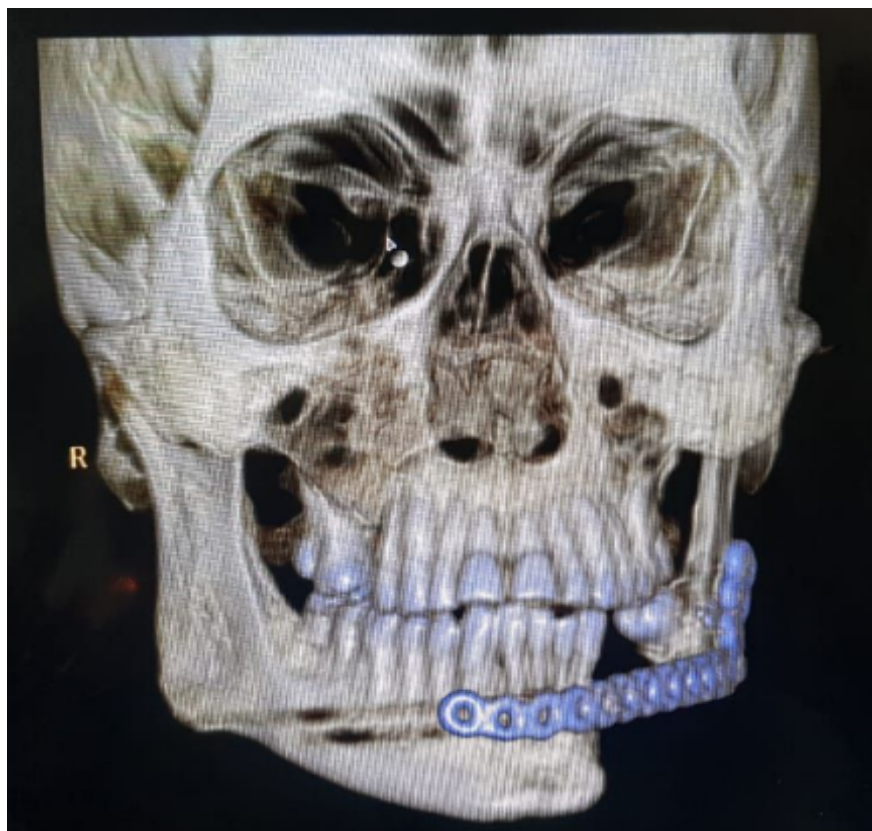Figure 3.







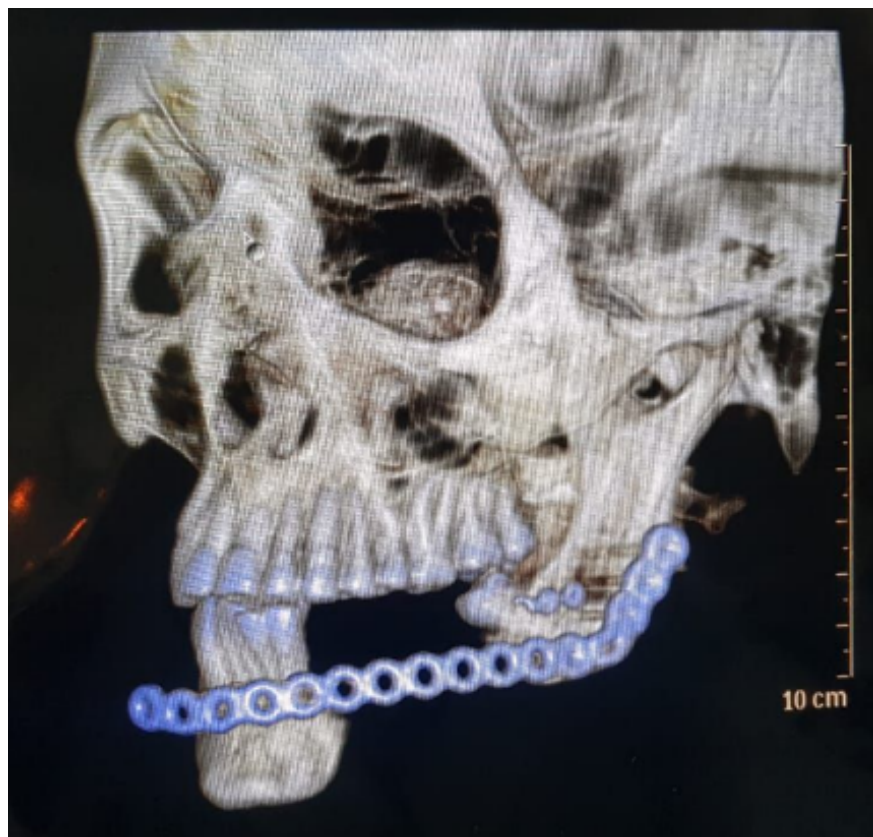


Figure 4.

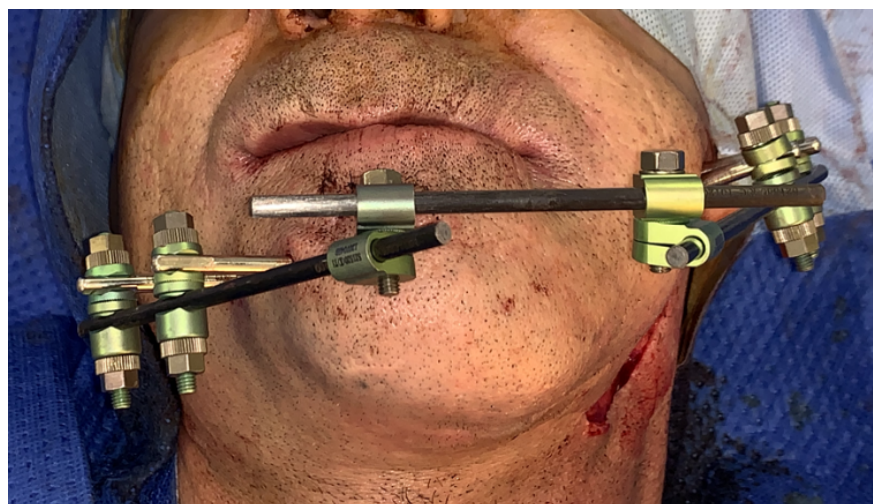
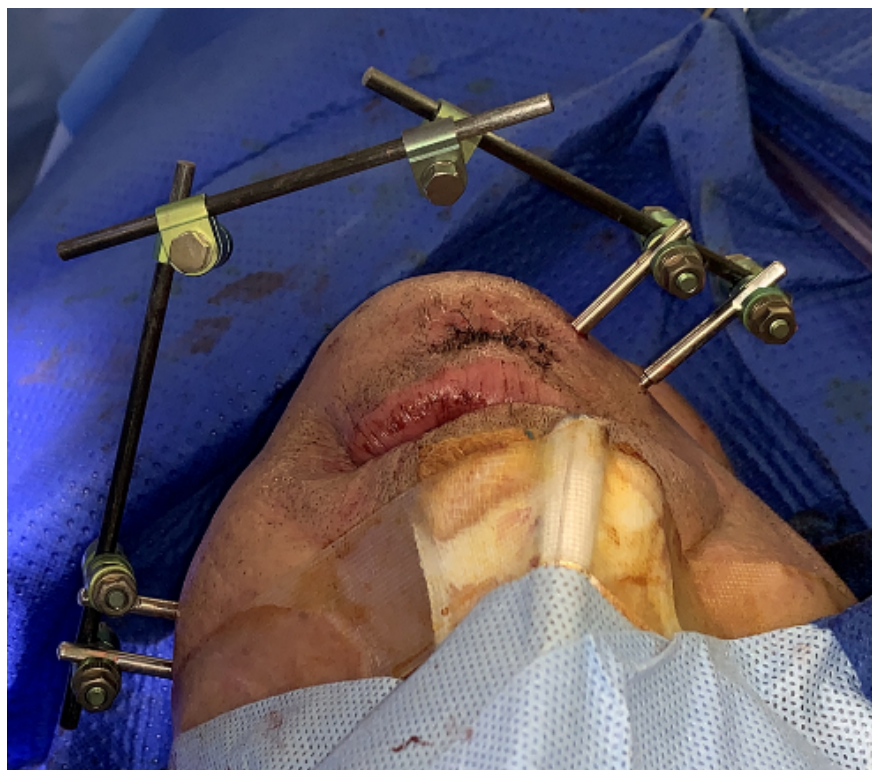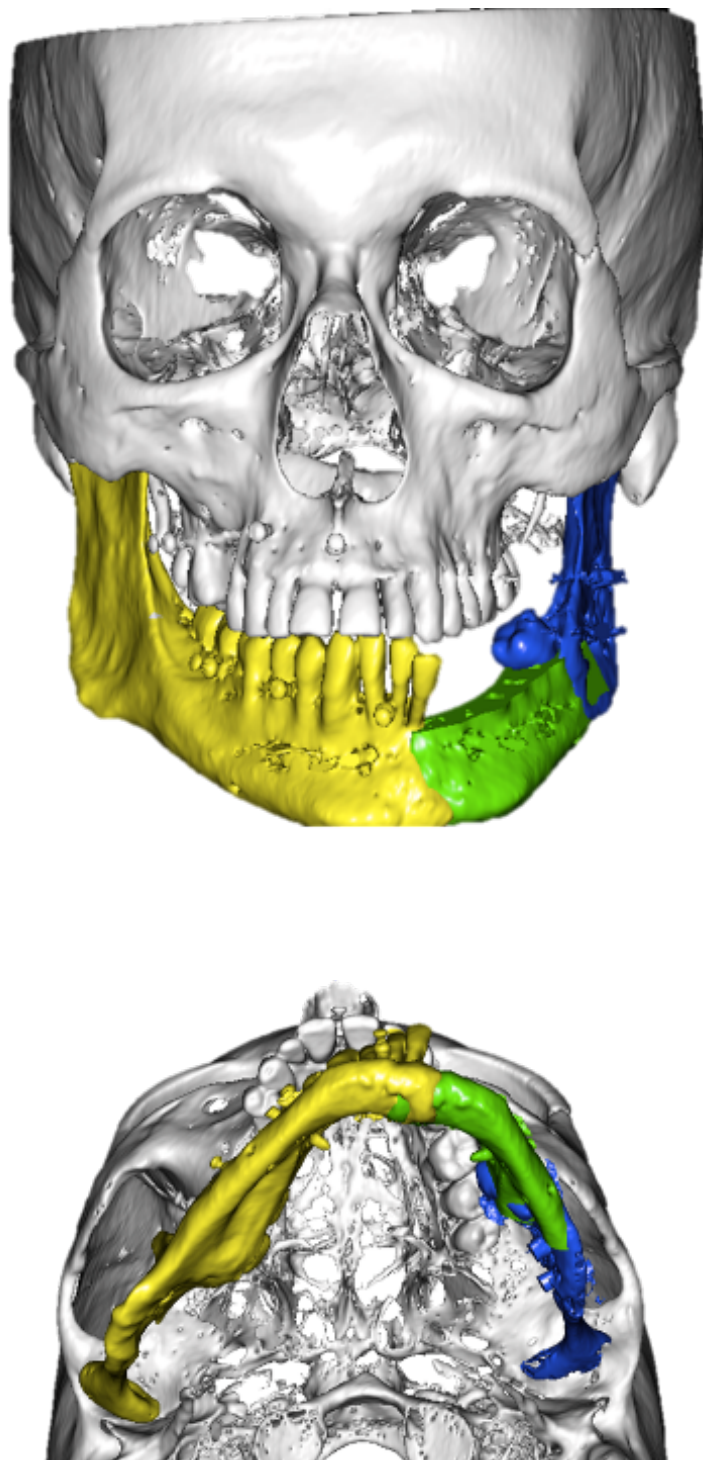
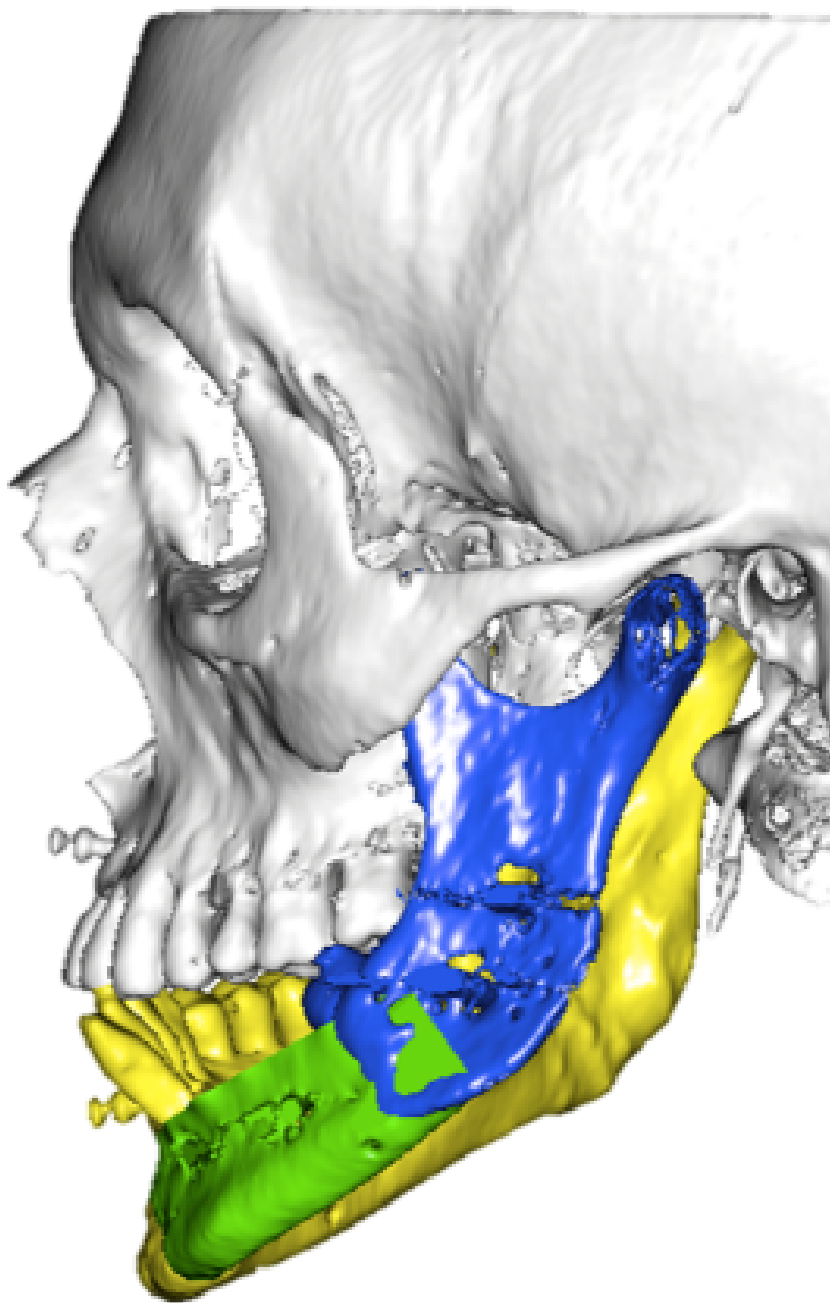


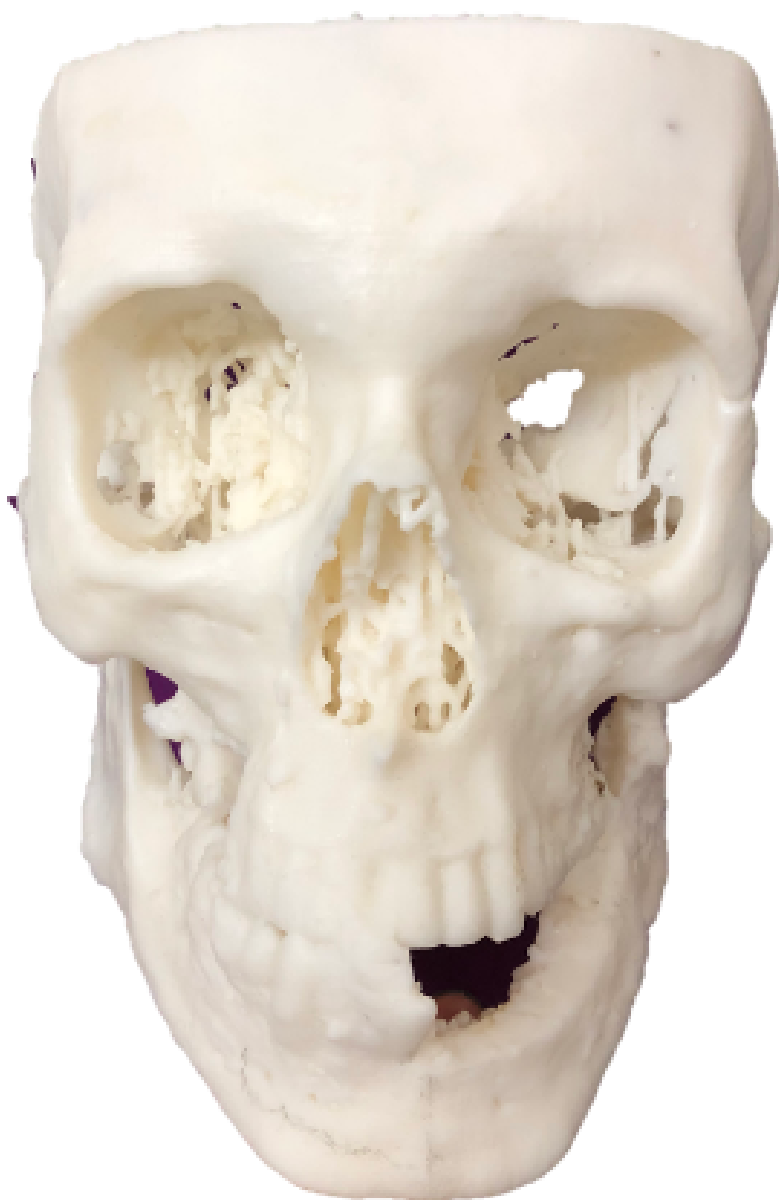

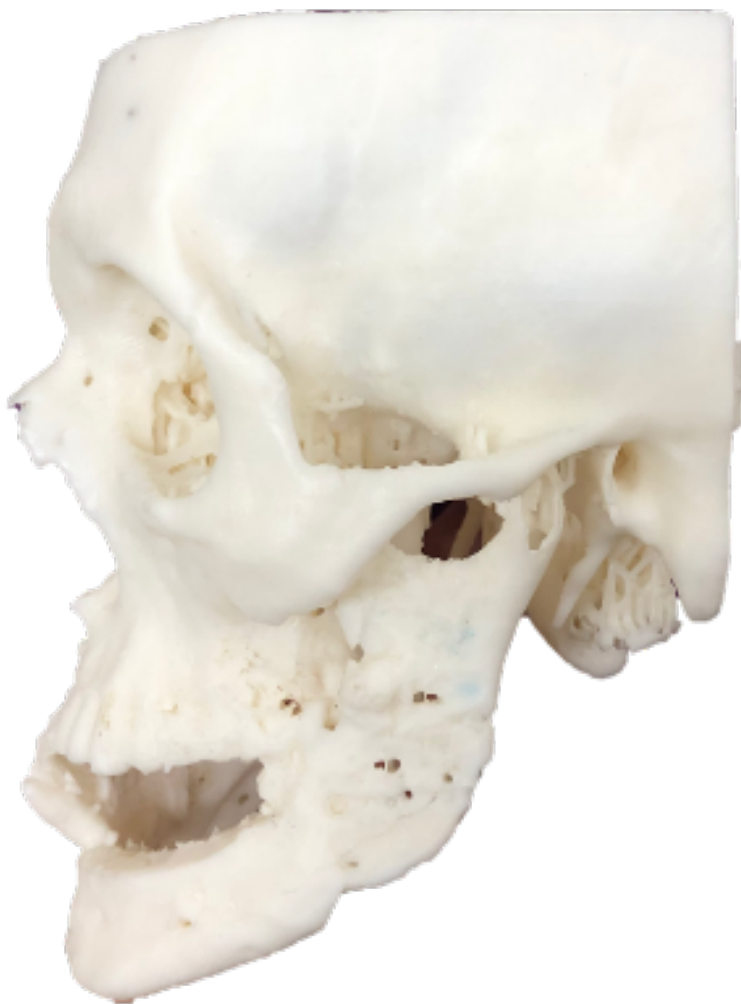Figure 5.







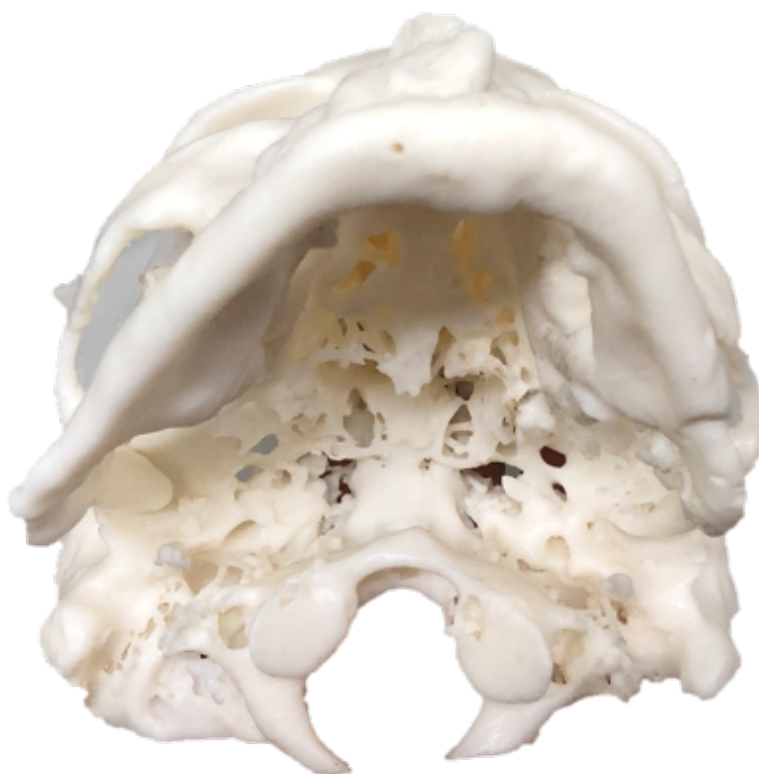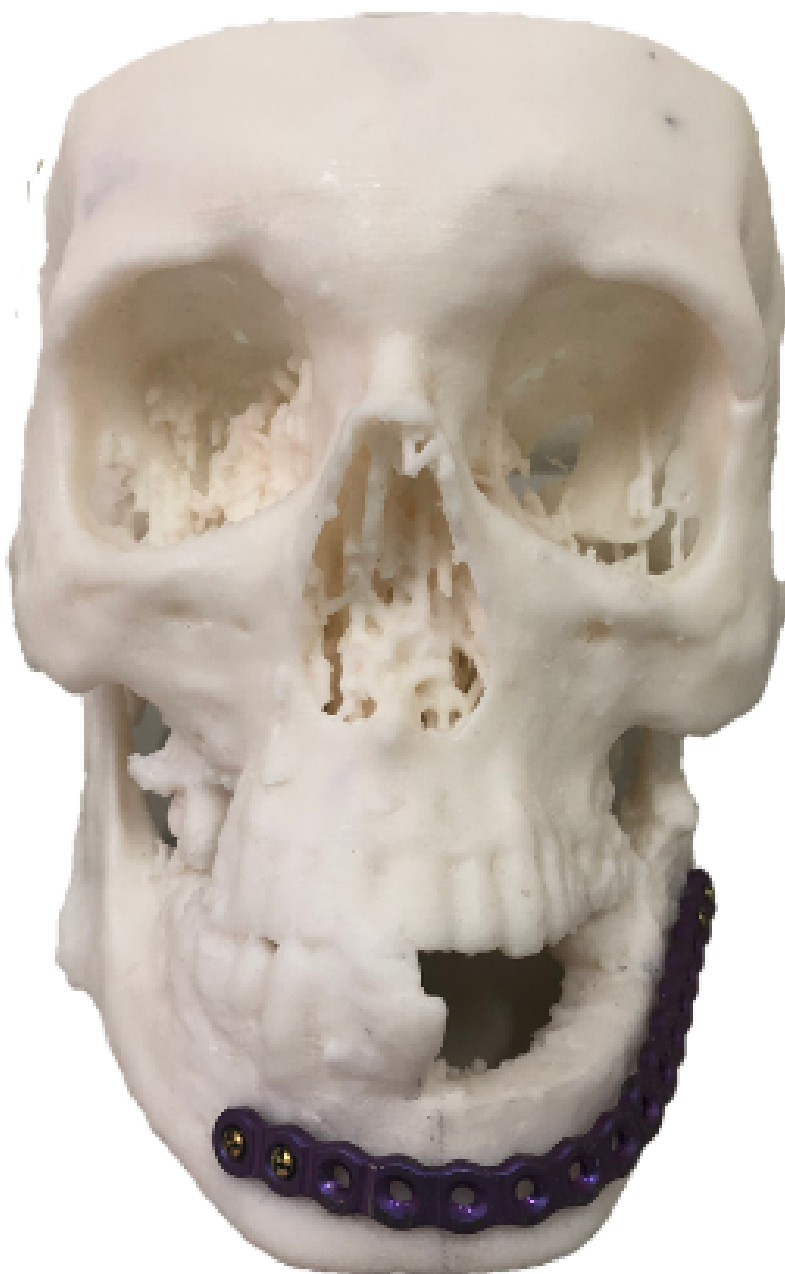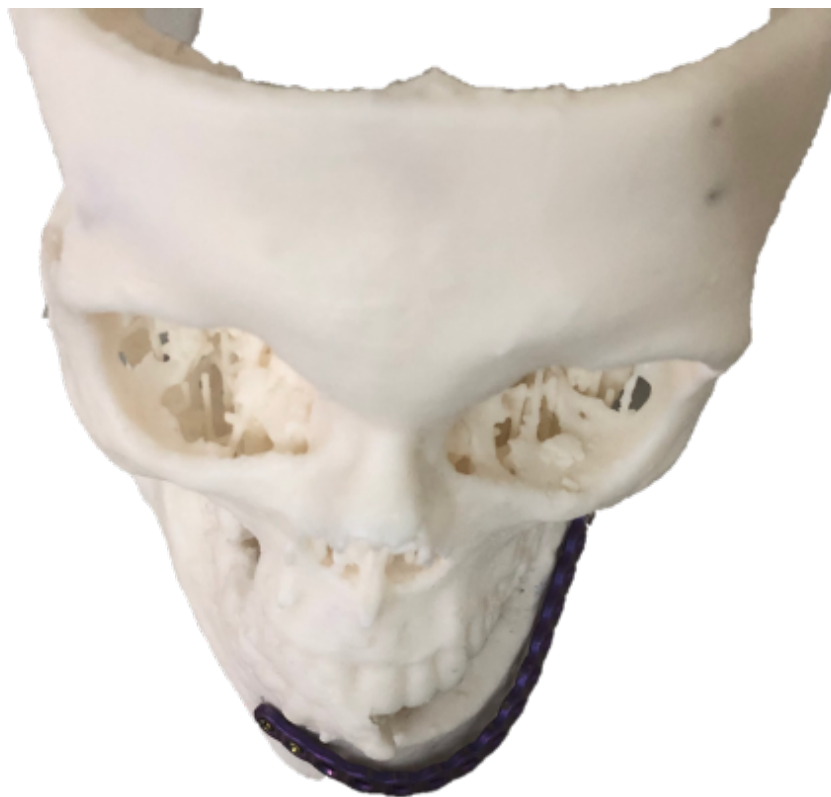




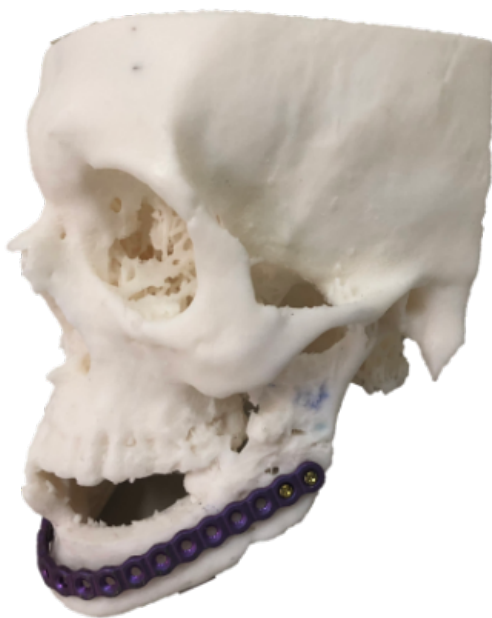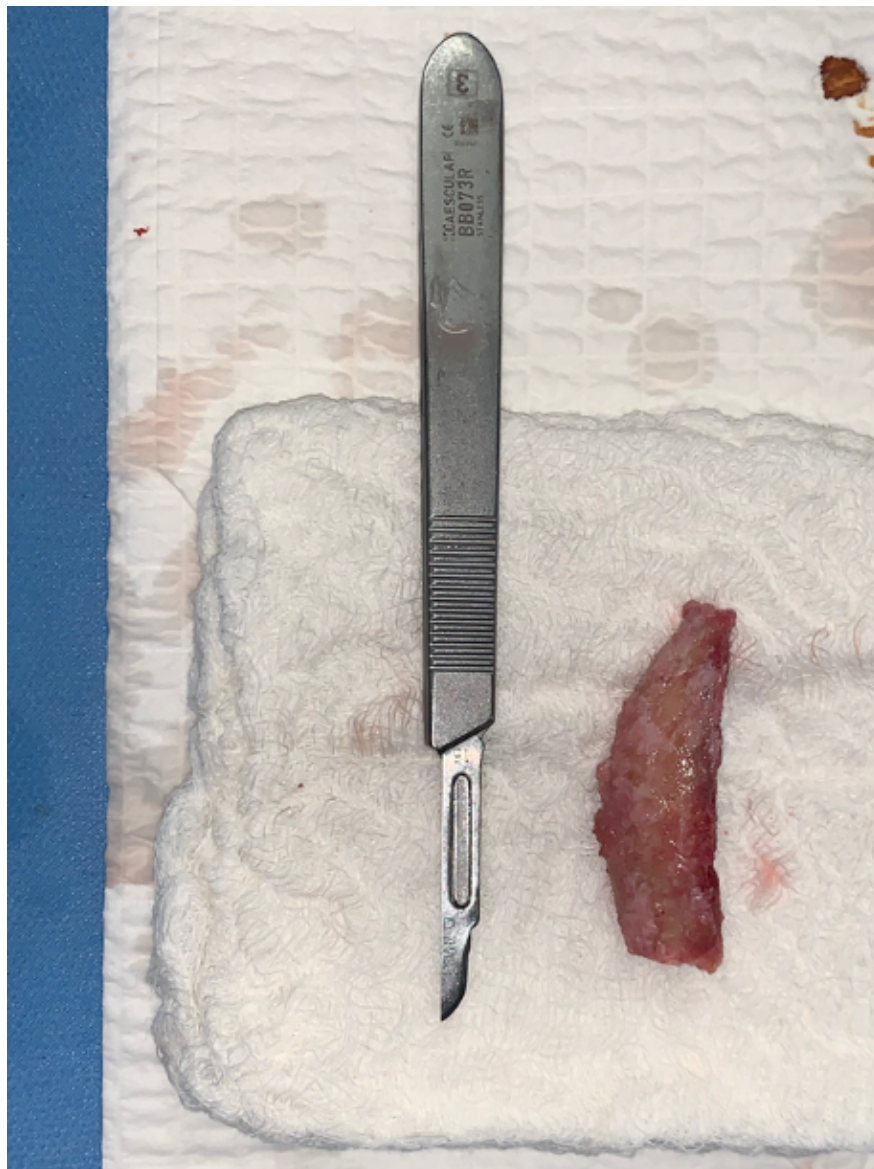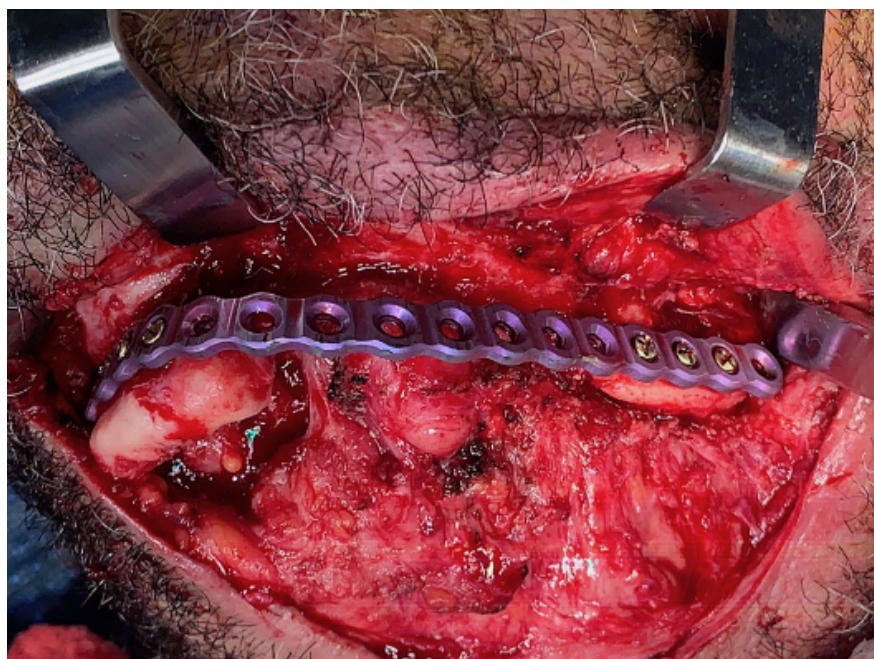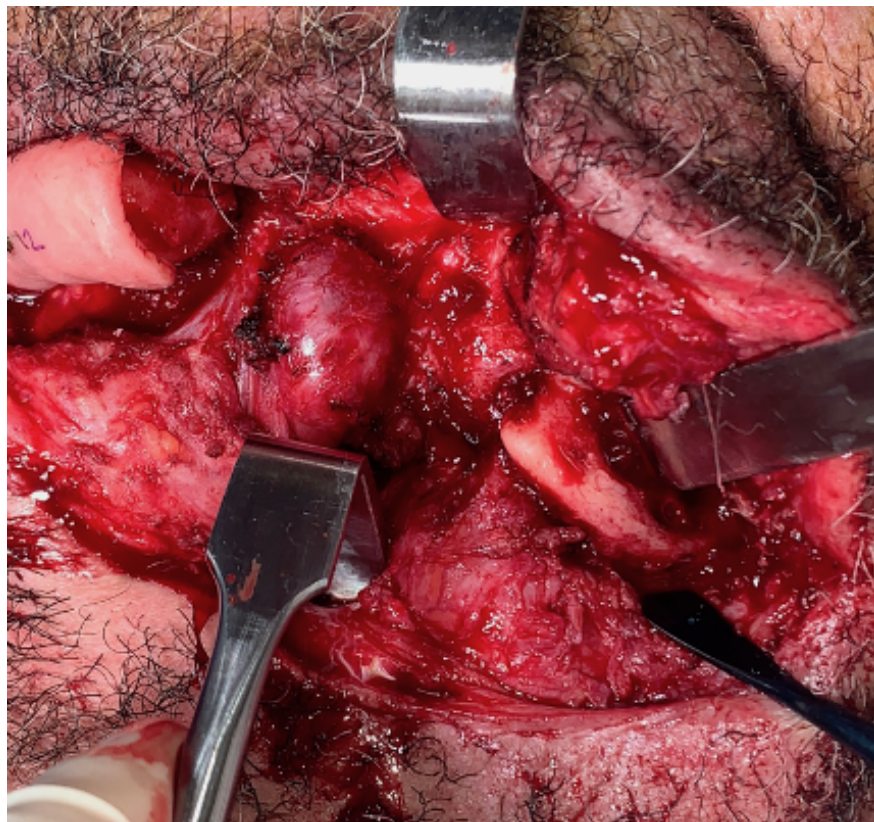






Figure 6.





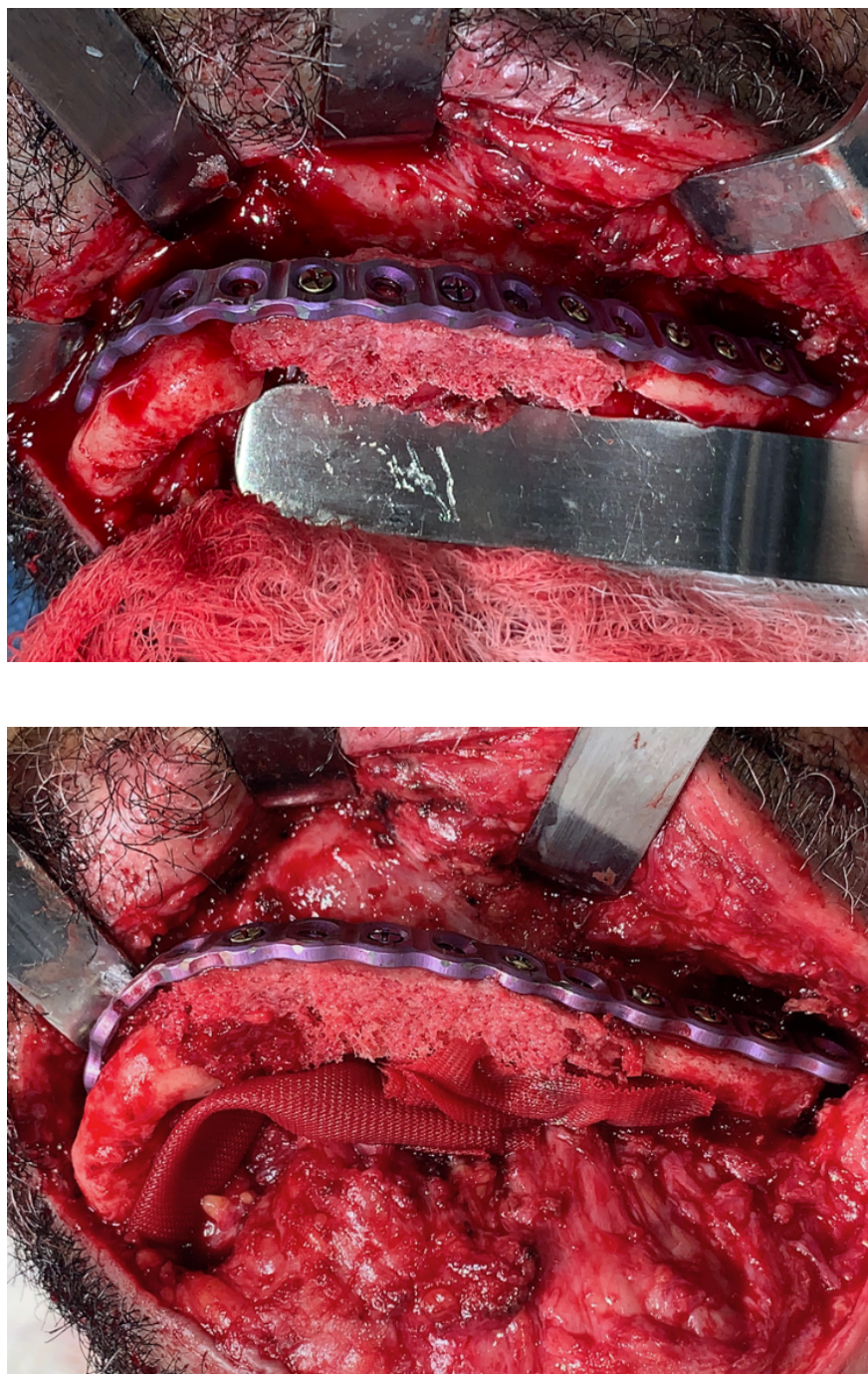
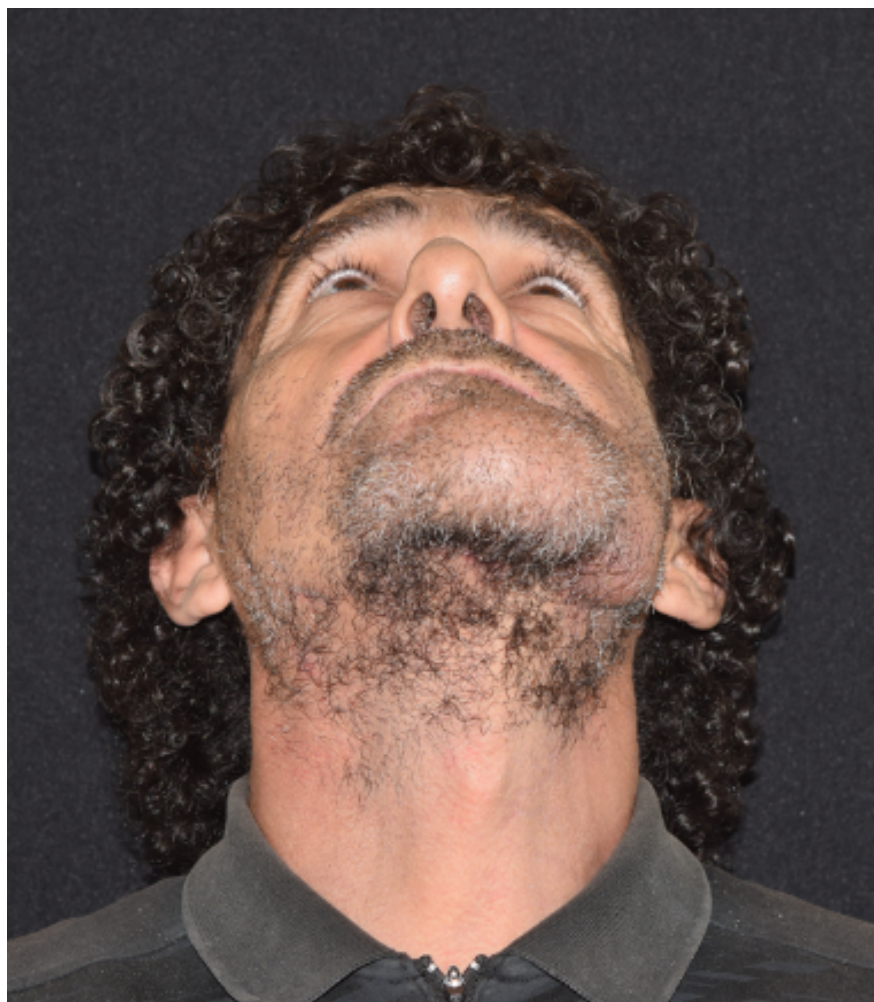
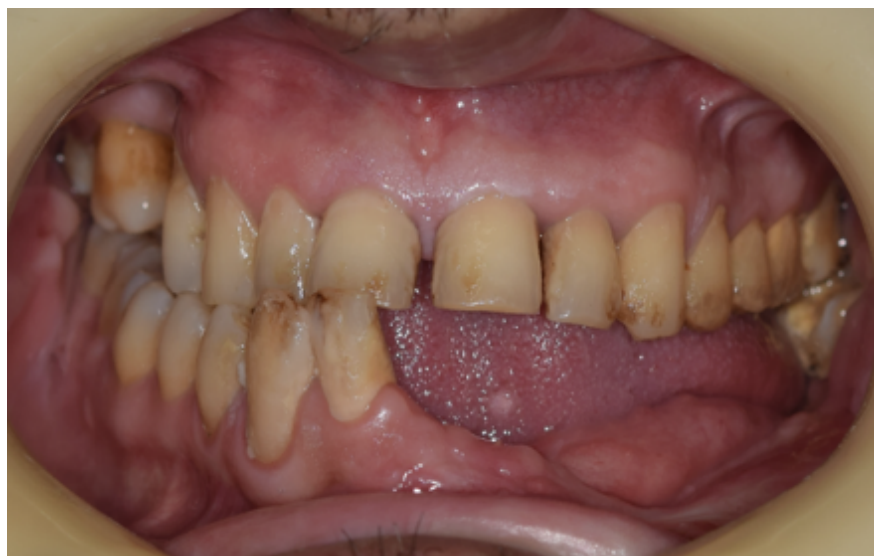
Figure 7.


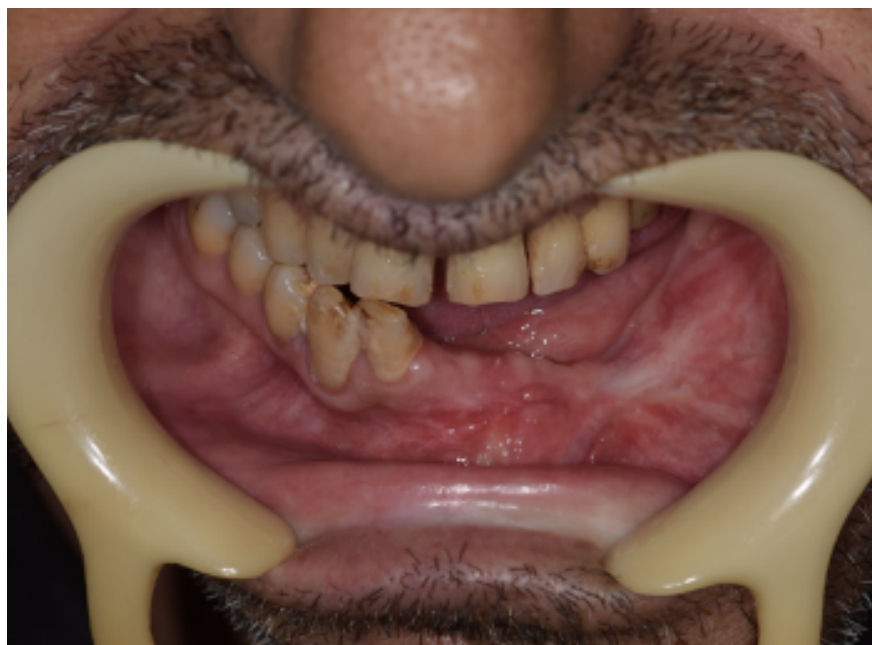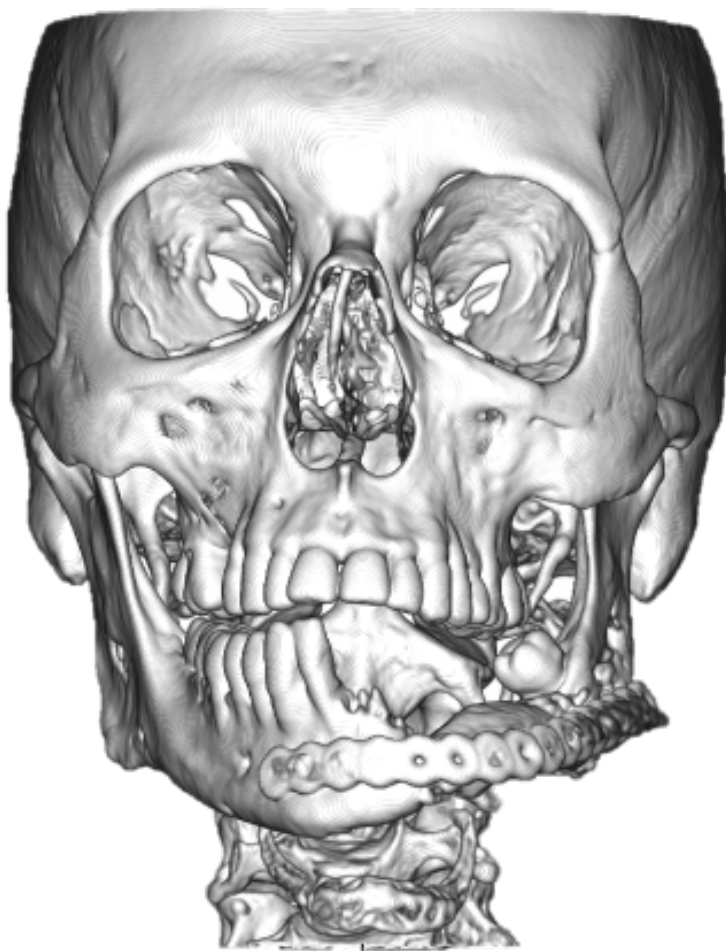
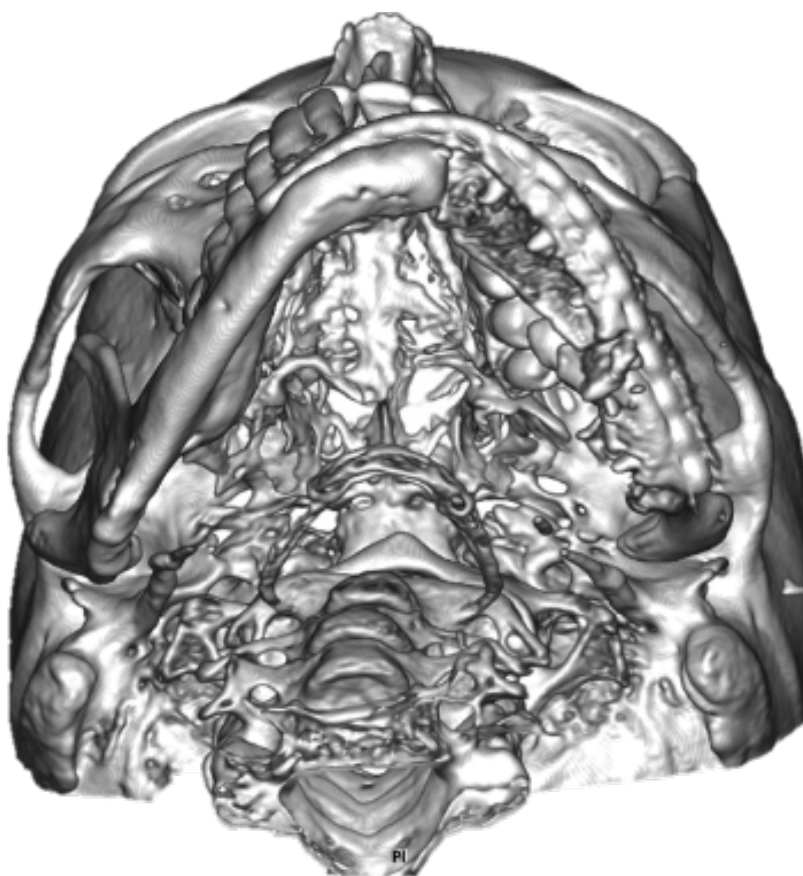




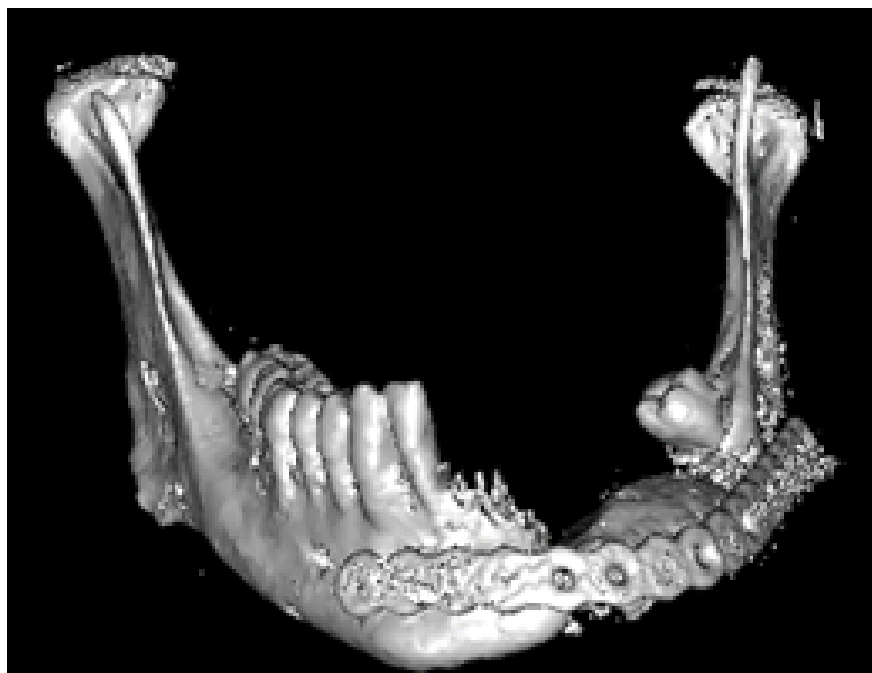

Figure 8.





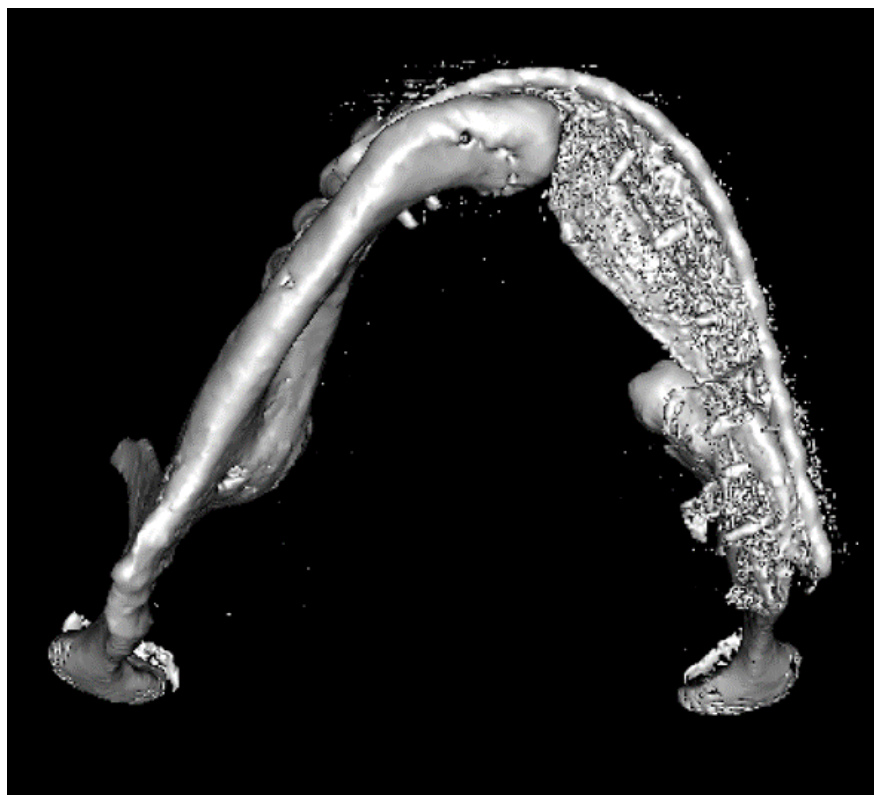


Figure 9.