

Analysis of droplet splatter patterns during Coblation tonsil surgery in the Covid-19 pandemic

Grace Khong¹, Jaya Bhat¹, Ravi Sharma¹, and Samuel Leong²

¹Alder Hey Children's NHS Foundation Trust

²Liverpool University Hospitals NHS Foundation Trust

September 14, 2020

Abstract

Objectives: To assess droplet splatter around the surgical field and surgeon during simulated Coblation tonsil surgery to better inform on mitigation strategies and evaluate choice of personal protective equipment. **Design:** Observational study **Setting:** Operation theatre suite at a tertiary hospital **Participants:** Life size head model was used to simulate tonsil surgery using fluorescein-soaked strawberries to mimic tonsils **Main outcome measures:** The Coblation wand was activated over the strawberries for 5 minutes. This was repeated 5 times with 2 surgeons (total of 10 data sets). The presence of droplet around the surgical field and anatomical subsites on the surgeon was assessed in binary fashion: present or not present. The results were collated as frequency of droplet detection and illustrated as a heatmap; 0 = white, 1-2 = yellow, 3-4 = orange and 5 = red. **Results:** Fluorescein droplets were detected in all four quadrants of the surgical field. The frequency of splatter was greatest in the upper (nearest to surgeon) and lower quadrants. There were detectable splatter droplets on the surgeon; most frequently occurring on the hands followed by the forearm. Droplets were also detected on the visor, neck, and chest albeit less frequently. However, none were detected on the upper arms. **Conclusion:** Droplet splatter can be detected in the immediate surgical field as well as on the surgeon. Although wearing a face visor does not prevent splatter on the surgical mask or around the eyes, it should be considered when undertaking tonsil surgery as well as a properly fitted goggle.

Introduction

Tonsillectomy is a common ENT procedure commonly undertaken for recurrent tonsillitis or sleep disordered breathing. Blood splatter contamination occurring on the surgeon during tonsil surgery is well recognised in the literature¹¹Keogh IJ, Hone SW, Colreavey M, Walsh M. Blood splash and tonsillectomy: an underestimated hazard to the otolaryngologist. *J Laryngol Otol.* 2001 Jun;115(6):455-6. ²²Hanna BC, Thompson P, Smyth C, Gallagher G. Blood splash from different diathermy instruments during tonsillectomy. *J Laryngol Otol.* 2006; 120(11): 927 – 31.. In fact, tonsillectomy was the procedure most commonly resulting in patient's blood and secretions being detected on the surgeon's face³³Lakhani R, Loh Y, Zhang TT, Kothari P. A prospective study of blood splatter in ENT. *Eur Arch Otorhinolaryngol.* 2015 Jul;272(7):1809-12..

The current Covid-19 pandemic has highlighted many routine ENT operations, including tonsillectomy, as being an aerosol-generating procedure (AGP). The issue of AGP has been at the forefront of concerns raised by healthcare professionals and patient-focused groups alike because the coronavirus is in the oral and nasal cavities⁴⁴Kowalski LP, Sanabria A, Ridge JA, Ng WT, de Bree R, Rinaldo A, Takes RP, Mäkitie AA, Carvalho AL, Bradford CR, Paleri V, Hartl DM, Vander Poorten V, Nixon IJ, Piazza C, Lacy PD, Rodrigo JP, Guntinas-Lichius O, Mendenhall WM, D'Cruz A, Lee AWM, Ferlito A. COVID-19 pandemic: Effects and evidence-based recommendations for otolaryngology and head and neck surgery practice. *Head Neck.* 2020 Jun;42(6):1259-1267.. Procedures undertaken in these anatomical areas on patients who carry the virus may cause aerosolisation of the virus thereby posing a relative risk of transmission to the clinical team.

Studies focusing on bipolar cautery during tonsil surgery have demonstrated not only aerosolisation of particles originating from the oral cavity but also deposition of blood droplets around the surgeon's eyes⁵⁵Carr MM, Patel VA, Soo JC, Friend S, Lee EG. Effect of Electrocautery Settings on Particulate Concentrations in Surgical Plume during Tonsillectomy. *Otolaryngol Head Neck Surg.* 2020 Jun;162(6):867-872.·66Keogh IJ, Hone SW, Colreavey M, Walsh M. Blood splash and tonsillectomy: an underestimated hazard to the otolaryngologist. *J Laryngol Otol.* 2001 Jun;115(6):455-6.. Coblation is a popular method because it purportedly causes less pain than other surgical methods⁷⁷Pynnonen M, Brinkmeier JV, Thorne MC, Chong LY, Burton MJ. Coblation versus other surgical techniques for tonsillectomy. *Cochrane Database Syst Rev.* 2017 Aug 22;8(8):CD004619.·88Daskalakis D, Tsetsos N, Karagergou S, Goudakos J, Markou K, Karkos P. Intracapsular coblation tonsillectomy versus extracapsular coblation tonsillectomy: a systematic review and a meta-analysis. *Eur Arch Otorhinolaryngol.* 2020 Jul 4. doi: 10.1007/s00405-020-06178-2. Online ahead of print.. However, in the light of the current pandemic it is unknown if Coblation tonsillectomy results in detectable droplet splatter on the surgeon. The aim of this study was to assess droplet splatter around the surgical field and surgeon during simulated tonsil surgery in order to better inform on mitigation strategies and evaluate choice of personal protective equipment.

Methods

Ethical considerations

This was an observational study on simulated surgery which did not involve patients, healthy volunteers or utilised patient-derived clinical data. Following review by the Director of Research at [removed for blind peer review], formal ethics committee approval was not required. The reporting guideline we used was the Strengthening the Reporting of Observational Studies in Epidemiology (STROBE) checklist for observational studies.

Experimental setup

A life-size, anatomically realistic model of the head (AirSim®. TruCorp® Co. Armagh, Northern Ireland, U.K) was used in this study (Figure 1a). All simulations of tonsil surgery were undertaken in the operating theatre suite at [removed for blind peer review]. The hospital is a recent construction (2015) incorporating modern airflow techniques in each of its operating theatres. The model was placed at the top edge of the operating table in an extended neck position, akin to the conventional way of doing a tonsillectomy in a patient, with an appropriately sized Boyle–Davis mouth-gag which was supported by Draffin rods (Figure 1a). Pillows were placed at the bottom of the model to simulate the chest and upper abdomen of a patient. The model and surgical setup was then covered by an impervious black square sheet.

Fresh strawberries cut in half and soaked overnight in nontoxic fluorescein dye (1mg in 25mL. Monument Tools, MAP UK (TA Tool Chimp) Ltd. Essex, U.K) was used to simulate tonsils (Figure 1b). The Coblation™ Procise™ EZ wand (Smith&Nephew Ltd. Hull, U.K) was used in default energy settings (Coblate = 7, coagulate = 3). Diluted fluorescein dye was also added to the irrigation bag; 1g dye diluted in 250mL irrigation fluid. (Figure 1c).

Tonsil surgery was undertaken by two trained members of the team ([removed for blind peer review]) who undertook five experiments each, wearing standard personal protective equipment (PPE).

Quantification of fluorescein droplets and reporting of data

Each surgeon undertook five simulated tonsil procedures. The Coblation wand was activated on the strawberries for five minutes (Figure 1d) before the surgical field and surgeon was assessed for fluorescein droplet deposition using an ultraviolet (UV) lamp. The presence of droplet was assessed in binary fashion: present or not present. The results were collated as frequency of droplet detection and illustrated as a heatmap; 0 = white, 1-2 = yellow, 3-4 = orange and 5 = red.

For the surgical field, a 10cm diameter circle was cut out of the epicentre of the black square sheet to allow access into the oropharynx. A 30cm line was drawn to each corner of the square to divide it into

four quadrants representing areas within the immediate surgical field. Another black square sheet measuring 42cm x 42cm was placed over the pillow (Figure 2a). The surgeon was assessed based on anatomical subsites (Figure 2b): hands, forearm, upper arm, chest, neck, face visor and the area under the visor (mask and upper face).

The surgical field was then cleaned and re-checked with the UV lamp. Remnant strawberries were carefully removed and replaced with fresh fluorescein-soaked pieces. The Coblation wand was cleaned and activated externally to ensure both irrigation and suction was functioning properly. The surgeon's PPE was also cleaned and where necessary, changed.

Results

Each surgeon completed five experiments, providing a total of 10 data sets for analysis. For both simulated surgeons, the distance between tip of nose (surgeon) and upper lip (model) was 35cm. Fluorescein droplets were detected in all four quadrants of the surgical field. The frequency of splatter was greatest in the upper and lower quadrants (Figure 3). The upper quadrant corresponded to the area nearest the surgeon.

There were detectable splatter droplets on the surgeon; most frequently occurring on the hands followed by the forearm (Figure 4). Droplets were also detected on the visor, neck and chest albeit less frequently. However, none were detected on the upper arms.

Discussion

Simulated tonsil surgery using Coblation technology results in detectable splatter around the surgical field and on the surgeon. The most common area in the surgical field to be contaminated were the quadrants anterior and posterior to the oral cavity. There was reduced frequency of splatter in both lateral quadrants (Figure 3). This is due to the position of the surgeon's hand within the surgical field which corroborates with the finding of splatter on both hands (Figure 4). Splatter was detected on the face visor but interestingly, was also found on the mask and around the eyes which were areas under the visor. The results of this study, and in the light of the current pandemic, emphasises the importance of appropriate PPE and strict donning and doffing practice.

We were unable to undertake the splatter assessments during real-life surgery due to the suspension of elective surgery throughout the spring and summer of 2020. We believe that our experiments on a life-like model simulated real surgery and provided a consistent and repeatable platform to undertake the experimental observations. The strawberries were saturated in fluorescein dye which was also added to the saline irrigation bag (Figure 1b,c) to facilitate detection of droplet splatter. While excepting that fresh strawberries were not a substitute for tonsils, it is frequently used to simulate tonsils at instructional courses. We decided not to use porcine or bovine soft tissue due to the health and safety issues of utilising the operating theatre suite in our institution.

It was an arbitrary decision to activate the Coblation wand for 5 minutes during each experiment. Appreciating that different surgical styles and practices exist, we felt that 5 minutes was an average duration required to complete a unilateral tonsillectomy and that the duration mimicked our clinical practice.

This is the first study to assess for droplet splatter contamination around the surgical field and on the surgeon after Coblation tonsillectomy. Previous studies, undertaken during actual surgery, have focused on either the monopolar or bipolar diathermy which clearly demonstrated splatter contamination on the surgeon's face^{1,2,3}. The latter diathermy resulted in greater splatter. These studies were published following concerns that transconjunctival exposure was a potential route of transmission for hepatitis viruses and the human immunodeficiency virus in health care workers. The consensus from these studies was for surgeons to wear goggles during tonsil surgery in order to mitigate the risk of transconjunctival contamination.

A recent study on monopolar tonsillectomy demonstrated greater spread of the surgical plume at higher energy settings¹¹O'Brien DC, Lee EG, Soo JC, Friend S, Callaham S, Carr MM. Surgical Team Exposure to Cautery Smoke and Its Mitigation during Tonsillectomy. *Otolaryngol Head Neck Surg.* 2020 Sep;163(3):508-

516.. The authors concluded that the addition of a suction catheter held by a surgical assistant reduced the detectable spread of the surgical plume. We did not alter the settings on the Coblation power console but elected to use the default settings which are recommended by the manufacturer and reflects our clinical practice. Furthermore, our experiments did not consider the introduction of an additional suction as we wanted to demonstrate the splatter patterns from Coblation tonsillectomy which is routinely undertaken without an assistant bearing in mind that the wand has a built-in suction port.

The results of our study demonstrate that a face visor is insufficient to prevent splatter on the surgeon's face. It must be assumed that if splatter droplets could be detected in our study, that there will be smaller droplets deposited on the surfaces which were undetectable or remain aerosolised. This study confirms that Coblation tonsil surgery is an AGP. Given that coronaviruses are approximately 0.125µm in size and are frequently carried in respiratory droplets, it is possible that surgical techniques regarded as aerosol generating may risk airborne transmission of SARS-CoV-2 during surgery. The small particle size of the virus and the extent airborne aerosols may travel has highlighted the need for specific PPE to protect against inhaled transmission.

This study cannot determine if N97 surgical masks and goggles are sufficient protection from the risk of viral transmission. Air-purifying respirators systems and hoods may seem to be the obvious choice, but it should be remembered that extended use of these PPE is uncomfortable and restricts communication between staff in the operating suite²²Verbeek JH, Rajamaki B, Ijaz S, Sauni R, Toomey E, Blackwood B, Tikka C, Ruotsalainen JH, Kilinc Balci FS. Personal protective equipment for preventing highly infectious diseases due to exposure to contaminated body fluids in healthcare staff. *Cochrane Database Syst Rev.* 2020 May 15;5:CD011621.**Succinct key points:**The Covid-19 pandemic has highlighted tonsillectomy as an aerosol generating procedure (AGP). This is the first study to assess for droplet splatter contamination around the surgical field and on the surgeon during Coblation tonsillectomy. Droplets were detected in all four quadrants of the surgical fields with the greatest in the upper (nearest to surgeon) and lower quadrants. Splatter droplets were most frequently occurring on the hands of the surgeon followed by the forearm, and less frequently on the visor, neck, and chest. Although wearing a face visor does not prevent splatter on the surgical mask or around the eyes, it should be considered when undertaking tonsil surgery as well as a properly fitted goggle.**Legend to tables and figures****Figure 1.** Experimental setup: (a) Head model with Boyle–Davis and Draffin rods in-situ. (b) Fluorescein-soaked strawberries used to mimic tonsils. (c) Fluorecein infused into saline irrigation bag and tubing connected to Coblation pump. (d) Close-up of simulated tonsil surgery using the Coblation Procise wand. Note the hole in the black sheet covering the model but providing access to the oropharynx.**Figure 2 .** a) Quadrants of surgical field b)Anatomical subsites of surgeon (Right and left hands, forearms and arms, chest, neck and face) including face shield**Figure 3 .** Frequency of detected droplet spread around the surgical field by individual (a and b) and average (c); 0 = white, 1-2 = yellow, 3-4 = orange and 5 = red.**Figure 4 .** Heatmap of anatomical areas of each surgeon (a and b) including face shield.. The need for better protection must be balanced between user comfort, ability to communicate effectively more complicated donning or doffing procedures, and ultimately compliance to PPE recommendations.

Conclusion

Coblation tonsillectomy is an aerosol-generating procedure. Droplet splatter can be detected in the immediate surgical field as well as on the surgeon. Although wearing a face visor does not prevent splatter on the surgical mask or around the eyes, it should be considered when undertaking tonsil surgery as well as a properly fitted goggle.

Conflict of interest: none

Financial support: none

Data availability statement: The data that support the findings of this study are available from the corresponding author upon reasonable request.

References

- [1] Keogh IJ, Hone SW, Colreavey M, Walsh M. Blood splash and tonsillectomy: an underestimated hazard to the otolaryngologist. *J Laryngol Otol.* 2001 Jun;115(6):455-6.
- [2] Hanna BC, Thompson P, Smyth C, Gallagher G. Blood splash from different diathermy instruments during tonsillectomy. *J Laryngol Otol.* 2006; 120(11): 927 – 31.
- [3] Lakhani R, Loh Y, Zhang TT, Kothari P. A prospective study of blood splatter in ENT. *Eur Arch Otorhinolaryngol.* 2015 Jul;272(7):1809-12.
- [4] Kowalski LP, Sanabria A, Ridge JA, Ng WT, de Bree R, Rinaldo A, Takes RP, Mäkitie AA, Carvalho AL, Bradford CR, Paleri V, Hartl DM, Vander Poorten V, Nixon IJ, Piazza C, Lacy PD, Rodrigo JP, Guntinas-Lichius O, Mendenhall WM, D'Cruz A, Lee AWM, Ferlito A. COVID-19 pandemic: Effects and evidence-based recommendations for otolaryngology and head and neck surgery practice. *Head Neck.* 2020 Jun;42(6):1259-1267.
- [5] Carr MM, Patel VA, Soo JC, Friend S, Lee EG. Effect of Electrocautery Settings on Particulate Concentrations in Surgical Plume during Tonsillectomy. *Otolaryngol Head Neck Surg.* 2020 Jun;162(6):867-872.
- [6] Keogh IJ, Hone SW, Colreavey M, Walsh M. Blood splash and tonsillectomy: an underestimated hazard to the otolaryngologist. *J Laryngol Otol.* 2001 Jun;115(6):455-6.
- [7] Pynnonen M, Brinkmeier JV, Thorne MC, Chong LY, Burton MJ. Coblation versus other surgical techniques for tonsillectomy. *Cochrane Database Syst Rev.* 2017 Aug 22;8(8):CD004619.
- [8] Daskalakis D, Tsetsos N, Karagergou S, Goudakos J, Markou K, Karkos P. Intracapsular coblation tonsillectomy versus extracapsular coblation tonsillectomy: a systematic review and a meta-analysis. *Eur Arch Otorhinolaryngol.* 2020 Jul 4. doi: 10.1007/s00405-020-06178-2. Online ahead of print.
- [9] O'Brien DC, Lee EG, Soo JC, Friend S, Callahan S, Carr MM. Surgical Team Exposure to Cautery Smoke and Its Mitigation during Tonsillectomy. *Otolaryngol Head Neck Surg.* 2020 Sep;163(3):508-516.
- [10] Verbeek JH, Rajamaki B, Ijaz S, Sauni R, Toomey E, Blackwood B, Tikka C, Ruotsalainen JH, Kilinc Balci FS. Personal protective equipment for preventing highly infectious diseases due to exposure to contaminated body fluids in healthcare staff. *Cochrane Database Syst Rev.* 2020 May 15;5:CD011621.

Succinct key points:

1. The Covid-19 pandemic has highlighted tonsillectomy as an aerosol generating procedure (AGP).
2. This is the first study to assess for droplet splatter contamination around the surgical field and on the surgeon during Coblation tonsillectomy.
3. Droplets were detected in all four quadrants of the surgical fields with the greatest in the upper (nearest to surgeon) and lower quadrants.
4. Splatter droplets were most frequently occurring on the hands of the surgeon followed by the forearm, and less frequently on the visor, neck, and chest.
5. Although wearing a face visor does not prevent splatter on the surgical mask or around the eyes, it should be considered when undertaking tonsil surgery as well as a properly fitted goggle.


Legend to tables and figures

Figure 1. Experimental setup: (a) Head model with Boyle–Davis and Draffin rods in-situ. (b) Fluorescein-soaked strawberries used to mimic tonsils. (c) Fluorecein infused into saline irrigation bag and tubing connected to Coblation pump. (d) Close-up of simulated tonsil surgery using the Coblation Procise wand. Note the hole in the black sheet covering the model but providing access to the oropharynx.

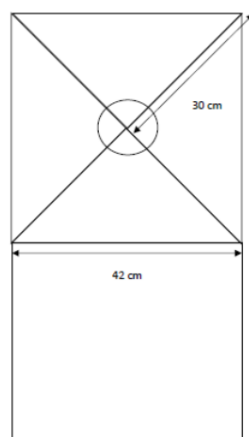
Figure 2. a) Quadrants of surgical field b) Anatomical subsites of surgeon (Right and left hands, forearms and arms, chest, neck and face) including face shield

Figure 3. Frequency of detected droplet spread around the surgical field by individual (a and b) and average (c); 0 = white, 1-2 = yellow, 3-4 = orange and 5 = red.

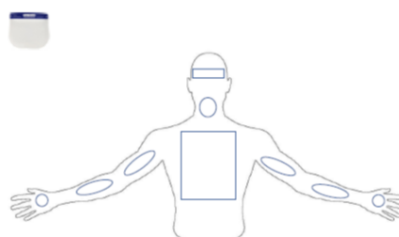
Figure 4. Heatmap of anatomical areas of each surgeon (a and b) including face shield.

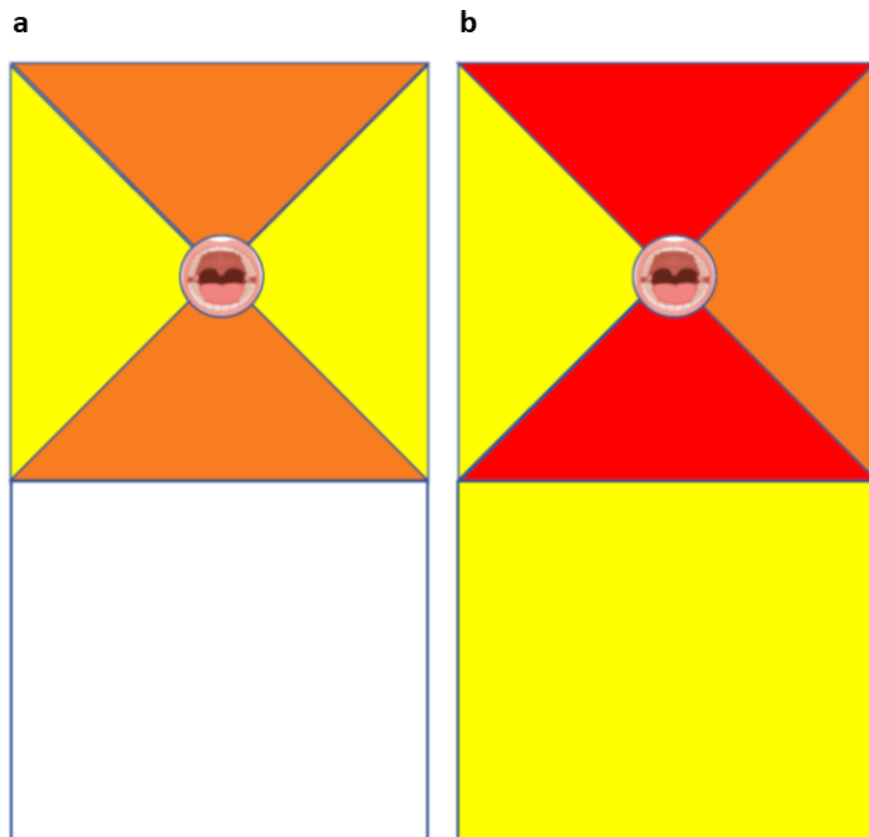


a

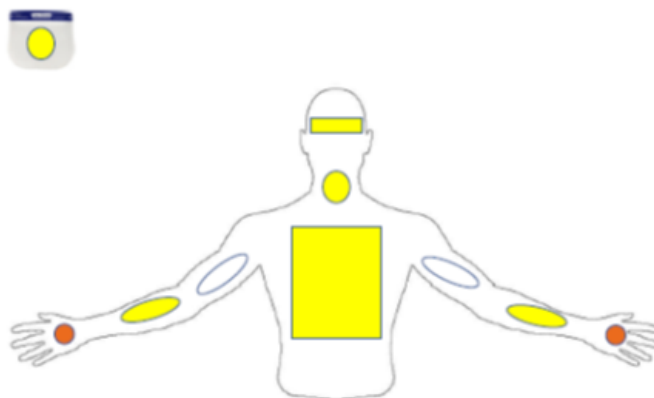


b





a



b

