

Surgical management of a giant atrial septal aneurysm

Motoyuki Kumagai¹, Junichiro Nishizawa², Makoto Takehara², Eiji Shinoda², and Kenji Minatoya¹

¹Kyoto University Graduate School of Medicine Department of Cardiovascular Surgery

²Hamamatsu Rosai Hospital

September 16, 2020

Abstract

A 63-year-old woman was diagnosed with a giant atrial septal aneurysm (ASA) protruding into the right atrium and thrombus attached to the left side of the ASA pouch. We surgically resected the ASA, and the resection site was closed with pericardial patch. The postoperative course was uneventful.

Introduction

Technological improvements in transthoracic echocardiography and the widespread application of transesophageal echocardiography have simplified the identification of atrial septal aneurysms (ASA) and the reported prevalence of ASA is now 2% – 10%.¹ Although ASA have recently become more common, they rarely require surgical resection. We describe surgical management of a giant atrial aneurysm in a patient with a patent foramen ovale (PFO).

Case report

A 63-year-old woman presented with chest discomfort. Coronary angiography revealed vasospastic angina, and transthoracic echocardiography (TTE) showed a giant ASA without a PFO, interatrial shunt or mitral valve prolapse. Cardiac multidetector computed tomography and cardiac magnetic resonance imaging showed that the giant ASA protruded about 30 mm into the right atrium and that a thrombus was attached to the left side of the ASA pouch (Fig. 1A and B). The patient was started on nicorandil, aspirin and anticoagulation therapy. Electrocardiographic monitoring detected occasional paroxysmal atrial tachycardia. We recommended surgical resection of the ASA because the patient was at risk for systemic thrombosis, so following procedure was performed. The ASA was surgically repaired via a median sternotomy under a cardiopulmonary bypass. The ASA visualized through a right atriotomy, protruded into the right atrium (Fig. 2A). A PFO was also evident next to the ASA (Fig. 2B). The aneurysm was excised, and the defect was closed with a pericardial patch using 4-0 polypropylene sutures. No thrombus remained attached to the surface of the resected ASA. The postoperative course was uneventful, and postoperative TEE did not detect a shunt, so the patient was discharged on postoperative day 26 with normal sinus rhythm. Macroscopic assessment of the ASA showed a mixture of normal and very thin tissues that seemed vulnerable to imminent tearing (Fig. 3A). Pathological assessment of the resected ASA showed that the thick tissues comprised a mixture of infiltrative fatty cells and fibrosis (Fig. 3B and C). The patient is under followup as an outpatient and remains free of complications at ten months postoperatively.

Comment

Atrial septal aneurysms are rare, but the range of their prevalence is due to variations in ASA diagnostic criteria, materials, methods, diagnostic equipment, study populations and recognition by echographers.¹ These aneurysms are often associated with other cardiac anomalies such as an intraarterial shunt, atrial

septal defect type II, PFO, valvular prolapse, etc.²Complications of ASA include cerebrovascular events, arrhythmia and pulmonary hypertension. Even among these, candidates for surgical repair of ASA and reports about the surgery of ASA are very rare. Stroke is one of the worst complications of ASA. Mattioli et al. reported that ASA is the only potential cardiac source of embolism detected by transesophageal echocardiography in patients aged < 45 years.³ Cabanes et al. reported that PFO and ASA are significantly associated with stroke in adults aged < 55 years.⁴ On the other hand, Shinohara et al. described a thrombus attached to the left side of an atrial septal aneurysm that disappeared under anticoagulation therapy, but the aneurysm was eventually excised and repaired with an atrial patch because of risk of recurrent thrombus and a need for lifelong anticoagulation therapy.⁵ The thrombus that was attached to the left side of the ASA pouch in our patient disappeared with anticoagulation therapy. However, we identified a PFO next to the ASA during surgery. Because our patient was at risk for cardiogenic embolism with intraatrial thrombi and PFO, we decided on surgical management of the ASA. Interatrial shunts are similar complications of ASA, and their prevalence is 54.4% – 77%. One risk of cardiogenic embolism with ASA is the intraatrial shunt.^{2,6} Although holes were not found in the atrial septal wall of our patient, pathological and macroscopic findings showed that parts of wall were so thin that rupture seemed imminent. The cause of the interatrial shunt in our patient remains obscure, but it might have been due rupture of the weakened atrial septal wall due to long-term bulging and stretching. Atrial tachyarrhythmias are also complications of ASA, with a prevalence of 18% – 25%.^{1,2,7} The cause of arrhythmias in patients with ASA is not clear, but cardiac abnormalities might be responsible, such as hypertension, atrial enlargement, systolic dysfunction, or valvular prolapse.¹ Although atrial tachyarrhythmias in patients with ASA are not a risk for cardiac embolism per se, ASA does confer thromboembolic potential, and long-term anticoagulant therapy is indicated for patients with ASA and a history of embolic events.^{2,6}The incidence of mitral valve prolapse associated with ASA is 12% – 20.5%,^{1,2,7,8} and the cause is also unclear. Mitral valve prolapse and ASA might have a similar pathological basis, namely, a connective disorder involving fibrous cardiac tissue¹. The connective tissue of an ostium primum atrial septal defect can become defective, especially when patients have myxomatous degeneration of the mitral valve. As a result, a weakened atrial septum might lead to outpouching of the atrial septal wall⁴. Taking into consideration these factors, echocardiography did not reveal mitral valve prolapse or regurgitation in our patient, but our patient has a potential risk of a mitral valve prolapse.

CONFLICTS OF INTEREST

None declared

AUTHOR CONTRIBUTIONS

MK: treated the patient, captured the images, co-conducted the literature review, and co-wrote the paper. NJ: treated the patient and corrected the paper. MK: treated the patient. ES: analyzed the case, co-wrote the paper. KM: analyzed the case, co-wrote the paper.

References

1. Olivares-Reyes A, Chan S, et al. Atrial septal aneurysm: a new classification in two hundred five adults. *J Am Soc Echocardiogr* 1997;10:644-656.
2. Mügge A, Daniel WG, Angermann C, et al. Atrial septal aneurysm in adult patients. A multicenter study using transthoracic and transesophageal echocardiography. *Circulation* 1995;91:2785-2792
3. Mattioli AV, Aquilina M, Oldani A, et al. Atrial septal aneurysm as a cardioembolic source in adult patients with stroke and normal carotid arteries. A multicentre study. *Eur Heart J* 2001;22: 261-268.
4. Cabanes L, Mas JL, Cohen A, et al. Atrial septal aneurysm and patent foramen ovale as risk factors for cryptogenic stroke in patients less than 55 years of age. A study using transesophageal echocardiography. *Stroke* 1993;24:1865-1873.
5. Shinohara T, Kimura T, Yoshizu H, et al. Three-year follow-up of an atrial septal aneurysm. *Ann Thorac Surg* 2001;71:1672-1673.

6. Hanley PC, Tajik AJ, Hynes JK, et al. Diagnosis and classification of atrial septal aneurysm by two-dimensional echocardiography: report of 80 consecutive cases. *J Am Coll Cardiol* 1985;6:1370-1382.
7. Schneider B, Hanrath P, Vogel P, Meinertz T. Improved morphologic characterization of atrial septal aneurysm by transesophageal echocardiography: relation to cerebrovascular events. *J Am Coll Cardiol* 1990;16:1000-1009.
8. Abinader EG, Rokey R, Goldhammer E, et al. Prevalence of atrial septal aneurysm in patients with mitral valve prolapse. *Am J Cardiol* 1988;62:1139-1140.
- 9.

Figure legends

Figure 1. Preoperative imaging of arterial septal aneurysm.

Multi-slice computed tomography shows giant ASA is protruding into right atrium and thrombus attached to left side of ASA pouch (A). Transthoracic echocardiography shows ASA attached to right atrial free wall and protruding into right atrium (B). ASA, atrial sepal aneurysm; LA, left atrium; LV, left ventricle; RA, right atrium; RV, right ventricle.

Figure 2. Intraoperative imaging findings.

Giant atrial sepal aneurysm protrudes into right atrium (A). Patent foramen ovale (B). ASA, atrial sepal aneurysm; RA, right atrium

Figure 3. Pathological findings of atrial sepal aneurysm (ASA).

Bloodstained gauze was placed inside giant ASA to understand nature of thin tissue. Mixture of thickened and very thin tissues that seemed vulnerable to imminent tears (A). Histological section of thin ASA tissues (B). Histological section of normal ASA tissues mixed with fatty cell infiltration and fibrosis (C). Hematoxylin and eosin staining. Magnification, $\times 100$. ASA, atrial sepal aneurysm.

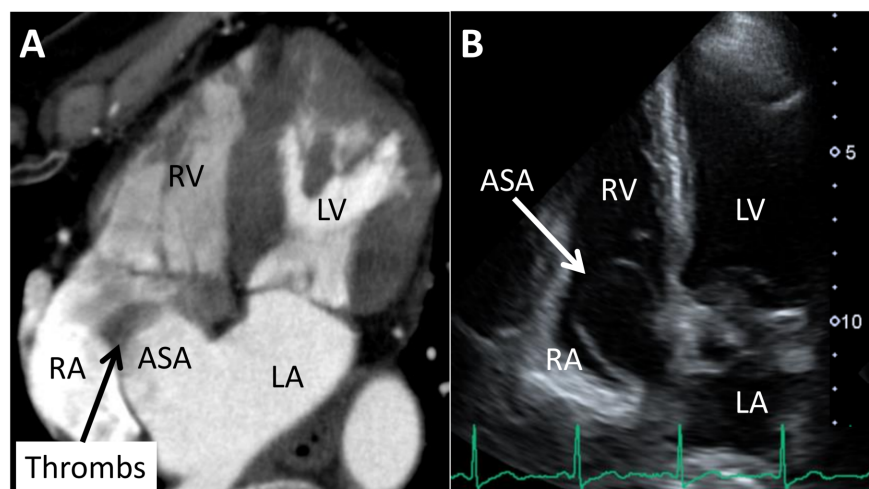


Fig 1.

Hosted file

Figure-__ASA.pdf available at <https://authorea.com/users/319113/articles/481425-surgical-management-of-a-giant-atrial-septal-aneurysm>