

Surgical Ablation Supplemented by Ethanol Injection for Ventricular Tachycardia Refractory to Percutaneous ablation

Gang Yang¹, Yongfeng Shao², Weidong Gu², Buqing Ni², Bing YANG³, Fengxiang Zhang¹, Weizhu Ju⁴, Hongwu CHEN⁵, Kai Gu⁶, Mingfang Li⁷, yu CHEN¹, Haoliang Sun¹, tam_tsz_kin⁸, Yanhu Wu¹, and Minglong Chen⁶

¹the First Affiliated Hospital of Nanjing Medical University

²The First Affiliated Hospital of Nanjing Medical University

³Shanghai East Hospital

⁴ the First Affiliated Hospital of Nanjing Medical University

⁵ the First Affiliated Hospital of Nanjing Medical University, Nanjing

⁶Institution of Clinical cardiovascular center

⁷the First Affiliated Hospital of Nanjing Medical Universit

⁸Division of Cardiology, Prince of Wales Hospital

November 26, 2020

Abstract

Background: Combination of endocardial and epicardial approach has improved the overall success rate of ventricular tachycardia (VT) ablation in patients with cardiomyopathy. However, the origins of some VTs are truly intramural or close to coronary arteries, which make this combined strategy either prone to failure or too risky. Objectives: This observational study aimed to explore the feasibility and efficacy of direct epicardial ablation combined with intramural ethanol injection via surgical approach for such VTs. Methods: Six consecutive patients with recurrent sustained VT refractory to combined endocardial and epicardial radiofrequency ablation were included. Direct epicardial access was achieved through limited left thoracotomy in 3 patients and median sternotomy in other 3 patients. Ablation was performed using irrigation catheter guided by electroanatomic mapping. Ethanol was injected in all patients to reinforce transmural lesions. The primary outcome was freedom of sustained VT determined by device interrogation and periodical 24h-holter recordings subsequently. Results: Over a median follow-up of 22 months (range, 6~65), all patients remained free of sustained VT. One patient died of pulmonary infection one year after the procedure. Conclusions: A hybrid strategy of surgical ablation combined with intramural ethanol injection is feasible and effective in patients with multiple failed percutaneous ablation attempts.

Surgical Ablation Supplemented by Ethanol Injection for Ventricular Tachycardia Refractory to Percutaneous ablation

Short title: Combined surgical and chemical VT ablation

Gang Yang, MD^{1*}; Yongfeng Shao, MD^{2*}; Weidong Gu, MD²; Buqing Ni, MD²; Bing Yang³, MD¹; Fengxiang Zhang, MD¹; Weizhu Ju, MD¹; Hongwu Chen, MD¹; Kai Gu, MD¹; Mingfang Li, MD¹; Yu Chen, MD⁴; Haoliang Sun, MD²; Tsz Kin Tam, MBChB⁴; Yanhu Wu, MD²; Minglong Chen, MD¹

1 Division of Cardiology, the First Affiliated Hospital of Nanjing Medical University, Nanjing, 210029, China

2 Division of Cardiac Surgery, the First Affiliated Hospital of Nanjing Medical University, Nanjing, 210029, China

3 Department of Cardiology, Shanghai East Hospital, Shanghai, 200123, China

4 Division of Anesthesiology, the First Affiliated Hospital of Nanjing Medical University, Nanjing, 210029, China

4 Division of Cardiology, Prince of Wales Hospital, Chinese University of Hong Kong, Hong Kong, China

*Both authors contributed to this work equally.

Word Count: 5016

Disclosures:

All authors have completed and submitted the ICMJE forms for Disclosure of Potential Conflicts of Interest. Dr. Chen reports receiving lecture fee from Biosense Webster, St. Jude Medical, Medtronic, Bayer and Boehringer Ingelheim. No other disclosures were reported.

Address for correspondence :

Minglong Chen, MD, Division of Cardiology, The First Affiliated Hospital of Nanjing Medical University, Nanjing 210029, China.

Tel: 0086-25-68303115

Fax: 0086-25-6813-6479

E-mail: chenminglong@njmu.edu.cn

ABSTRACT

Background: Combination of endocardial and epicardial approach has improved the overall success rate of ventricular tachycardia (VT) ablation in patients with cardiomyopathy. However, the origins of some VTs are truly intramural or close to coronary arteries, which make this combined strategy either prone to failure or too risky.

Objectives : This observational study aimed to explore the feasibility and efficacy of direct epicardial ablation combined with intramural ethanol injection via surgical approach for such VTs.

Methods: Six consecutive patients with recurrent sustained VT refractory to combined endocardial and epicardial radiofrequency ablation were included. Direct epicardial access was achieved through limited left thoracotomy in 3 patients and median sternotomy in other 3 patients. Ablation was performed using irrigation catheter guided by electroanatomic mapping. Ethanol was injected in all patients to reinforce transmural lesions. The primary outcome was freedom of sustained VT determined by device interrogation and periodical 24h-holter recordings subsequently.

Results: Over a median follow-up of 22 months (range, 6~65), all patients remained free of sustained VT. One patient died of pulmonary infection one year after the procedure.

Conclusions: A hybrid strategy of surgical ablation combined with intramural ethanol injection is feasible and effective in patients with multiple failed percutaneous ablation attempts.

KEY WORDS: ventricular tachycardia, epicardial ablation, ethanol injection, chemical ablation

ABBREVIATIONS:

AAD = antiarrhythmic drugs

CRT-D = cardiac resynchronization therapy with defibrillator

DCM = dilated cardiomyopathy

ICD = implantable cardioverter defibrillator

LVZ = low voltage zone

NICM = non-ischemic cardiomyopathy

VT = ventricular tachycardia

INTRODUCTION

Catheter ablation is an effective therapy for ventricular tachycardia (VT) in patients with structural heart disease. Endocardial ablation was often supplemented by epicardial ablation in 15-30% of patients to achieve success.(1-3) Percutaneous epicardial mapping and ablation was first attempted by Sosa and his colleagues.(4) Since then, this technique has been widely used in patients with non-ischemic cardiomyopathy (NICM), arrhythmogenic right ventricular cardiomyopathy (ARVC) and some focal VTs originating epicardially.(5-7) Unfortunately, some VTs are still refractory to combined endocardial and epicardial ablation. These challenging VTs often progress to electrical storm causing frequent implantable cardioverter defibrillator (ICD) shocks and significantly increase the mortality. (8-9) The intramural or subepicardial VT substrate may cause the ablation failure. Percutaneous epicardial ablation frequently was limited by poor contact force or fat tissue. Some non-conventional ablation strategies for intramural ventricular arrhythmias have been reported recently including bipolar ablation, needle ablation, half-normal saline irrigated ablation. (10-12) However, these techniques required specific devices or equipment which have not been available in most of centers. Transvessel ethanol ablation has also been reported as an effective alternative strategy for VTs with previously failed radiofrequency ablation.(13, 14) However, its success was limited by the anatomy of coronary branches. Surgical epicardial ablation has been reported as a feasible alternative strategy for VTs.(15-17) Meanwhile, intramyocardial ethanol injection has been proved effectively in animal models. (18) There have been no reports on effects of intramyocardial ethanol injection for the treatment of VTs in human. We hypothesized that surgical catheter ablation supplemented by direct ethanol injection might be a powerful treatment in those challenging VTs, especially when concomitant surgical interventions were needed.

METHODS

Study Population

From 2014 to 2019, VT patients with structural heart disease who were resistant to combined endocardial and epicardial ablation in our center were included. These VTs either presented as electrical storms or could not be controlled by antiarrhythmic drugs. All procedures were performed after written informed consent. The study was approved by the institutional review board.

Electrophysiological Study and Endocardial Ablation Procedure

All patients underwent a transthoracic echocardiography study to evaluate left ventricular ejection fraction (LVEF) and to look for potential ventricular aneurysm or intracardiac thrombi. The electrophysiological study was performed under general anesthesia. Intracardiac electrograms were recorded using a digital electrophysiological recording system (Prucka CardioLab, USA or EP-WorkMate St. Jude Medical, St. Paul, MN, USA). Three-dimensional electroanatomic mapping was guided by an EnSite NavX system (St. Jude Inc., St. Paul, MN, USA) or CARTO 3 system (Biosense Webster, Diamond Bar, CA, USA).

If the patient was in sinus rhythm (SR), an endocardial voltage map during SR was acquired using an ablation catheter (ThermoCool NaviStar, Biosense Webster, CA, USA or CoolFlex, St. Jude Inc., St. Paul, MN, USA). Low voltage zones (LVZ) were defined as amplitude between 0.5 and 1.5 mV. Late potentials and/or local fragmented ventricular potentials were also tagged. After voltage mapping, VT induction was attempted with programmed stimulation. For hemodynamically well tolerated VTs, local activation mapping was performed. In cases that were non-inducible or with hemodynamically poorly tolerated VTs, substrate modification was performed during SR. Low voltage areas, fragmented or late potentials and areas with matching pace-maps were targeted. Radiofrequency (RF) ablation was performed with a power of 30-45 W at a temperature limit of 45 °C. The acute procedural endpoint was defined as non-inducibility of VTs.

Epicardial Ablation Procedure

When endocardial VT ablation was unsuccessful, epicardial approach would be attempted using subxiphoid access. Mapping and ablation strategies were similar to the endocardial approach as described above. Coronary angiogram was performed in all the patients before ablation to avoid inadvertent damage of coronary artery. High output pacing was performed in the area close to the course of phrenic nerve before ablation to avoid phrenic nerve injury.

Surgical VT Ablation

When VT ablation was failed despite endo/epi ablation, eligible patients would be rescheduled for surgical VT ablation. A quadripolar catheter was advanced into right ventricle for mapping reference and VT induction. Left limited thoracotomy would be the preferred access for surgical VT ablation. If the patient required other concomitant cardiac surgery, a median sternotomy would be performed instead. Three-dimensional electroanatomic mapping system (EnSite NavX, St. Jude Inc., St. Paul, MN, USA) was used to guide the procedure. The mapping strategy was similar to that of endocardial and epicardial approach. An irrigated ablation catheter (CoolFlex, St. Jude, Inc., St. Paul, MN, USA) with a flow rate of 30-60mL/min was used. Since the impedance recorded by the catheter tip was often higher than 200 Ω due to its exposure to air, the upper limit of impedance should be reset to the maximum allowed by the RF generator. The tip of ablation catheter was manually pressed against the epicardial surface to maximize the contact force.

Intramural Ethanol Injection under Direct Vision

When direct epicardial ablation failed to eliminate VTs or VT could not be induced at baseline, ethanol injection would be attempted. The borders of the RF lesion sets were selected as sites for injection. 4-5 injections were delivered at each area at the dosage of 0.3 to 0.5 ml per injection. To avoid inadvertent entering into the left ventricular (LV), the needle was guarded by plastic tubes to limit the injection depth to be less than 5mm (Figure 1). Before injection, a gentle negative suction was performed to ensure no blood could be drawn.

Clinical Follow-up

During the first year after procedure, all patients were followed up with clinic visits, 24h Holter recordings, and device interrogation if available at 1, 3, 6 and 12 months. In subsequent years, same assessments would be done every 6 months. If no VT recurrence were observed, antiarrhythmic medication except beta blockers would be discontinued. LVEF was evaluated by transthoracic echocardiography annually.

Ethanol Injection in Animal Experiments to study acute and delayed effect

Intramyocardial ethanol injection was tested in four dogs in order to figure out the morphology and histology of the acute lesions and to verify the relationship between the injection dosage and the lesion size. After general anesthesia, the heart was exposed by left thoracotomy. Boluses of ethanol were injected at LV anterior wall at a dose of 0.2 ml, 0.3 ml and 0.5 ml for each dog. Two dogs were sacrificed after 15 minutes after finishing the injections to study the acute effect. The other two dogs would be sacrificed after 6 weeks to study the delayed effect. Morphologic and histopathological examinations were performed for each specimen. The animal study was approved by the animal ethic committee of Nanjing Medical University.

Statistical Analysis

Continuous variables were summarized using descriptive statistics (mean, standard deviation, median, and range). The results are expressed in terms of p values. All statistical analyses were performed using SPSS software version 19.0.

RESULTS

Patient Characteristics

178 patients with non-ischemic cardiomyopathy who underwent VT ablation in our center from 2014 to 2019. Surgical access was finally used in 12 patients. Six patients were enrolled in present study who underwent direct epicardial ablation plus intramural ethanol injection via surgical approach. Baseline characteristics were listed in Table 1. All patients were refractory to at least 1 antiarrhythmic drug (AAD). 4 of 6 (67%) patients had previous ICD implantation. All of them experienced VT storm and multiple ICD shocks before surgical treatment.

Previous Endocardial and Epicardial Ablation

All 6 patients had a total of 14 clinical or induced VTs (Figure 2). When VT endocardial ablation failed, epicardial mapping and ablation followed. Finally, the remaining 12 VTs of these 6 patients, which were refractory to catheter epicardial ablation, received surgical intervention.

Surgical VT Ablation

The procedural flowchart and the follow-up results of all 6 patients were summarized in Figure 3. And the 12-lead electrocardiograms of VTs were displayed in Figure 4. Among the 6 patients, three were accessed with limited left thoracotomy and other three with median sternotomy. Notably, previous epicardial RF lesions could hardly be visualized on the cardiac surface in patients with history of epicardial ablation. Voltage mapping, VT induction and activation mapping were performed sequentially before ablation. Clinical VTs could be induced in all patients at baseline in the procedure. With support from anesthesiologists, VTs were hemodynamically tolerated in all patients to allow activation mapping. All the VT locations were shown in Table 2. VTs could be terminated during ablation but easily reinduced in all patients. LVZs and late potentials or fragmented electrograms were targeted and ablated if found (Supplementary Figure 1). After surgical ablation, all the RF lesions were visible.

Intramyocardial Ethanol Injection

When VT was reinduced after surgical ablation, ethanol injection would be attempted (Figure 3). The sites of injection were around the RF lesions (Table 2). A mean of 2.3 ± 0.6 ml ethanol was injected for each patient. During injection, accelerated idioventricular rhythm or non-sustained VTs were noticed in 2 patients (Pt-1 and -5), which might be an acute reaction of the myocardium to alcohol. Interestingly, VT could be reinduced again after surgical RF ablation and ethanol injection. After activation mapping, the earliest site was localized close to the left circumflex coronary artery (<1 cm). Surgical ablation was not considered and local epicardial fat tissue was removed. With one dosage of 0.3 ml ethanol injection in this specific site, VT was terminated immediately (Figure 5). In addition to surgical RF ablation and ethanol injection, concomitant surgical procedures were performed in 3 patients (Figure 3).

Clinical Outcomes

Over a median follow-up of 22 months (range, 6 to 65), all 6 patients remained free of sustained VT (Figure 3). Pt-2 was free from VT but died of severe pneumonia 2 years after the procedure. LVEF did not seem to be impacted by the procedure (Table 1).

Macroscopic and Histopathological Examination in Animal Studies

With increasing the dosage of ethanol (0.2, 0.3, 0.5 ml), the lesion size also increased (Figure 6A, Supplementary Table 1). Histology examination revealed both acute and chronic homogenized necrosis of the myocardium. Acute histology examination demonstrated a cloudy swelling of muscle with the disappearance of some of the nuclei, and the cross-striation of myofibrils was decreased (Figure 6B). The chronic lesion showed homogeneous fibrosis with clear but irregular border (Figure 6C).

DISCUSSION

Catheter ablation is a very effective and demanding technique in the treatment for cardiomyopathy patients with VT storms, especially those with frequent ICD shocks. However, those who were failed by combined endocardial and epicardial ablation are a unique population with very high mortality. Searching for solutions

to control VTs in such tough patients is rather important. We report our experience of direct RF ablation with intramyocardial ethanol injection via surgical approach to treat the patients with recurrent VT despite multiple endocardial and/or epicardial ablations. The key findings of this study are as follows: (1) in some patients with non-ischemic cardiomyopathy, VTs were of true intramural origin which explain their refractory property to both endocardial and epicardial ablation (Supplementary Figure 2); (2) surgical RF ablation allowed manual pressure of the catheter against the epicardium, yielding more effective lesions than percutaneous epicardial ablation; (3) intramural ethanol injection produced homogenized tissue necrosis and was a safe and effective strategy for VT elimination.

Surgical VT Ablation Techniques

With improvements in catheter-based ablation technology, the outcomes of percutaneous VT ablation have also been improved. However, inadequate contact force, epicardial fat tissue, substrate close to the coronary arteries and intramural foci limited the success with percutaneous ablation. The other important issue was pericardial adhesion. Soejima et al described a series of 6 patients with pericardial adhesion, for which a hybrid subxiphoid surgical window approach to treat VT in electrophysiology (EP) lab was adopted.(16) However, the subxiphoid approach allowed inadequate access to anterior and lateral regions. Michowitz then used limited anterior thoracotomy in patients with previous cardiac surgery and pericardial adhesion in EP lab.(17) This approach could permit access to the whole anterior and lateral wall as well as the apex. Anter et al reported their surgical cryoablation experience in 8 non-ischemic cardiomyopathy patients with refractory VT.(15) Two patients died of heart failure and sepsis eventually, while the other 6 patients had significant reduction in VT burden. All these studies emphasized that direct epicardial ablation via limited thoracotomy or even open chest approach could be effective in difficult VT cases.

Compared with percutaneous access, surgical RF ablation has the following advantages: (1) contact force is ensured by pressing the catheter tip against epicardium, which makes deeper lesions (Figure 1); (2) under direct vision, the substrates in close proximity to the coronary arteries could be ablated safely and adequately;(3) other concomitant surgical procedures could be done simultaneously; (4) in patients with CRT indication, the LV lead can be placed at a more electrophysiological site (high voltage, latest activation, away from scar) guided by 3-D electroanatomic mapping system. However, the limitation of this traumatic approach is apparent. This approach can only be served as the last resort for patients with frequent VT attack and refractory to both antiarrhythmic drugs and conventional ablation therapy, especially those with frequent ICD shocks.

Ethanol Injection for the Treatment of VT

Trans-coronary arterial injection has been established as a potentially useful therapeutic alternative in VTs that fail to respond to RF (18-21). However, the limitations of this technique include inadvertent coronary artery damage, lacking of a suitable branch to deliver the ethanol and non-homogenized tissue injury paradoxically producing new VT substrate. Therefore, some other investigators tried to use venous route for ethanol delivery. Wright et al. explored the retrograde venous approach in a canine model showing the feasibility and efficacy.(22) Kreidieh et al. used retrograde coronary venous ethanol ablation as a bail-out approach to failed VT ablation, particularly from left ventricular summit.(23) Meanwhile, transcatheter intra-myocardial ethanol injection was tested in animal models.(24-28) However, so far this technique has not been reported in human beings and this special catheter has not been widely used clinically. In our study, we directly injected the ethanol to the myocardium to reinforce surgical ablation. As a supplementary treatment, it worked in association with surgical RF ablation and achieved the final success. To our knowledge, this is the first study describing the safety and efficacy of intramural ethanol injection via surgical approach in VT patients. In our animal study, epicardial ethanol injection created homogenous and well-circumscribed lesions which could be less arrhythmogenic. Meanwhile, the impact of small dosage of ethanol injection on cardiac function is still not significant in the long-term follow up. Therefore, the efficacy of ethanol injection at the critical VT sites is promising. This novel technique can be used to supplement surgical epicardial RF ablation.

Other Alternative Treatments for Challenging VTs

The sympathetic nervous system plays an important role in the genesis of ventricular arrhythmias. Cardiac sympathetic denervation (CSD) has been emerged as an important adjunctive therapy in the management of patients with treatment resistant VTs. CSD could reduce VT burden and decrease ICD shocks in patients with refractory VT.(29) However, CSD was performed more often in patients with channelopathy such as long QT syndrome and catecholaminergic polymorphic VT, data on CSD in structural heart disease is still limited, and the post-operation complications are still relatively high.(30)

More recently, Phillip S. and his colleagues reported that their novel noninvasive electrophysiology-guided radioablation could reduce the burden of VT and ICD shocks dramatically in 5 patients with refractory VTs.(31) However, this noninvasive treatment workflow is very complex, and a specific electrocardiographic mapping system is needed. Furthermore, this radiotherapy equipment has not been launched in market.

Study Limitations

The number of this cases series is small. Whether the procedural and long-term outcomes can be reproducible in a larger patient population is unknown.

The biophysics of radiofrequency lesion is different in healthy myocardium from that of the scarred myocardium. If the animal model with scarred myocardial tissue was created first and the techniques used in our study were then applied afterwards, the results would be more scientific and accurate. Meanwhile, lesion size by direct ethanol injection should be measured three dimensionally and the lesion geometry should be present in a full view in the animal study. However, only two dogs were assigned to test the acute lesion formation and the other two for chronic lesion pathology. Our main purpose of the animal study is to test the correlation between the lesion size and the ethanol dosage, and the homogenization property of the chronic lesion pathology. We would further the animal study as a single study project in the future.

CONCLUSIONS

A hybrid strategy of direct epicardial ablation supplemented by intramural ethanol injection via surgical approach is feasible and effective in VT patients who were refractory to multiple combined percutaneous catheter ablations. This might be a powerful treatment for challenging VTs, especially in those ICD patients with failed ablation percutaneously.

Acknowledgements: None.

Funding: This work was supported by the National Key R&D Program of China [2017YFC1307800].

Disclosure: All authors have completed and submitted the ICMJE forms for Disclosure of Potential Conflicts of Interest. Dr. Chen reports receiving lecture fee from Biosense Webster, St. Jude Medical, Medtronic, Bayer and Boehringer Ingelheim. No other disclosures were reported.

REFERENCES

1. Sacher F, Roberts-Thomson K, Maury P, Tedrow U, Nault I, Steven D, et al. Epicardial ventricular tachycardia ablation a multicenter safety study. *J Am Coll Cardiol*. 2010;55(21):2366-72.
2. Aliot EM, Stevenson WG, Almendral-Garrote JM, Bogun F, Calkins CH, Delacretaz E, et al. EHRA/HRS Expert Consensus on Catheter Ablation of Ventricular Arrhythmias: developed in a partnership with the European Heart Rhythm Association (EHRA), a Registered Branch of the European Society of Cardiology (ESC), and the Heart Rhythm Society (HRS); in collaboration with the American College of Cardiology (ACC) and the American Heart Association (AHA). *Heart Rhythm*. 2009;6(6):886-933.
3. Nakahara S, Tung R, Ramirez RJ, Michowitz Y, Vaseghi M, Buch E, et al. Characterization of the arrhythmogenic substrate in ischemic and nonischemic cardiomyopathy implications for catheter ablation of hemodynamically unstable ventricular tachycardia. *J Am Coll Cardiol*. 2010;55(21):2355-65.
4. Sosa E, Scanavacca M, d'Avila A, Pilleggi F. A new technique to perform epicardial mapping in the electrophysiology laboratory. *J Cardiovasc Electrophysiol*. 1996;7(6):531-6.

5. Soejima K, Stevenson WG, Sapp JL, Selwyn AP, Couper G, Epstein LM. Endocardial and epicardial radiofrequency ablation of ventricular tachycardia associated with dilated cardiomyopathy: the importance of low-voltage scars. *J Am Coll Cardiol*. 2004;43(10):1834-42.
6. Garcia FC, Bazan V, Zado ES, Ren JF, Marchlinski FE. Epicardial substrate and outcome with epicardial ablation of ventricular tachycardia in arrhythmogenic right ventricular cardiomyopathy/dysplasia. *Circulation*. 2009;120(5):366-75.
7. Daniels DV, Lu YY, Morton JB, Santucci PA, Akar JG, Green A, et al. Idiopathic epicardial left ventricular tachycardia originating remote from the sinus of Valsalva: electrophysiological characteristics, catheter ablation, and identification from the 12-lead electrocardiogram. *Circulation*. 2006;113(13):1659-66.
8. Dukkipati SR, d'Avila A, Soejima K, Bala R, Inada K, Singh S, et al. Long-term outcomes of combined epicardial and endocardial ablation of monomorphic ventricular tachycardia related to hypertrophic cardiomyopathy. *Circ Arrhythm Electrophysiol*. 2011;4(2):185-94.
9. Tung R, Vaseghi M, Frankel DS, Vergara P, Di Biase L, Nagashima K, et al. Freedom from recurrent ventricular tachycardia after catheter ablation is associated with improved survival in patients with structural heart disease: An International VT Ablation Center Collaborative Group study. *Heart Rhythm*. 2015;12(9):1997-2007.
10. Koruth JS, Dukkipati S, Miller MA, Neuzil P, d'Avila A, Reddy VY. Bipolar irrigated radiofrequency ablation: a therapeutic option for refractory intramural atrial and ventricular tachycardia circuits. *Heart Rhythm*. 2012;9:1932-41.
11. AbdelWahab A, Stevenson W, Thompson K, et al. Intramural Ventricular Recording and Pacing in Patients With Refractory Ventricular Tachycardia: Initial Findings and Feasibility With a Retractable Needle Catheter. *Circ Arrhythm Electrophysiol* 2015;8:1181-1188.
12. Nguyen DT, Gerstenfeld EP, Tzou WS, et al. Radiofrequency Ablation Using an Open Irrigated Electrode Cooled with Half-Normal Saline. *JACC Clin Electrophysiol* 2017;3:1103-1110.
13. Tokuda M, Sobieszczek P, Eisenhauer AC, Kojodjojo P, Inada K, Koplan BA, et al. Transcatheter ethanol ablation for recurrent ventricular tachycardia after failed catheter ablation: an update. *Circ Arrhythm Electrophysiol*. 2011;4(6):889-96.
14. Miller MA, Kini AS, Reddy VY, Dukkipati SR. Transcatheter ethanol ablation of ventricular tachycardia via an anomalous first septal perforating artery. *Heart Rhythm*. 2011;8(10):1606-7.
15. Anter E, Hutchinson MD, Deo R, Haqqani HM, Callans DJ, Gerstenfeld EP, et al. Surgical ablation of refractory ventricular tachycardia in patients with nonischemic cardiomyopathy. *Circ Arrhythm Electrophysiol*. 2011;4(4):494-500.
16. Soejima K, Couper G, Cooper JM, Sapp JL, Epstein LM, Stevenson WG. Subxiphoid surgical approach for epicardial catheter-based mapping and ablation in patients with prior cardiac surgery or difficult pericardial access. *Circulation*. 2004;110(10):1197-201.
17. Michowitz Y, Mathuria N, Tung R, Esmailian F, Kwon M, Nakahara S, et al. Hybrid procedures for epicardial catheter ablation of ventricular tachycardia: value of surgical access. *Heart Rhythm*. 2010;7(11):1635-43.
18. Chilson DA, Peigh PS, Mahomed Y, Waller BF, Zipes DP. Chemical ablation of ventricular tachycardia in the dog. *Am Heart J*. 1986;111(6):1113-8.
19. Brugada P, de Swart H, Smeets JL, Wellens HJ. Transcatheter chemical ablation of ventricular tachycardia. *Circulation*. 1989;79(3):475-82.
20. Kay GN, Epstein AE, Bubien RS, Anderson PG, Dailey SM, Plumb VJ. Intracoronary ethanol ablation for the treatment of recurrent sustained ventricular tachycardia. *J Am Coll Cardiol*. 1992;19(1):159-68.

21. Haines DE, Wayne JG, DiMarco JP. Intracoronary ethanol ablation in swine: effects of ethanol concentration on lesion formation and response to programmed ventricular stimulation. *J Cardiovasc Electrophysiol.* 1994;5(5):422-31.
22. Wright KN, Morley T, Bicknell J, Bishop SP, Walcott GP, Kay GN. Retrograde coronary venous infusion of ethanol for ablation of canine ventricular myocardium. *J Cardiovasc Electrophysiol.* 1998;9(9):976-84.
23. Kreidieh B, Rodriguez-Manero M, Schurmann P, Ibarra-Cortez SH, Dave AS, Valderrabano M. Retrograde Coronary Venous Ethanol Infusion for Ablation of Refractory Ventricular Tachycardia. *Circ Arrhythm Electrophysiol.* 2016;9(7).
24. Weismuller P, Mayer U, Richter P, Heieck F, Kochs M, Hombach V. Chemical ablation by subendocardial injection of ethanol via catheter—preliminary results in the pig heart. *Eur Heart J.* 1991;12(11):1234-9.
25. Goette A, Hartung W, Lesh M, Honeycutt C, Fleischman S, Swanson D, et al. Transcatheter subendocardial infusion. A novel technique for mapping and ablation of ventricular myocardium. *Circulation.* 1996;94(6):1449-55.
26. Callans DJ, Ren JF, Narula N, Patel V, Michele J, Gelzer A, et al. Left ventricular catheter ablation using direct, intramural ethanol injection in swine. *J Interv Card Electrophysiol.* 2002;6(3):225-31.
27. Rogers T, Mahapatra S, Kim S, Eckhaus MA, Schenke WH, Mazal JR, et al. Transcatheter Myocardial Needle Chemoablation During Real-Time Magnetic Resonance Imaging: A New Approach to Ablation Therapy for Rhythm Disorders. *Circ Arrhythm Electrophysiol.* 2016;9(4):e003926.
28. Reek S, Geller JC, Schildhaus HU, Mahnkopf D, Mittag J, Klein HU. Catheter ablation of ventricular tachycardia by intramyocardial injection of ethanol in an animal model of chronic myocardial infarction. *J Cardiovasc Electrophysiol.* 2004;15(3):332-41.
29. Vaseghi M, Barwad P, Malavassi Corrales FJ, Tandri H, Mathuria N, Shah R, et al. Cardiac Sympathetic Denervation for Refractory Ventricular Arrhythmias. *J Am Coll Cardiol.* 2017;69(25):3070-80.
30. Shah R, Assis F, Alugubelli N, Okada DR, Cardoso R, Shivkumar K, et al. Cardiac sympathetic denervation for refractory ventricular arrhythmias in patients with structural heart disease: A systematic review. *Heart Rhythm.* 2019;16(10):1499-505.
31. Cuculich PS, Schill MR, Kashani R, Mutic S, Lang A, Cooper D, et al. Noninvasive Cardiac Radiation for Ablation of Ventricular Tachycardia. *N Engl J Med.* 2017;377(24):2325-36.

Table 1 Patient Baseline Characteristics

Pt.	Age (year)	Gender	Etiology	Prior Angiogram	LVEF (%)	Device	AAD	Follow-up (Month)	LV
1	48	Male	DCM+CAD-LCX BiAV	50%	38	ICD	Amio	65	45
2	69	Male	DCM+CAD LAD	90%+PCI	35	CRT	Amio+BB	30	30
3	71	Male	DCM+CAD LCX	90%+PCI	55	DDD	Amio	29	56
4	55	Male	DCM+AR	Normal	42	ICD	Amio+BB	13	45
5	80	Male	DCM	No	55	ICD	Amio	12	50
6	56	Male	DCM	No	58	ICD	Amio+Nifekafant	16	55
Mean±SD	63±12	-	-	-	47±10	-	-	22	46

LVEF: left ventricular ejection fraction; LVEDD: left ventricular end diastolic diameter; AAD: antiarrhythmic drugs; DCM: dilated cardiomyopathy; CAD: coronary artery disease; Bi-AV : bi-aortic valve; LCX: left circumflex coronary artery; LAD: left anterior descending artery; PCI: percutaneous coronary intervention; BiAV: bicuspid aortic valve; AR: aortic regurgitation; MR: mitral regurgitation; Amio: amiodarone; BB: beta blocker. Endo: endocardial mapping and ablation; Epi: epicardial mapping and ablation. *: the difference of LVEF between the baseline and the follow up was nonsignificant. (P=0.954)

Table 2 Surgical Ablation and Ethanol Injection

Pt.	No. of VTs induced @Baseline	Location of target area	Targeted LVZ/LP&FP	VT inducibility @Post RFA
1	1	Anterior wall close to DA	+ / +	Yes
2	1	Anterior wall close to OM	- / +	Yes
3	2	Lateral wall close to LCX	+ / +	Yes
4	1	Anterior wall close to MA	- / -	Yes
5	1	Anterolateral wall	- / -	Yes
6	0	LV Summit	- / -	No

VT: ventricular tachycardia; LVZ: low voltage zone (<0.5mV); LP: late potential; FP: fragmented potential; MA: mitral annulus; LV: left ventricle; DA: diagonal artery; OM: obtuse marginal artery; LCX: left circumflex artery; PDA: posterior descending artery; AIVR: accelerated idioventricular rhythm.

FIGURES

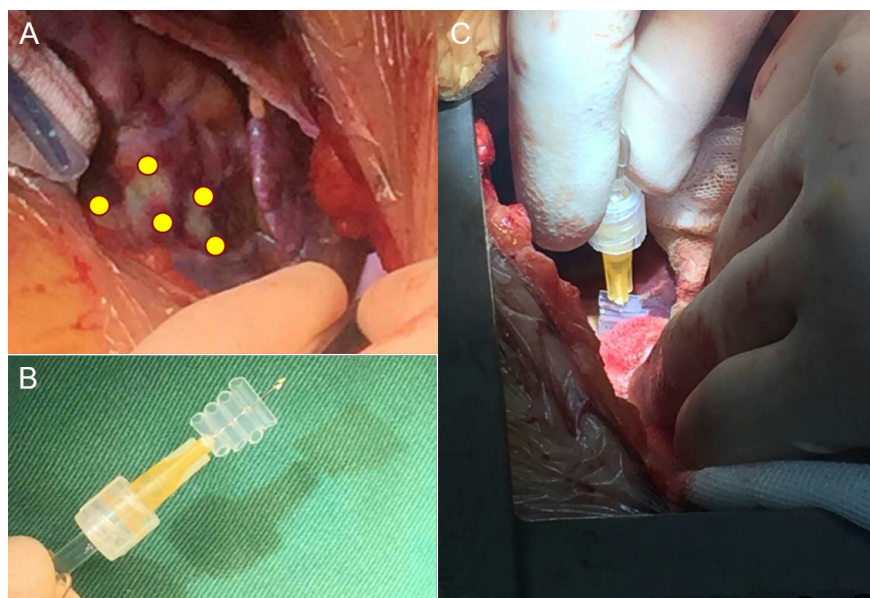


Figure 1: Direct epicardial ethanol injection. A: The sites of injection were selected at the border of direct RF lesion set. 3 to 5 injections were delivered around the region and 0.3 ml of absolute ethanol was used in each injection. B: the tip of needle was limited to 5mm in depth, guarded by plastic tubes. C: ethanol injection was performed under direct vision.

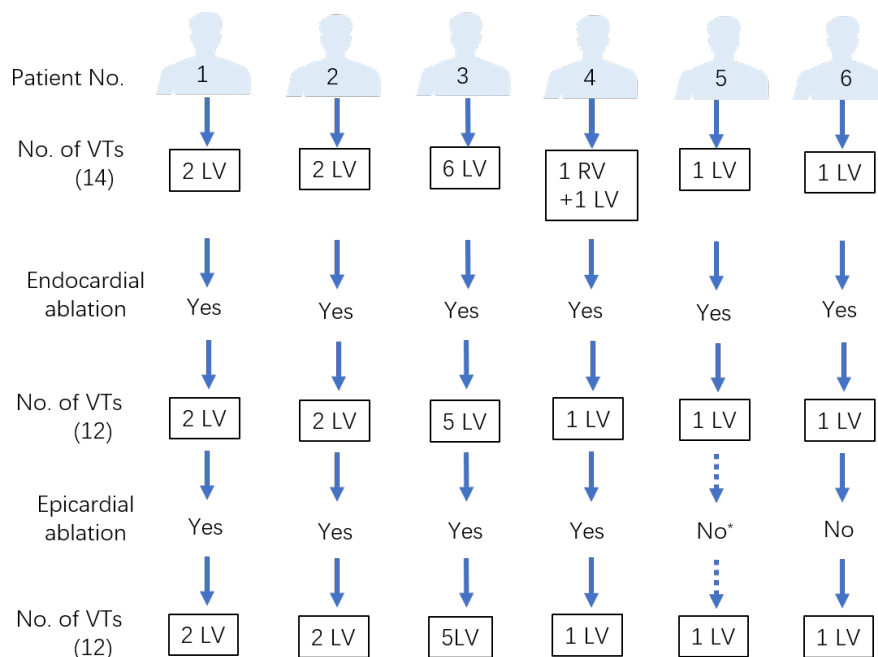


Figure 2. The outcomes of previous endocardial and epicardial ablation in 6 patients. LV: ventricular tachycardia from left ventricle; RV: ventricular tachycardia from right ventricle.

*: Pt-5 experienced puncture failure via subxiphoid approach due to epicardial adhesion.

Patient No.	1	2	3	4	5	6
Prior Device Implantation	ICD	CRT	DDD	ICD	ICD	ICD
Prior Percutaneous Ablation	3 endo + 2 epi	1 endo + 1 epi	3 endo + 3 epi	1 endo + 1 epi	1 endo	2 endo
Surgical Approach						
Step 1. VT Induction @Baseline	Yes	Yes	Yes	Yes	Yes	Yes
Step 2. VT ablation & substrate modification	Yes	Yes	Yes	Yes	Yes	Yes
Step 3. VT induction	Yes	Yes	Yes	Yes	Yes	Yes
Step 4. Ethanol Ablation	1.5ml	2.0ml	3.0ml	2.4ml	1.8ml	3.0ml
Step 5. VT Induction @End	AIVR	No	No	No	AIVR	No
Step 6. Combined Procedures	AVR	Epi-LV Lead placement		AVR+MVR +TVR		
	↓ 65M	↓ 30M	↓ 29M	↓ 13M	↓ 12M	↓ 6M
Follow-up outcomes	No VT	No VT, Die of Pneumonia	No VT	Non-sustained slow VT	No VT	No VT

Figure 3. The procedural flowchart and the follow-up outcomes of all 6 patients. Endo: endocardial mapping and ablation; Epi: epicardial mapping and ablation; VT: ventricular tachycardia; AIVR: accelerated idioventricular rhythm; AVR: aortic valve replacement; MVR: mitral valve repair; TVR: tricuspid valve repair.

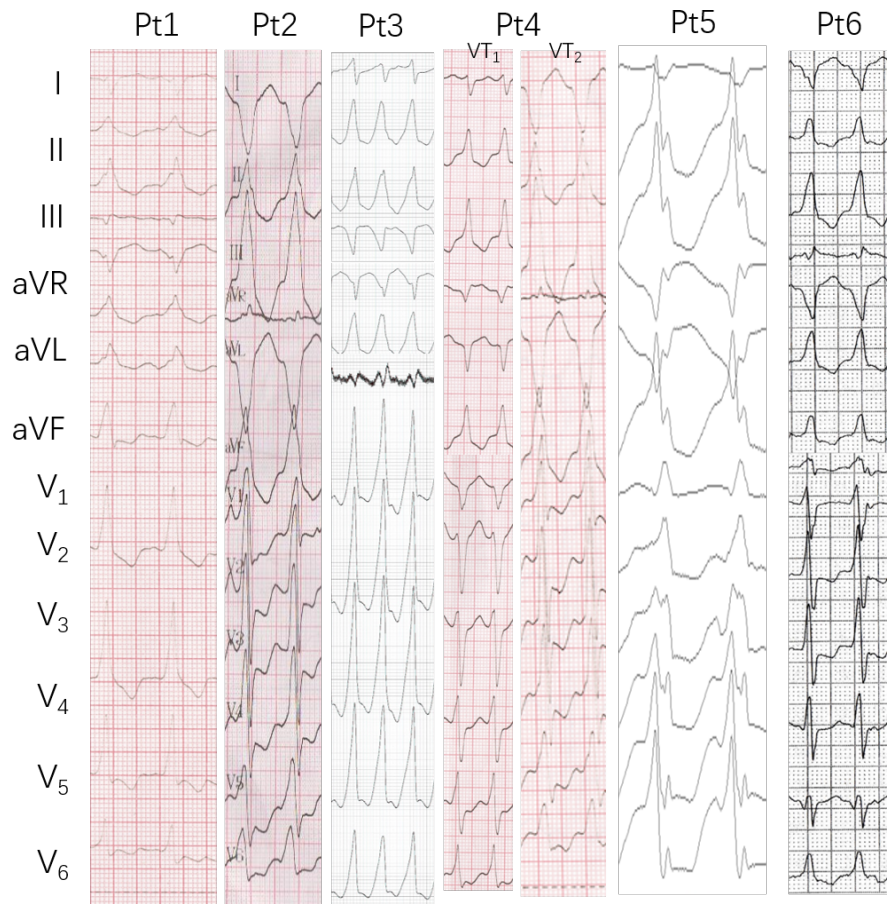


Figure 4. The examples of 12-lead surface electrocardiogram of ventricular tachycardia in 6 patients.

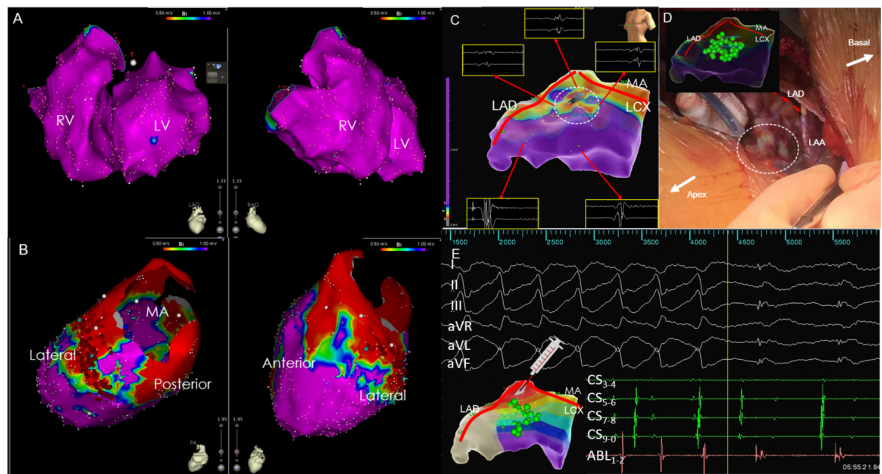
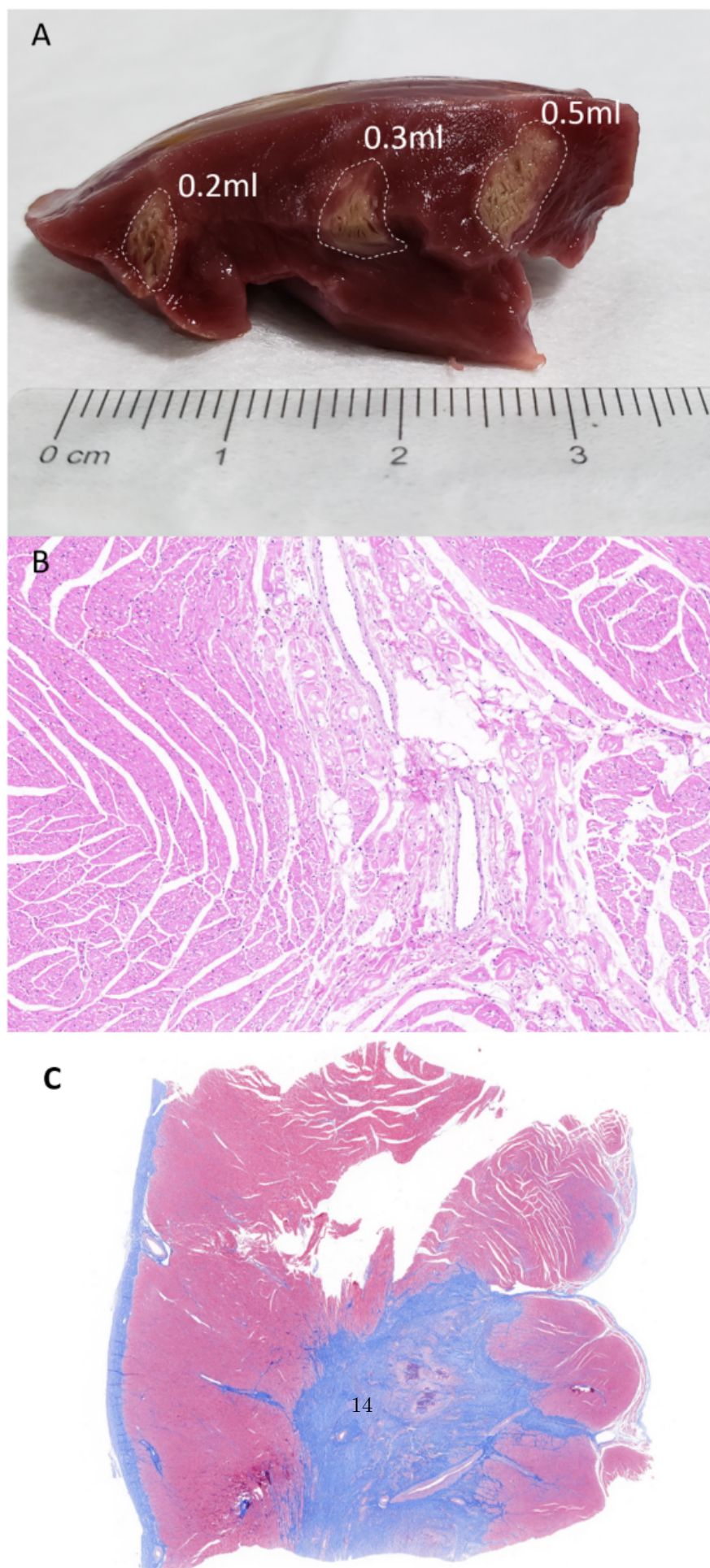


Figure 5. Endocardial, epicardial, surgical and ethanol ablation in Patient 3. A: LVZ could hardly be identified endocardially in both ventricles. B: small LVZ existed on the anterolateral wall near MA and epicardial lesions were placed in these areas. C: fragmented electrograms were identified and targeted at the bifurcation of LAD and LCX on the anterior wall. D: well-defined lesions could be seen after surgical ablation. E: VT could be induced again after surgical ablation. The activation map showed the earliest site close to the LCX. With one dose of 0.3 ml ethanol injection, VT was terminated immediately. RV: right ventricle; LV: left ventricle; LVZ: low voltage zone; MA: mitral annulus; LAD: left anterior descending artery; LCX: left circumflex artery.



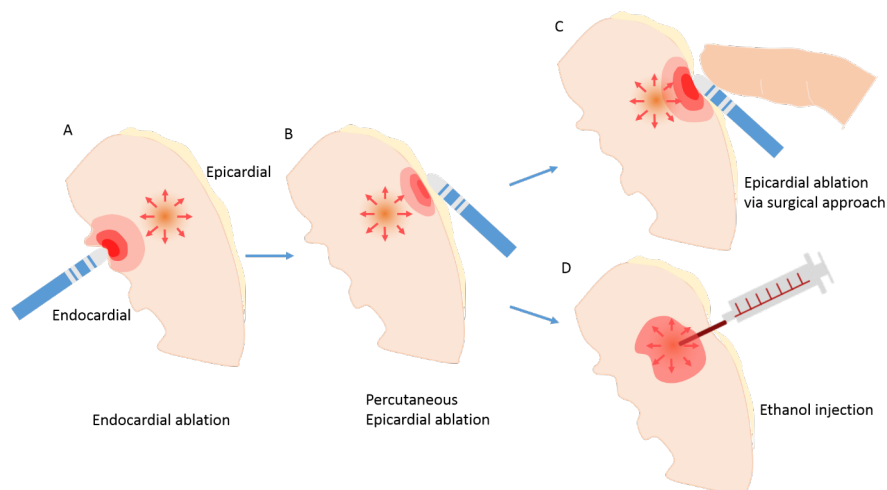


Figure 6. Lesion morphology and histological examination in ethanol ablated animal model. A: with increasing dose of ethanol (0.2, 0.3, 0.5ml), the lesion size increased correspondingly (8, 10, 12mm respectively). B: acute necrosis of the myocardium could be seen immediately after ethanol injection (HE \times 100). C: the chronic lesion was homogeneous with clear border (Masson's \times 10).

Graphic abstract: Surgical Epicardial Ablation Supplemented by Ethanol Injection for Ventricular Tachycardia Refractory to Percutaneous ablation. A: Energy penetration is insufficient by endocardial ablation to reach the critical tissue maintaining ventricular tachycardia. B: Percutaneous epicardial ablation is an alternative approach but is still not enough to touch the foci due to poor contact force and epicardial fat tissue. C: Direct epicardial ablation via surgical approach could make deeper lesions with increased contact force. D: Intramural ethanol injection could produce deep and homogenous lesions with clear boundary.