

# Accessory maxillary sinus ostia in superior meatus: a retrospective study and its clinical application

Hsiao-Wei Lu<sup>1</sup>, Pin-Zhir Chao<sup>1</sup>, Fei-Peng Lee<sup>1</sup>, Cheng-Jung Wu<sup>1</sup>, and Hsing-Won Wang<sup>1</sup>

<sup>1</sup>Taipei Medical University Shuang Ho Hospital Ministry of Health and Welfare

May 3, 2021

## Abstract

**Objectives:** To investigate the incidence of accessory maxillary sinus ostia in superior meatus in patients with clinical and radiological signs of maxillary sinusitis and the association with the development of chronic rhinosinusitis. **Design:** Retrospective study **Setting:** Tertiary care hospital **Participant:** 159 patients examined with paranasal sinus computed tomography scans **Main outcome measures:** We retrospectively evaluated patients who visited the outpatient department at an academic medical facility between January and April 2020 with a clinical diagnosis of chronic rhinosinusitis. Paranasal sinus axial and coronal computed tomography scans were evaluated for accessory maxillary sinus ostia in superior meatus and confirmed by reconstructed three-dimensional simulation images. The demographic information and incidence of accessory ostia in superior meatus were assessed. The Lund–Mackay score was used to rate chronic rhinosinusitis severity. Analysis of variance was performed to correlate the severity of chronic rhinosinusitis with presenting accessory ostia in superior meatus. **Results:** Of 159 patients (81 males; 78 females), 41.5% had accessory maxillary sinus ostia in superior meatus. Of these, two-thirds were bilateral and one-third was unilateral. The severity of rhinosinusitis was not correlated with having accessory maxillary sinus ostia in superior meatus, but the presence of accessory ostia was significantly associated with less severe chronic rhinosinusitis ( $P < 0.001$ ). **Conclusions:** Accessory maxillary sinus ostia in superior meatus are significantly associated with less severe chronic rhinosinusitis and most cases are bilateral.

## Accessory maxillary sinus ostia in superior meatus: a retrospective study and its clinical application

### Abstract

**Objectives :** To investigate the incidence of accessory maxillary sinus ostia in superior meatus in patients with clinical and radiological signs of maxillary sinusitis and the association with the development of chronic rhinosinusitis.

**Design:** Retrospective study

**Setting:** Tertiary care hospital

**Participant:** 159 patients examined with paranasal sinus computed tomography scans

**Main outcome measures :** We retrospectively evaluated patients who visited the outpatient department at an academic medical facility between January and April 2020 with a clinical diagnosis of chronic rhinosinusitis. Paranasal sinus axial and coronal computed tomography scans were evaluated for accessory maxillary sinus ostia in superior meatus and confirmed by reconstructed three-dimensional simulation images. The demographic information and incidence of accessory ostia in superior meatus were assessed. The Lund–Mackay score was applied to rate chronic rhinosinusitis severity. Analysis of variance was performed to correlate the severity of chronic rhinosinusitis with presenting accessory ostia in superior meatus.

**Results :** Of 159 patients (81 males; 78 females), 41.5% had accessory maxillary sinus ostia in superior meatus. Of these, two-thirds were bilateral and one-third was unilateral. The severity of rhinosinusitis was not correlated with having accessory maxillary sinus ostia in superior meatus, but the presence of accessory ostia was significantly associated with less severe chronic rhinosinusitis ( $P < 0.001$ ).

**Conclusions :** Accessory maxillary sinus ostia in superior meatus are significantly associated with less severe chronic rhinosinusitis and most cases are bilateral.

**Key words:** paranasal sinus, accessory ostium, maxillary, sinusitis, superior meatus

## Key points

1. Accessory maxillary sinus ostia in superior meatus is a novel anatomical variation and were detected in 41.5% of patients.
2. Among patients with accessory maxillary sinus ostia in superior meatus, two-thirds were found to be bilateral.
3. Patients with accessory maxillary sinus ostia in superior meatus had significant lower Lund-Mackay score which represent less severity of rhinosinusitis.

## Introduction

The natural ostium of the maxillary sinus is an anterior part of the posterior fontanelle and extends transversely with an oval shape toward the inferior part of the ethmoid infundibulum. In routine nasal endoscopic examinations, the ostium of the maxillary sinus is not typically visible.<sup>1</sup> An accessory maxillary ostium is an anatomical variant commonly observed in the middle meatus that potentially contributes to the development of chronic rhinosinusitis.<sup>2,3</sup> However, there is a lack of clarity about the causal relationship between accessory ostia and chronic rhinosinusitis.

Research has systematically evaluated the pathophysiology of chronic rhinosinusitis and has attributed it to aberrant interactions between environmental factors and the host immune system. Accessory or secondary ostia are defined as defects in the fontanelle region of the lateral nasal wall.<sup>4</sup> It has not yet been determined if accessory ostia are a congenital anatomical variant or if they are acquired. It has been postulated that accessory ostia are often found in the posterior nasal fontanelle of the middle meatus, and they may be unilateral or bilateral.<sup>5,6</sup>

Our evaluation of accessory maxillary sinus ostia highlighted some accessory ostia in the superior meatus. Previous studies conducting cadaver evaluations, computed tomography examinations, and endoscopies have reported various incidences of accessory maxillary sinus ostia in the middle meatus.<sup>7-9</sup> Accessory ostia in the maxillary sinus have been associated with chronic maxillary sinusitis, and these ostia can cause recirculation of mucus, leading to the recurrence of sinusitis.<sup>10,11</sup> Studies based on computed tomography have also indicated that accessory maxillary sinus ostia are significantly associated with chronic maxillary sinusitis.<sup>8,12</sup> Therefore, any interventional maxillary sinus surgery must be supported by an in-depth knowledge of anatomical variations in the accessory maxillary sinus ostia of the patient to ensure maximum results and to prevent recurrence.<sup>7</sup> However, there are few reports on accessory maxillary sinus ostia in the superior meatus and the association with chronic rhinosinusitis. Thus, this study investigated the incidence of accessory maxillary sinus ostia in the superior meatus of patients exhibiting clinical and radiological signs of maxillary sinusitis and associations with the severity of chronic rhinosinusitis.

## Materials and methods

### *Study design*

This retrospective study included patients visiting the outpatient department of Otolaryngology Head and Neck Surgery, Shuang Ho Hospital, Taipei Medical University. Patients visited between January and April 2020 with a chief complaint wherein chronic rhinosinusitis was suspected. We selected cases according to inclusion criteria with a clinical diagnosis of chronic rhinosinusitis confirmed by high-resolution computed tomography (HRCT) scan of paranasal sinuses. Bilateral accessory maxillary sinus ostia were viewed in

axial and coronal sections. (Figure 1). Images with suspicion of accessory maxillary sinus ostia in superior meatus were reconstructed by three-dimensional (3D) simulation to confirm the existence of accessory ostia (Figure 2). Patients who had systemic diseases such as cystic fibrosis, previous sinus surgery, acute sinusitis, maxillofacial trauma, inverted papilloma, cystic fibrosis, choanal atresia, or sinus anomalies were excluded. Finally, 159 patients were included for analysis.

### *Ethics statements*

This study was approved by the expedited review process of the Taipei Medical University-Joint Institutional Review Board (Approval Number: N202009022, Approval Date: 25 September 2020). Informed Consent was waived because of the retrospective nature of the study. All procedures carried out are in accordance with principles in Declaration of Helsinki. This article does not disclose any personally identifiable information of any of the participant. Hence, consent for publication is not applicable.

### *Data Availability Statement*

The data that generated and/or analysed during the current study are available from the corresponding author upon reasonable request.

### *Analysis of HRCT and 3D simulation images of accessory maxillary sinus ostia in superior meatus*

HRCT images were acquired using a computed tomography scanner (GE Brightspeed S, Boston, Massachusetts, United States) with a resolution of  $512 \times 512$  matrix size. Data were reconstructed with slices of 2.5 mm thickness and the inter-space was 2.5 mm. The images were analysed by the same software (Advantage workstation 4.4 Navigation, Wisconsin, United States). All HRCT images were evaluated by one examiner and 3D simulation images were all reconstructed by one radiologist without any patient identifiers.

In the HRCT scans and confirmed 3D-reconstructed images, bilateral maxillary sinus was assessed. An accessory maxillary sinus ostium in superior meatus was recorded as either 1) radiologically absent or 2) radiologically present.

### *Lund-Mackay score assessment*

The Lund-Mackay method was used to assess the HRCT images of chronic rhinosinusitis. Right and left sides were each grouped into six sinus areas including maxillary, anterior ethmoidal, posterior ethmoidal, sphenoid, frontal, and ostiomeatal complex. The severity of sinus mucosa opacification was scored as 0 (with no abnormality), 1 (partial opacification), or 2 (complete opacification). The ostiomeatal complex was assigned a score of either 0 (not obstructed) or 2 (obstructed).

### *Statistical analysis*

Data were expressed as the mean and standard deviation for comparison between the presence and absence of accessory maxillary sinus ostia in superior meatus in both left and right sides of the maxillary sinus. Statistical analysis was performed using one-way analysis of variance and Tukey test (SigmaPlot 12.5), with a P value of  $<0.05$  considered statistically significant. Sample size calculations were based on an alpha of 0.05 and a power value of 0.99.

## **Results**

### *Study population*

Participants included 159 patients (81 males; 78 females). Age ranged from 6 to 96 years, with an average age of 46.8 years (Table 1). Accessory maxillary sinus ostia in superior meatus were detected in 66 of 151 (41.5%) participants, of which 32 were males and 34 were females. Among the 66 cases with accessory ostia, two-thirds were found to be bilateral and one-third was unilateral (Table 2). Among the unilateral cases, 13 were in the left nasal cavity and nine were in the right.

### *Lund-Mackay score*

The association between accessory ostia of left and right maxillary sinus in the superior meatus and the Lund–Mackay score is shown in Figure 3. The Lund–Mackay score distribution in patients with accessory maxillary sinus ostia in superior meatus was similar to the score distribution in patients without accessory ostia. However, the mean and standard deviation of scores in patients without accessory ostia was approximately two points higher than in patients with accessory ostia in both the left and the right maxillary sinus. There was a statistically significant higher tendency for rhinosinusitis in patients without versus with accessory maxillary sinus ostia in superior meatus ( $P < 0.001$ ) (Table 3).

## DISCUSSION

Chronic rhinosinusitis is a commonly observed condition and has significantly contributed to healthcare consumption and productivity loss, affecting 5%–12% of the global population.<sup>13,14</sup> The obstructed drainage and ventilation of paranasal sinuses increase the risk of long-term inflammation.<sup>3</sup> Theoretically, the presence of accessory ostia implies disturbance in mucociliary clearance and the mucus circulation of the associated maxillary sinus, which may sustain chronic inflammation.<sup>11</sup>

We examined the incidence and associations of accessory maxillary sinus ostia in the superior meatus with the presence of chronic rhinosinusitis in a single-centre patient sample using HRCT and 3D simulation images. The results revealed that 41.5% (66) of the patients exhibited accessory maxillary sinus ostia in the superior meatus, irrespective of gender. Several studies conducting cadaver and live endoscopic examinations have reported 0–43% of humans have accessory maxillary ostia.<sup>7,15</sup> Mahajan et al. showed that accessory maxillary sinus ostia were observed in 42 out of 200 (21%) half heads,<sup>7</sup> and Mladina et al. reported a prevalence of 19.3% for accessory maxillary ostia, with 68% being bilateral.<sup>9</sup> Bani-Ata et al. showed that both maxillary and ethmoid sinusitis were significantly associated with male individuals, but the presence of a right or left accessory ostium had no correlation with gender or age.<sup>8</sup>

Our study showed a significant association between the absence of accessory maxillary sinus ostia in the superior meatus and the Lund–Mackay score. Accessory maxillary sinus ostia present in the superior meatus were associated with less severe chronic sinusitis. Our study is the first to identify and evaluate accessory maxillary sinus ostia in the superior meatus. Previous studies have shown that in patients who have experienced multiple episodes of maxillary sinusitis, the greater frequency of accessory maxillary sinus ostia can be attributed to pathology.<sup>1,3,7</sup> Ghosh et al. investigated the correlation between accessory maxillary ostia and chronic sinusitis and recommended that middle meatal antrostomy should include the posterior and anterior fontanelle to reduce mucus circulation.<sup>3</sup> If accessory maxillary ostia were present, there was an associated increased incidence of mucus retention cysts by three-fold and the frequency of findings of mucosal thickening and maxillary sinusitis doubled, as shown by Yenigun et al.<sup>12</sup> According to Capelli et al., a maxillary mucosa thickness [?] 2 mm and obstructed natural drainage of maxillary sinus were significantly correlated with chronic rhinosinusitis; however, they found no association between accessory maxillary ostia and chronic rhinosinusitis.<sup>16</sup>

Genc et al. examined 10 rabbits in New Zealand and found the development of accessory maxillary ostia after inducing sinusitis.<sup>17</sup> Accessory ostia can develop when mucosal oedema obstruct main ostia and when chronic sinusitis or other anatomical or pathological factors in the middle meatus disrupt ciliary movement, rupturing membranes in the lateral nasal wall.<sup>7</sup> The formation of accessory ostia could sustain sinus mucosa inflammation by enabling the recirculation of mucus between adjacent openings, leading to the chronic recurrence of sinusitis.<sup>18</sup> This study showed that patients with accessory maxillary sinus ostia in the superior meatus did not have a higher Lund–Mackay score compared with patients without accessory ostia. A possible inference is that accessory maxillary sinus ostia in the superior meatus are a congenital anatomical variation that do not obstruct the mucociliary clearance of the maxillary sinus. In fact, they may improve the mucus circulation of the maxillary sinus. Our results suggest that patients with accessory maxillary sinus ostia in the superior meatus may have an advantage in not being susceptible to chronic rhinosinusitis. For a surgeon, this information may indicate that patients with this anatomy will have better disease outcomes. However, as accessory maxillary sinus ostia may alternatively be individual anatomic variations of no clinical importance, it is essential to further investigate accessory maxillary sinus ostia in the superior meatus of

healthy subjects and in those with chronic maxillary sinusitis.

This study is subject to certain limitations given its retrospective nature and use of radiographic data. The research design does not examine the exact causal relationship between sinusitis and accessory maxillary sinus ostia in the superior meatus. In addition, the study is based on a small sample size and a single-centre design. However, the sample size is large enough to demonstrate statistical significance. While there are several studies that have explored maxillary sinus anatomy and its variations, no clinical research has been conducted on accessory maxillary sinus ostia in the superior meatus. This study is the first to investigate the accessory maxillary sinus ostia in the superior meatus and their incidence in patients with clinical and radiological signs of maxillary sinusitis.

## Conclusions

In conclusion, this study reveals a significant association of accessory maxillary sinus ostia in superior meatus with less severe chronic rhinosinusitis. This suggests that patients with accessory maxillary sinus ostia in superior meatus may experience better chronic rhinosinusitis outcomes. Additionally, most cases with accessory maxillary sinus ostia in superior meatus are bilateral, and the condition is considered a congenital anatomical variation. However, further studies are required to analyse this structure in healthy subjects and in those with chronic maxillary sinusitis to illuminate the relationship between recurrent sinusitis and accessory maxillary sinus ostia in superior meatus.

## References

1. Stammberger H, Posawetz W. Functional endoscopic sinus surgery. The Messerklinger technique. *Eur Arch Otorhinolaryngol* 1990; 247:63-76.
2. Sahin C, Ozcan M, Unal A. Relationship between development of accessory maxillary sinus and chronic sinusitis. *Med J DY Patil Univ* 2015; 8:606-608.
3. Ghosh P, Kumarasekaran P, Sriraman G. Incidence of accessory ostia in patients with chronic maxillary sinusitis. *Int J Otorhinolaryngol Head Neck Surg* 2018; 4:443-447.
4. Agency for Health Care Policy and Research. Diagnosis and treatment of acute bacterial rhinosinusitis *Evid Rep Technol Assess* 1999; 9.
5. Prasanna LC, Mamatha H. The location of maxillary sinus Ostium and its clinical application. *Indian J Otolaryngol Head Neck Surg* 2010; 62:335-337.
6. Singhal MD, Singhal DMK. Anatomy of accessory maxillary sinus ostium with clinical application. *Int J Med Sci Public Health* 2014; 3:327-329.
7. Mahajan A, Mahajan A, Gupta K, Verma P, Lalit M. Anatomical variations of accessory maxillary sinus ostium: an endoscopic study. *Int J Anat Res Int J Anat Res* 2017; 5:3485-3490.
8. Bani-Ata M, Aleshawi A, Khatatbeh A, et al. Accessory maxillary ostia: prevalence of an anatomical variant and association with chronic sinusitis. *Int J Gen Med* 2020; 13:163-168.
9. Prasanna LC, Mamatha H. The location of maxillary sinus ostium and its clinical application. *Indian J Otolaryngol Head Neck Surg.* 2010; 62:335-337.
10. Matthews BL, Burke AJ. Recirculation of mucus via accessory ostia causing chronic maxillary sinus disease. *Otolaryngol Head Neck Surg* 1997; 117:422-423.
11. Mladina R, Vuković K, Poje G. The two holes syndrome. *Am J Rhinol Allergy* 2009; 23:602-604.
12. Yenigun A, Fazliogullari Z, Gun C, et al. The effect of the presence of the accessory maxillary ostium on the maxillary sinus. *Eur Arch Otorhinolaryngol* 2016; 273:4315-4319.
13. Hirsch AG, Stewart WF, Sundaresan AS, et al. Nasal and sinus symptoms and chronic rhinosinusitis in a population-based sample. *Allergy* 2017; 72:274-281.
14. Sundaresan AS, Hirsch AG, Storm M, et al. Occupational and environmental risk factors for chronic rhinosinusitis: a systematic review. *Int Forum Allergy Rhinol* 2015; 5:996-1003.
15. May M, Sobol SM, Korzec K. The location of the maxillary os and its importance to the endoscopic sinus surgeon. *Laryngoscope* 1990; 100:1037-1042.
16. Capelli M, Gatti P. Radiological study of maxillary sinus using CBCT: relationship between mucosal thickening and common anatomic variants in chronic rhinosinusitis. *J Clin Diagn Res* 2016; 10:MC07-MC10.
17. Genc S, Ozcan M, Titiz A, Unal A. Development of maxillary accessory ostium following sinusitis in rabbits. *Rhinology* 2008; 46:121-124.
18. Aygun N, Zinreich SJ. Radiology of the nasal cavity and paranasal sinuses. In: Cummings eds. *Otolaryngology: Head & Neck Surgery*. 5th ed. Philadelphia, PA: Elsevier Mosby; 2010:662-663.

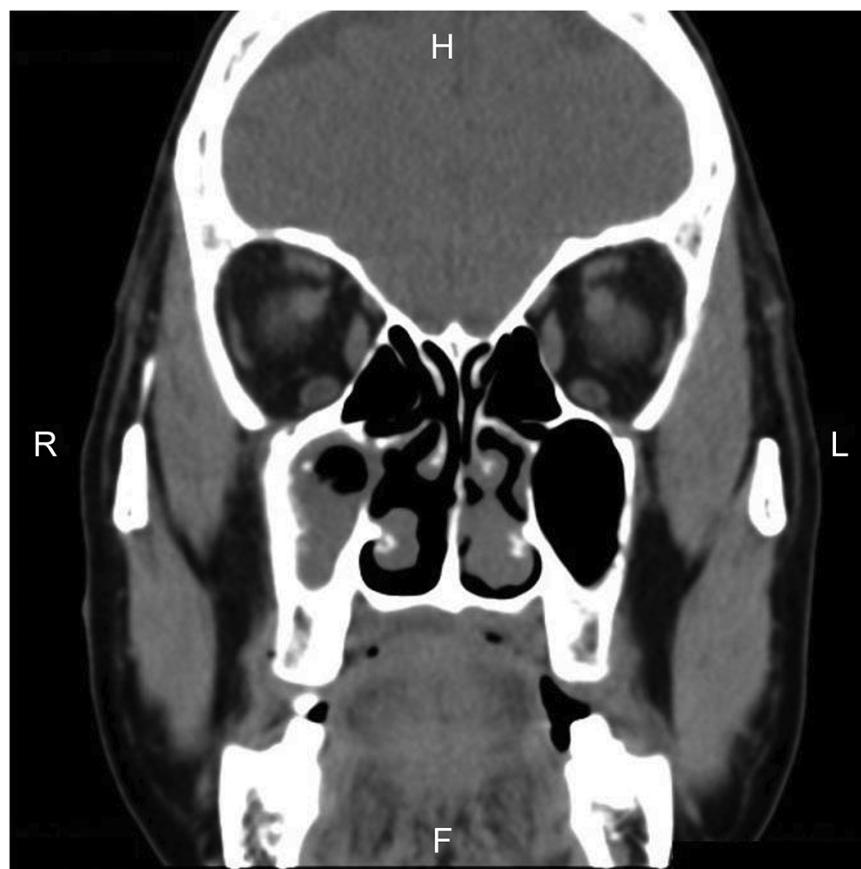## Figure legends

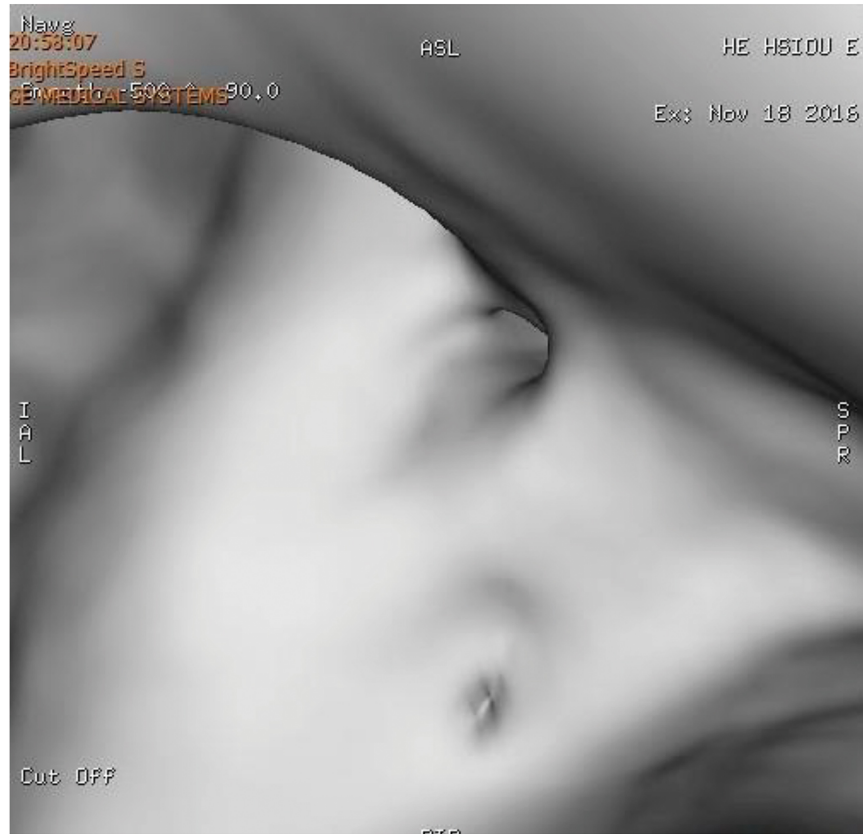Figure 1: Paranasal high-resolution computed tomography scan showed accessory maxillary sinus ostia in

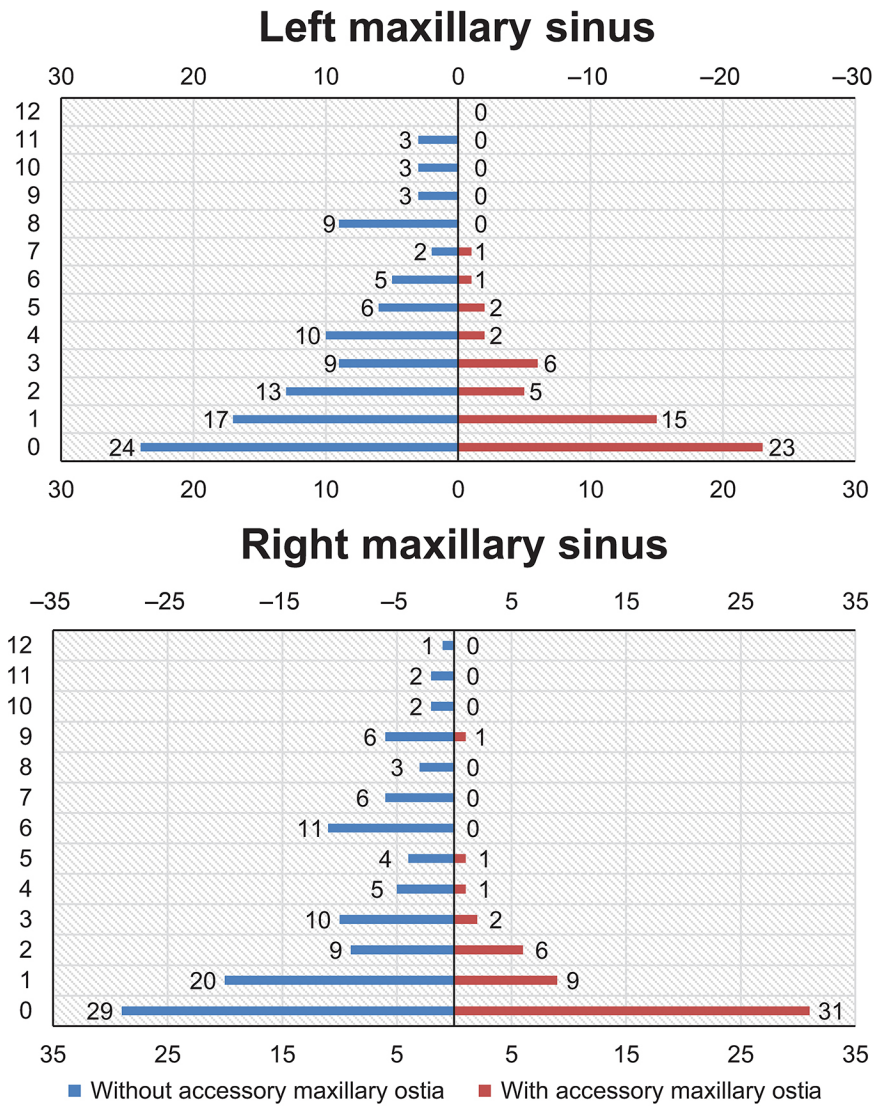
left superior meatus

Figure 2: Reconstruction of 3D simulation image to confirm accessory maxillary sinus ostia in superior meatus

Figure 3: Distribution of the Lund–Mackay score in patients with and without accessory ostia in the superior meatus of bilateral maxillary sinuses







#### Hosted file

Table1.pdf available at <https://authorea.com/users/411691/articles/520636-accessory-maxillary-sinus-ostia-in-superior-meatus-a-retrospective-study-and-its-clinical-application>

#### Hosted file

Table2.pdf available at <https://authorea.com/users/411691/articles/520636-accessory-maxillary-sinus-ostia-in-superior-meatus-a-retrospective-study-and-its-clinical-application>

#### Hosted file

Table3.pdf available at <https://authorea.com/users/411691/articles/520636-accessory-maxillary-sinus-ostia-in-superior-meatus-a-retrospective-study-and-its-clinical-application>