And the Oscar goes to peripheral blood film for detection of lead poisoning in a complicated toxic patient: A case report with review of laboratory clues

Amir Zamani[1], Ehsan Sarraf Kazerooni[1], S Saeed Kasaee[2], Mohammad Hossein Anbardar[3], Sahand Mohammadzadeh[3], Golsa Shekarkhar[4], and Neda Soleimani[3]

[1]Department of pathology, Shiraz Transplant Center, Abu Ali Sina Hospital, Shiraz University of Medical Sciences, Shiraz, Iran
[2]Department of oncology and hematology, Shiraz Transplant Center, Abu Ali Sina Hospital, Shiraz University of Medical Sciences, Shiraz, Iran
[3]Shiraz University of Medical Sciences
[4]raz pathobiology lab, shiraz, iran

May 10, 2021

Abstract

PBS provides the hematologic and/or non-hematologic picture of a case.A 40-year-old man with history of alcohol and marijuana abuse presented with extremities and abdominal pain.After extensive investigations, finding basophilic stippling on PBS led to the diagnosis of lead poisoning.PBS is the simplest screening test which provide rich morphological information.

And the Oscar goes to peripheral blood film for detection of lead poisoning in a complicated toxic patient: A case report with review of laboratory clues

Amir Zamani, Bachelor in medical laboratory Department of pathology, Shiraz Transplant Center, Abu Ali Sina Hospital, Shiraz University of Medical Sciences, Shiraz, Iran Zamania28@yahoo.com Ehsan Sarraf Kazerooni, MSC of hematology and blood bank Department of pathology, Shiraz Transplant Center, Abu Ali Sina Hospital, Shiraz University of Medical Sciences, Shiraz, Iran ehsan.sarraf1@gmail.com S Saeed Kasaee, hematologist and oncologist Department of oncology and hematology, Shiraz Transplant Center, Abu Ali Sina Hospital, Shiraz University of Medical Sciences, Shiraz, Iran Cnin.ir@gmail.com

Mohammad Hossein Anbardar, Assistant professor of pathology

Department of pathology, Shiraz Medical School, Shiraz University of Medical Sciences, Shiraz, Iran Department of pathology, Shiraz Transplant Center, Abu Ali Sina Hospital, Shiraz University of Medical Sciences, Shiraz, Iran*anbardarm@sums.ac.ir*

Sahand Mohammadzadeh , Assistant professor of pathology

Department of pathology, Shiraz Medical School, Shiraz University of Medical Sciences, Shiraz, Iran Department of pathology, Shiraz Transplant Center, Abu Ali Sina Hospital, Shiraz University of Medical Sciences, Shiraz, Iran mohammads@sums.ac.ir Golsa Shekarkhar, Molecular pathologist and cytogeneticist Pathology department, molecular pathology, Raz pathobiology lab, Shiraz, Iran g.shekarkhar@gmail.com

Neda Soleimani, Assistant professor of pathology

Department of pathology, Shiraz Medical School, Shiraz University of Medical Sciences, Shiraz, Iran Department of pathology, Shiraz Transplant Center, Abu Ali Sina Hospital, Shiraz University of Medical Sciences, Shiraz, Iran soleimani_n@sums.ac.ir

Running title: Laboratory data in lead poisoning

Correspondence: Neda Soleimani, Department of pathology, Shiraz University of Medical Sciences, Shiraz, Iran, e- mail: Soleimani_n@sums.ac.ir, phone number: 09173422519, 07132301784, fax: 07132301784

And the Oscar goes to peripheral blood film for detection of lead poisoning in a complicated toxic patient: A case report with review of laboratory clues

Clinical message

In addition to verifying the results of automated cell counters, the PBS has the potential to identify some pathologic morphologic changes that remain hidden using the cell counters alone. In order not to lose the cases, laboratories are recommended to design their own policy for peripheral blood smear review.

Abstract

PBS provides the hematologic and/or non-hematologic picture of a case.A 40-year-old man with history of alcohol and marijuana abuse presented with extremities and abdominal pain.After extensive investigations, finding basophilic stippling on PBS led to the final diagnosis of lead poisoning.PBS is the simplest screening test which provide rich morphological information.

Keywords

Lead poisoning, peripheral blood smear, basophilic stippling

Background

A manual blood smear review is defined as the thorough and careful microscopic analysis of a well-prepared and stained smear of the peripheral blood, with the objective of seeking morphological changes relevant to the diagnosis and monitoring of patients(1). Laboratory-initiated examinations of blood smears for patients with anemia are usually the result of a laboratory policy according to which a blood smear is ordered whenever the hemoglobin concentration is unexpectedly low. In these cases, despite the wealth of the captured information from modern automated cell counters including red-cell count, mean cell volume(MCV), mean cell hemoglobin(MCH), mean cell hemoglobin concentration(MCHC) and red-cell–distribution width(RDW), there are still morphologic abnormalities that are critical in the differential diagnosis of anemia and can be determined only from a blood smear. Particularly important is the detection of variations in the cell shape and of red-cell inclusions, such as Howell– Jolly bodies, Pappenheimer bodies and basophilic stippling or punctate basophilia. The last could suggest lead poisoning in the setting of matched clinical data (2).

Case presentation

A 40-year-old man was transferred to our center at Abu Ali Sina Hospital, Shiraz, Iran, to be evaluated for severe bone pain and abdominal pain for a month with worsening since 1 week ago. The bone pain was mostly limited to lower extremities and the abdominal pain was severe with colicky pattern and radiation to both scrotums. It was accompanied by nausea, vomiting and constipation. The patient was also complaining of severe weight loss (15 kg during a month). He was a fast food employee with history of excessive alcohol intake over 3 years, with no periods of abstinence. He was drinking 1-2 liters of homemade alcohol (using traditional container for distillation) daily until few days prior to admission. Additionally, he reported a history of on and off synthetic marijuana abuse till 3 days prior to admission. His past medical history was not significant and he was not taking any medication. His physical examination was significant for high blood pressure (180/100 mmHg), tachycardia (108/min) and low grade fever (37.9°C) with abdominal and both scrotal tenderness.

Laboratory investigations at presentation showed moderate microcytic and hemolytic anemia in addition to significantly elevated liver enzymes. Abdominopelvic sonography and CT scan showed biliary sludge and small liver hemangioma, respectively. Other laboratory and imaging investigations (color doppler sonography of mesenteric artery and vein, upper gastrointestinal endoscopy, colonoscopy) were unremarkable. He underwent cholecystectomy with the impression of acute cholecystitis and the microscopic pathologic diagnosis was just chronic cholecystitis without cholelithiasis. Due to the presence of unexplained anemia and severe bone pain, bone marrow study was done for him to rule out of leukemia, which was in favor of myelodysplastic syndrome (MDS) with 10% ring sideroblasts (Figure 1). Cytogenetic study was normal. Complete blood count (CBC) test with peripheral blood smear (PBS) checking (according to our policy in the hematology laboratory) was done for the patient several times at presentation and during hospitalization. Blood film examinations revealed mild to moderate anemia, microcytic hypochromic red blood cells with, anisocytosis, polychromasia and also frequent coarse basophilic stippling of the red cells (Figure2 A, B); the last one was missed at the first PBS review. Regarding the presence of ring sideroblasts in the bone marrow report, the possibility of lead poisoning was considered and surprisingly the blood lead level was markedly raised (151 µg/dL; reference range was 10 µg/dL). Since there was no occupational exposure, the traditional distillation dish (made of copper and lead) was traced as the possible source of the lead.

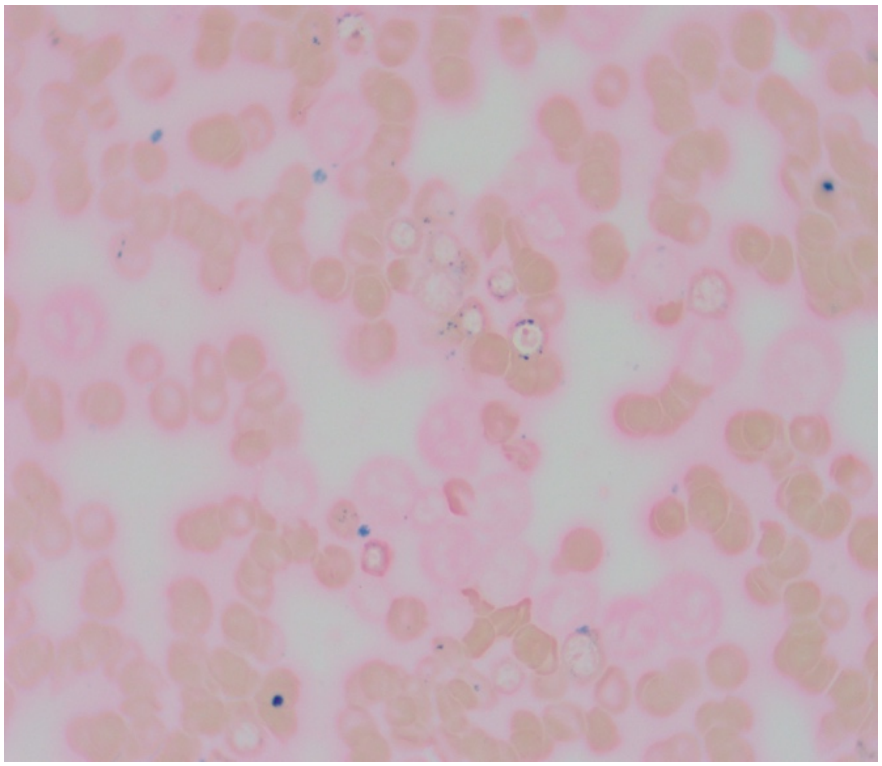

Figure 1: Bone marrow smear (Perls Prussian blue stain) showing that about 10% of erythroid precursors are ring sideroblasts

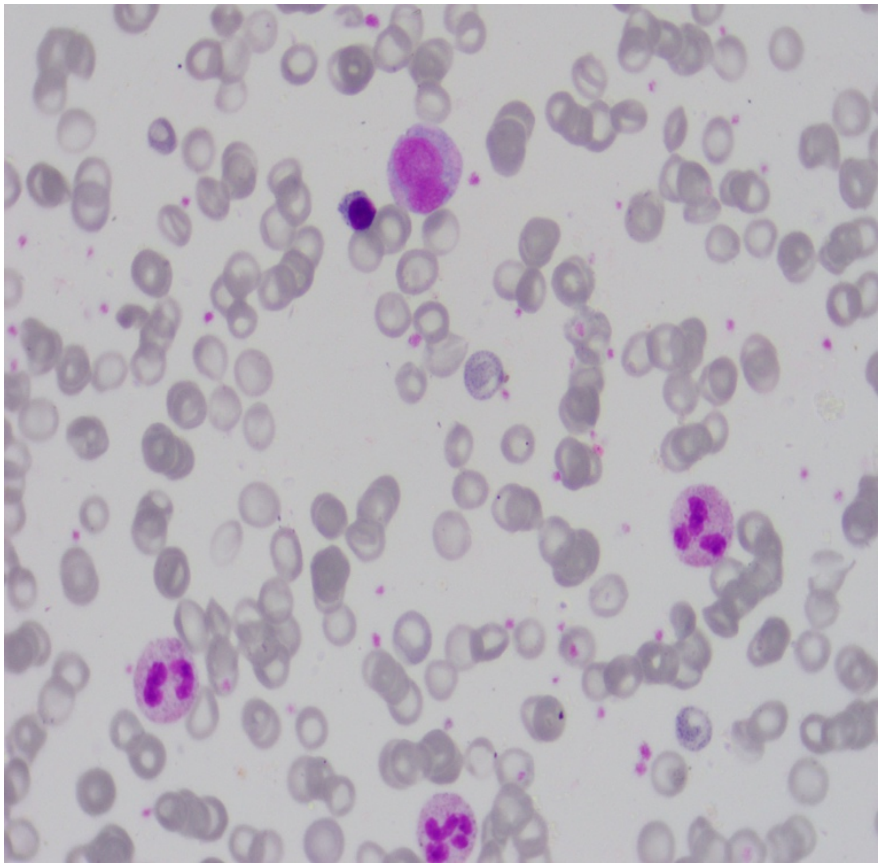

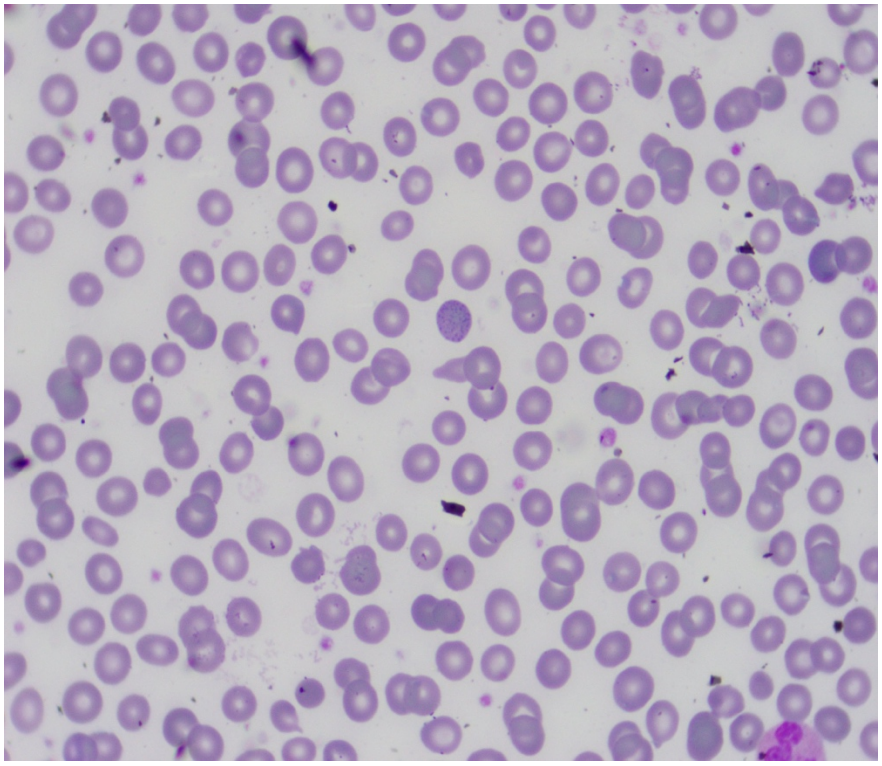

Figure 2A, B: peripheral blood smear with basophilic stippling of red blood cells(arrows)

The patient stopped drinking alcohol and marijuana abuse. Chelating therapy with Succimer was initiated, with a dose of 500 mg (5 capsules) daily and now after 4 weeks the blood lead level has declined to 25 µg/dl and there is 6 kg weight gain. All signs and symptoms were removed and all laboratory findings changed to normal condition. Although there are some documented researches supporting the correlation between hypertension and lead poisoning, in our case, marijuana withdrawal could also be the cause of sympathetic overactivity(3). Table 1 shows the transition of laboratory data from the first presentation to recovery time.

Table 1: The initial and final (post-treatment) results of the laboratory tests

Parameter(unit)
AST(IU/L)
ALT(IU/L)
ALP(IU/L)
Total Bilirubin(mg/dL)
Direct Bilirubin(mg/dL)
ESR(mm/Hr)
ΩB"(ξ 10^3 /µΛ)
HB(g/dL)
MCV(fl)
MCH(pgr)
MCHC(g/dL)
RDW-CV(%)
ΠΛT(ξ 10^3 /µΛ)
Reticulocyte count(%)

Parameter(unit)
Blood sugar, blood urea nitrogen(BUN), creatinine, sodium, potassium, calcium, magnesium, phosphorus, r

AST: Aspartate aminotransferase **MCV:** Mean corpuscular volume

ALT: Alanine aminotransferase **MCH:** Mean corpuscular hemoglobin

ALP: Alkaline phosphatase **MCHC:** Mean corpuscular hemoglobin concentration

ESR: Erythrocyte sedimentation rate **RDW-CV:** red cell distribution width- coefficient of variation

WBC: White blood cell **PLT:** Platelet

HB: Hemoglobin

Discussion

CBC is the most commonly ordered test in hospitalized patients. Modern automated blood cell counters produce a detailed report on the red cells, white cells and platelet, with differential white blood cell counts. A drop of the remaining blood could then be smeared and stained (4). Microscopic examination of this smear under expert eye yields useful information and further details regarding all formed elements of the blood (5). "More information can be gained from examining the blood smear than from any other single hematologic procedure", Jandl in 1987 said (6). This shows the value of PBS review in the medical management. Initiation of a PBS review depends on the laboratory policy. It could be a clinical request by the attending clinician on the account of a clinical suspicion or initiated by the laboratory due to clinical information, numerical deviations in the automated counts, flags raised by the analyzers or based on a designed protocol in the laboratory(based on workload of the laboratory) (4, 7). For certain disorders, for instance hematologic malignancies or parasitic infestations, examination of the PBS can be diagnostic. For others such as our case, the PBS provides important clues in the clinical management and determines which diagnostic tests are indicated (2).

Among all useful data obtained from the blood smear, there is valuable information about the red blood cell size, shape, staining (color) and intracellular inclusions. Red cell inclusions often result from defective maturation of the erythrocytes, oxidant injury to the cells or infections and are almost always indicative of some sort of pathology. Basophilic stipplings (punctuate basophilia) are well-known red cell inclusions. In fact they are denatured RNA fragments dispersed within the cytoplasm (7). They are present as irregular basophilic granules which stain deep blue with Wright's stain. They vary from fine to coarse. Fine stippling is commonly seen with increased production of the red cells. Coarse stippling may be seen in haemoglobinopathies (thalassemias), sideroblastic anemia, megaloblastic anemia, and a rare inherited condition, pyrimidine 5' nucleotidase deficiency. Sideroblastic anemia is characterized by accumulation of iron in the mitochondria, which appears as ring distribution around the nucleus of the erythroid precursors on iron stain. Sideroblastic anemia occurs as primary or secondary (5,7).

Lead poisoning is an important cause of secondary sideroblastic anemia because environmental exposure to lead is usually unrecognized and needs to be detected (5). Lead exposure usually occurs through contaminated air and food. Excess lead affects almost every organ in the body. The major anatomic targets are the blood (bone marrow), nervous system, gastrointestinal tract, and kidneys. Lead has a high affinity for sulfhydryl groups and interferes with the enzymes involved in heme synthesis. Iron incorporation into heme is impaired, leading to microcytic hypochromic anemia with distinctive punctate basophilic stippling of the red cells. Lead also inhibits sodium- and potassium-dependent ATPases in the cell membranes, an effect that may increase the fragility of red cells, causing hemolytic anemia (8).

The classic form of lead neuropathy consists of weakness that primarily involves the wrist and finger extensor (wristdrop and footdrop). Excess lead could induce "lead lines" formation in epiphyses of the bone and gum. The gastrointestinal tract is also a locus for major clinical manifestations. Lead "colic" is characterized by

extremely severe, poorly localized abdominal pain and finally since the excretion of lead occurs through the kidneys, exposures may cause damage to the proximal tubules, interstitial fibrosis and possibly renal failure(8).

Since lead poisoning is a condition with potential multiorgan damage, it can be traced in the human body with variable laboratory tests. The half-life of lead in the blood and bone is 35 days and 32 years, respectively, so the blood lead level just reflects the current and recent exposure (5, 9). Table 2 shows different laboratory tests, their properties and changes in cases of lead poisoning. Elevated blood lead (> 10 μ/dL) and red cell free protoporphyrin levels (> 50 μg/ dL) or, alternatively, zinc-protoporphyrin levels, are required for definitive diagnosis (5).

Table 2: Change of different laboratory tests in lead poisoning

Test	Specimen	Diagnostic clue	Mechanism
HB	Whole blood	Decreased	Microcytic and hemolytic
MCV	Whole blood	Decreased	Iron incorporation into he
MCH	Whole blood	Decreased	Iron incorporation into he
PBS	Whole blood	Coarse basophilic stippling - Cabot rings	Instability of RNA and re
Retic count	Whole blood	Increased	Hemolytic anemia due to i
BM iron stain	BM aspiration smear	Ring sideroblast	Iron accumulation in the r
Blood lead level	Whole blood	Increased	*
zinc-protoporphyrin	Whole blood	Increased	zinc-protoporphyrin is for
free red cell protoporphyrin	Whole blood	Increased	It's a product of zinc-prot
LDH	Serum/Plasma	Increased	Hemolytic anemia(10)
Liver enzymes	Serum/Plasma	Increased	Increasing oxidative stress
BUN / Cr	Serum/Plasma	Increased	Proximal tubular dysfunct
Urine glucose	Urine	Increased (positive)	Proximal tubular dysfunct

*not applicable

HB: hemoglobin

MCV: mean corpuscular volume

MCH: mean corpuscular hemoglobin

PBS: peripheral blood smear

BM: bone marrow

LDH: lactate dehydrogenase

BUN: blood urea nitrogen

Cr: creatinine

Impairment of the hematological system is one of the earliest signs of lead accumulation and could be characteristic. Even in milder cases of lead exposure, anemia may be the only obvious abnormality (5). Obviously, the PBS is the fastest, simplest and cost-effective test which could also be made and examined at emergency and screening rooms at hospitals and could prevent unnecessary laboratory tests and other invasive diagnostic procedures including inappropriate laparatomy(13). Since this process is among the most time-consuming ones in hematology laboratories and requires high technical competence to minimize the errors of subjectivity, each laboratory should make its own policy to review the blood smears. Clearly providing clinical data including occupational and environmental health history through communication between the clinicians and the laboratory team could lead to a more rapid and accurate diagnosis(14).

Our patient was a case of chronic lead poisoning with atypical symptoms and signs, such as severe bone pain and highly elevated liver enzymes which caused delayed diagnosis. In this case, a lot of laboratory and imaging work ups including hematologic tests (and also the initial PBS) failed to reach a correct diagnosis, while the second PBS review by an expert clarified the long and painful story. We believe that even the first PBS review may discover the problem if it is reviewed accurately and/or is provided with typical clinical data.

Conclusion

This case emphasizes that all patients with unknown disease should be evaluated in terms of PBS at the first work up and the PBS in all patients (hematologic and non- hematologic) should be reviewed systematically regarding all blood elements. Lead poisoning is more common than our estimation. As clinical manifestations are non-specific and may be misdiagnosed with other pathophysiological conditions, at least it should be included in differential diagnosis lists of adult unexplained anemia (especially in the setting of matched clinical data) and basic initiative laboratory tests such as PBS could rule out the need for invasive, expensive and time consuming procedures.

List of abbreviations

Mean cell volume: MCV, Mean cell hemoglobin: MCH, Mean cell hemoglobin concentration: MCHC, Red-cell–distribution width: RDW, Myelodysplastic syndrome: MDS, Complete blood count: CBC, Peripheral blood smear: PBS, Blood urea nitrogen: BUN, Aspartate aminotransferase: AST, Alanine aminotransferase: ALT, Alkaline phosphatase: ALP, Erythrocyte sedimentation rate: ESR, White blood cell: WBC, Platelet: PLT, Hemoglobin: HB, Bone marrow: BM, Lactate dehydrogenase: LDH, Creatinine: Cr.

Declarations:

Ethics approval and consent to participate

Our institutional approval was not required to publish the case details.

Consent for publication

A written informed consent was obtained by the patient for publishing the case report and the publication of the accompanying images.

Availability of data and materials

All data generated or analysed during this study are included in this published article.

Competing interests

The authors declare that they have no competing interests.

Funding

Not applicable.

Authors' contributions

ZA, SKE and SN developed the concept of the study and the study design and wrote the draft manuscript. ZA, SKE, KSS and SN extracted the history. KSS examined the patient. SHG re-examined the bone marrow smears and biopsy and reported the findings. ZA, SKE, SN, KSS, AMH, MS, SHG with the input of all authors interpreted the patient data. AMH and MS reviewed and analysed all laboratory data. All authors read and approved the final manuscript.

Acknowledgements

The authors would like to thank Shiraz University of Medical Sciences, Shiraz, Iran and also Center for Development of Clinical Research of Nemazee Hospital and Dr. Nasrin Shokrpour for editorial assistance.

References

1. Comar SR, Malvezzi M, Pasquini R. Evaluation of criteria of manual blood smear review following automated complete blood counts in a large university hospital. Rev Bras Hematol Hemoter. 2017;39(4):306-17.
2. Bain BJ. Diagnosis from the blood smear. N Engl J Med. 2005; 353:498-507.
3. Vaziri ND. Mechanisms of lead-induced hypertension and cardiovascular disease. ajpheart. 2008; 295(2): 545-65.
4. Lee AC. Diagnosing Infections from the Peripheral Blood Smear. Hong Kong Journal of Paediatrics. 2018; 23(1):25-8.
5. McPherson RA, Pincus MR, "Henry's clinical diagnosis and management by laboratory methods," Elsevier, Philadelphia, PA, USA, 23rd ed, 2017.
6. Jandl JH. Blood: "Textbook of Hematology," Little, Brown and Company, Boston, 1st ed, 1987.
7. Adewoyin AS, Nwogoh B. Peripheral blood film- a review. b Postgrad Med. 2014;12(2):71-9.
8. Kumar V, Abbas AK, Aster JC. Robbins Basic Pathology. Philadelphia, PA, USA, 10th ed, 2018.
9. Roberts JR, Reigart JR, Ebeling M, Hulsey TC. Time required for blood lead levels to decline in nonchelated children. J Toxicol Clin Toxicol. 2001;39(2):153-60.
10. Shabani M, Hadeiy SK, Parhizgar P, Zamani N, Mehrad H, Hassanian-Moghaddam H et al. Lead poisoning; a neglected potential diagnosis in abdominal pain. BMC Gastroenterol. 2020;20(1):134.
11. Farmand F, Ehdaie A, Roberts CK, Sindhu RK. Lead-induced dysregulation of superoxide dismutases, catalase, glutathione peroxidase, and guanylate cyclase. Environ Res. 2005;98(1):33-9.
12. Nolan CV, Shaikh ZA. Lead nephrotoxicity and associated disorders: biochemical mechanisms. 1992; 73(2): 127-46.
13. Kehoe RA. Occupational lead poisoning: Chemical signs of the absorption of lead. Journal of Occupational Medicine. 1972; 14(5): 390-6.
14. Soleimani N, Mokhtari M, Mohammadzadeh S. From Reactive Lymphadenopathy to Systemic Vasculitis, the Importance of Providing Sufficient Clinical Information to Optimize Pathological Interpretation, a Case Report. International Medical Case Reports Journal. 2020; 13: 1-5.