

# A rare case of spontaneous abdominal aorta thrombosis

ahmad matarneh<sup>1</sup>, amna sadiq<sup>1</sup>, Adeel Khan<sup>2</sup>, asma Eltahir<sup>1</sup>, mazin alansari<sup>1</sup>, and  
abdulmoqeeth mohammad<sup>1</sup>

<sup>1</sup>Hamad medical corporation

<sup>2</sup>Hamad Medical Corporation

June 6, 2021

## Abstract

Spontaneous abdominal aorta thrombosis is extremely rare. Symptoms vary widely, ranging from asymptomatic to more catastrophic presentations. We report the case of a 40-year-old lady who presented with 1-week history of abdominal pain and was found to have spontaneous abdominal aorta thrombosis.

**Title: A rare case of spontaneous abdominal aorta thrombosis**

## Authors:

Ahmad Samir Salam Matarneh, Department of Internal Medicine, Hamad Medical Corporation, Doha, Qatar

Amna Sadiq, Department of Radiology, Hamad Medical Corporation, Doha, Qatar

Adeel Ahmad Khan, Department of Internal Medicine, Hamad Medical Corporation, Doha, Qatar

Asma Ibrahim Eltahir, Pharmacy department-section of clinical pharmacy, Hamad General Hospital, Doha, Qatar

Dr. Mazen alansari, internal medicine consultant, internal medicine department, Hamad General Hospital, Doha, Qatar

AbdulMoqeeth Mohammed, Senior consultant, Internal Medicine Clinic, Hamad General Hospital, Doha, Qatar

\*Corresponding Author

Dr. Ahmad Samir Salam Matarneh.

Department Internal Medicine.

Hamad Medical Corporation.

Al Rayyan street.

Doha, Qatar.

Tel: +97455957396

Fax: -44397857

E-mail: AMatarneh@Hamad.qa

Keywords: Aorta thrombosis, thrombophilias, ischemic colitis

## Keyboard Clinical message

Spontaneous aortic thrombosis is rare, and prompt diagnosis is needed whenever encountering a case of unexplained abdominal pain. the cause of the thrombosis needs to be evaluated thoroughly to rule out any underlying thrombophilias.

### **Abstract:** Introduction:

Spontaneous abdominal aorta thrombosis is extremely rare with an unclear incidence due to its infrequent occurrence. Symptoms vary widely, ranging from being asymptomatic to a more catastrophic presentation with organ ischemia. We report the case of a 40-year-old lady who presented with 1-week history of abdominal pain and was found to have spontaneous abdominal aorta thrombosis.

### Case presentation:

A 40-year-old lady, presented to the hospital with 1-week history of generalized abdominal pain, moderate to severe in intensity, associated with nausea and 4 episodes of vomiting. An initial CT scan of abdomen with contrast showed features of abdominal aorta thrombosis with ischemic colitis. Screening for an autoimmune etiology or hereditary thrombophilia was negative. The patient was treated with anticoagulation and she showed evidence of improvement in clinical symptoms and partial resolution of thrombus on follow up radiology.

### Conclusion:

Spontaneous aortic thrombosis is rare in occurrence. Evaluation includes abdominal imaging with either, CT scan or MRI, and the cause of the thrombosis needs to be evaluated thoroughly. Treatment includes anticoagulation and if needed re-vascularization by endovascular methods.

### **Introduction:**

Spontaneous abdominal aorta thrombosis is extremely rare with an unclear incidence due to its infrequent occurrence. To this date, there is very limited data on spontaneous abdominal aorta thrombosis in literature (1). It is of clinical significance because it can lead to devastating manifestations if it is not detected and treated in a timely manner. Symptoms vary widely, ranging from being asymptomatic to a more catastrophic presentation with organ ischemia (2). We present a case of a patient with severe abdominal pain who was found to have ischemic colitis secondary to spontaneous abdominal aorta thrombosis.

### **Case presentation:**

A 40-year-old lady, presented to the hospital with 1-week history of generalized abdominal pain, moderate to severe in intensity, associated with nausea and 4 episodes of vomiting, with no aggravating or relieving factors. There was no history of fever, hematemesis, bleeding per rectum, chest pain or palpitations. Patient was a known case of hypothyroidism, vitiligo, and type 1 diabetes mellitus. She was a non-smoker. Patient had no personal or family history of thrombophilia and there was no history of recurrent abortions. Physical examination revealed an afebrile patient, with heart rate of 92 beats per minute, blood pressure 124/76 and respiratory rate 17 breaths per minute. Abdominal examination showed diffuse tenderness, no organomegaly, normal percussion note with normal bowel sounds. Cardiac, respiratory and nervous system examination as normal.

Labs investigations showed mild neutrophilic leukocytosis, high C-reactive proteins, microcytic anemia, normal urea, creatinine, electrolytes and liver function tests (table 1). Coagulation testing showed normal PT, aPTT and INR (Table 2).

A computed tomography (CT) scan of abdomen with contrast showed diffuse thickening of the splenic flexure, descending colon and sigmoid colon with surrounding mesenteric oedema and fat stranding as well as a thrombus in the abdominal aorta at the level of L3 vertebra (Figure 1,2). However, all the thrombophilia screen and autoimmune work up was negative (Table 3).

Patient was managed as a case of ischemic colitis due to spontaneous abdominal aorta thrombosis. She was started on anticoagulation with warfarin bridged by therapeutic dose enoxaparin with a target INR of 2-3. A follow up CT-Scan of abdomen that was done 2 months afterwards showed resolution of thrombus and improvement of the inflammatory changes in the bowel (Figure 3). Three months afterward, she presented with left sided abdominal pain, nausea and vomiting. CT scan of the abdomen was done, and it showed Focal segmental circumferential mural thickening of the distal descending colon as a complication of the ischemic colitis the patient was admitted and underwent left hemicolectomy. She was then discharged home after improvement.

**Discussion:** Spontaneous arterial thrombosis is rare in occurrence, but It has a significant clinical importance as it leads to several complications' secondary to blood flow impediment (3). It can involve any organ system with the resulting ischemia and/or infarction. Prompt diagnosis and management is always needed as any delay can cause acute complications which can include renal infarction, stroke, abdominal and peripheral ischemia with gangrene, and might eventually lead to death. Presentation depends on the system or the organ involved (3). Clinically significant thrombosis can be because of a primary hypercoagulable state or as secondary to trauma, immobilization or other coagulopathic abnormalities. Suspicion should arise towards an underlying abnormality whenever a patient has history of unprovoked arterial or venous occlusion. Evaluation for causes such as factor V Leiden, antithrombin III deficiency or protein C or S deficiency is warranted in unprovoked cases (4).

Spontaneous abdominal aorta thrombosis is rare as the blood flowing in the aorta has a high velocity which, along with high caliber of the artery, makes it less prone to thrombosis and it is almost always secondary to an underlying hypercoagulable status. (5) It can present with manifestations that could range from asymptomatic in cases of chronic thrombosis to a more severe one in patients with acute thrombosis which can lead to devastating results with hemodynamic instability and even peripheral or abdominal organ loss. (6) As the abdominal aorta is the major source of arterial supply, its involvement can lead to renal artery ischemia with renal infarction, colonic ischemia, and limbs ischemia. Diagnosis should always be prompt. Initial evaluation should start with basic laboratories such as CBC, which can show increased white cell count, increased lactate denoting ischemia, acute kidney injury or liver injury. Urgent imaging evaluation should be done next. CT scan with contrast is usually the imaging diagnostic of choice as it can reveal the thrombus and allow prompt diagnosis of any underlying complication. CT scan can also help in excluding other diagnoses. (7) A full and thorough evaluation for possible underlying hypercoagulability must be sought. Treatment should be pursued as soon as possible, and it usually depends on the presentation and hemodynamic stability. Usually, the approach in stable patients with an established thrombus is to start on anticoagulation with warfarin and bridging enoxaparin (8). There is currently limited data at present on the novel anticoagulants use in hereditary thrombophilia's and in spontaneous aorta thrombosis. The duration of anticoagulation is usually guided by the underlying cause, as some patients require life-long anticoagulation for prophylaxis (9).

## Conclusion:

Spontaneous aortic thrombosis is rare in occurrence, and prompt diagnosis is needed whenever encountering a case of unexplained abdominal pain or embolic phenomena. Evaluation includes abdominal imaging with either, CT scan or MRI, and the cause of the thrombosis needs to be evaluated thoroughly to rule out any secondary hypercoagulable states as well as evaluating for primary hypercoagulability. Treatment includes anticoagulation and if needed re-vascularization by endovascular methods.

**Data availability statement:** The data that support the findings of this study are available from the corresponding author upon reasonable request.

**Authors Contribution:** Ahmad S matarneh: History and physical examination, literature review, manuscript writing Amna sadiq: Radiology, clinical images Adeel Ahmad Khan: Literature review, manuscript writing Asma Eltahir: Clinical Care Mazen Alansari: Clinical care AbdulMoqeeth Mohammed: Clinical care, manuscript writing

## References:

- 1 Lemaire A, Maniatis G, Vagaonescu T, Moreyra A, Lee LY. Mobile Thrombus in the Ascending Aorta Associated With Acute Myocardial Infarction. *Journal of Hematology*. 2015 Dec 22;4(4):228-30.
- 2 Madershahian N, Kuhn-Regnier F, Mime LB, Slottosch I, Langebartels G, Sindhu D, Wahlers T. A loose cannon: free-floating thrombus in ascending aorta. *Journal of cardiac surgery*. 2008 Sep 10;24(2):198-9.
- 3 O'Donnell M, Shatzel JJ, Olson SR, Daughety MM, Nguyen KP, Hum J, DeLoughery TG. Arterial thrombosis in unusual sites: A practical review. *European journal of haematology*. 2018 Dec;101(6):728-36.
- 4 Senst B, Tadi P, Basit H, Jan A. Hypercoagulability. *StatPearls* [Internet]. 2020 Mar 24.
- 5 Mandegar MH, Roshanali F, Kocharian A. Complicated course consequences of a floating thrombus in ascending aorta. *European Journal of Echocardiography*. 2008 Nov 1;9(6):846-8.
- 6 Sanon S, Phung MK, Lentz R, Buja LM, Tung PP, McPherson DD, Fuentes F. Floating, non-occlusive, mobile aortic thrombus and splenic infarction associated with protein C deficiency. *Journal of the American Society of Echocardiography*. 2009 Dec 1;22(12):1419-e1.
- 7 Soo A, Marley D, McGrath-Soo L, Herron B, Parissis H. Ascending aorta thrombus: a diagnostic and treatment dilemma. *Asian Cardiovascular and Thoracic Annals*. 2014 Jul;22(6):731-3.
- 8 Bowdish ME, Weaver FA, Liebman HA, Rowe VL, Hood DB. Anticoagulation is an effective treatment for aortic mural thrombi. *Journal of vascular surgery*. 2002 Oct 1;36(4):713-9.
- 9 Valdivia AR, Santos AD, Ureña MG, Lozano AR, Sanus EA, Guaita JO, Gandaria C. Anticoagulation alone for aortic segment treatment in symptomatic primary aortic mural thrombus patients. *Annals of vascular surgery*. 2017 Aug 1;43:121-6.

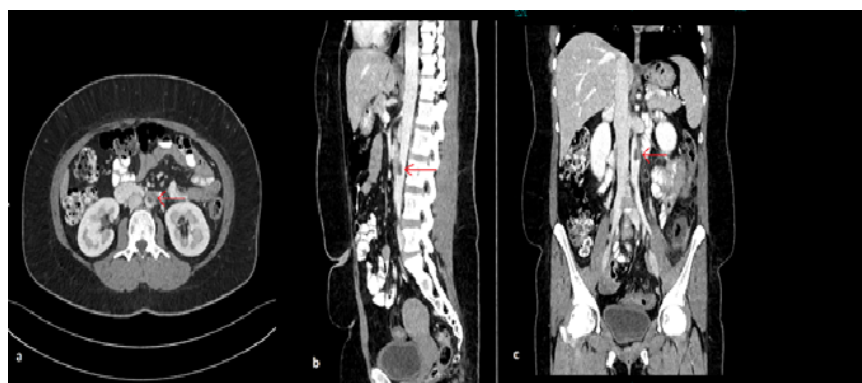


Figure 1: (a) Axial CT. (b) Sagittal CT. (c) Coronal CT abdomen with contrast showing a filling defect in the abdominal aorta at the level of L3 vertebrae consistent with aortic thrombus (arrow).

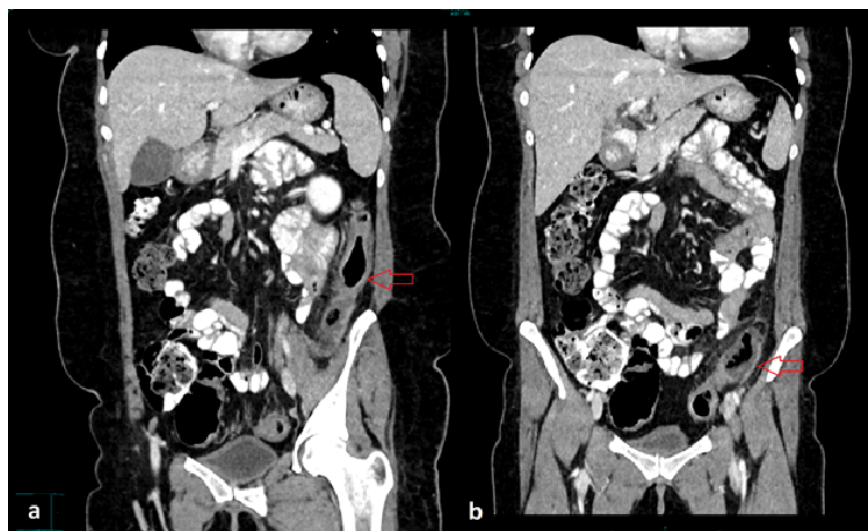

Figure 2: Coronal CT abdomen showing mural thickening and peri-colonic fat stranding in (a) descending colon and (b) sigmoid colon suggestive of ischemic colitis.

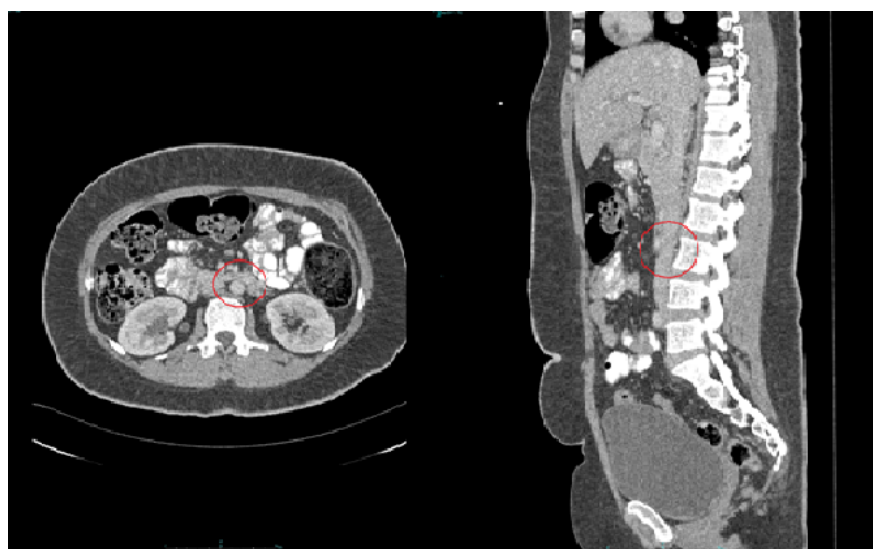


Figure 3. Follow up CT abdomen with contrast (a) axial and (c) sagittal view shows complete resolution of the previously seen abdominal aorta thrombus in the circled area at the level of L3 vertebrae.