

IMAGES

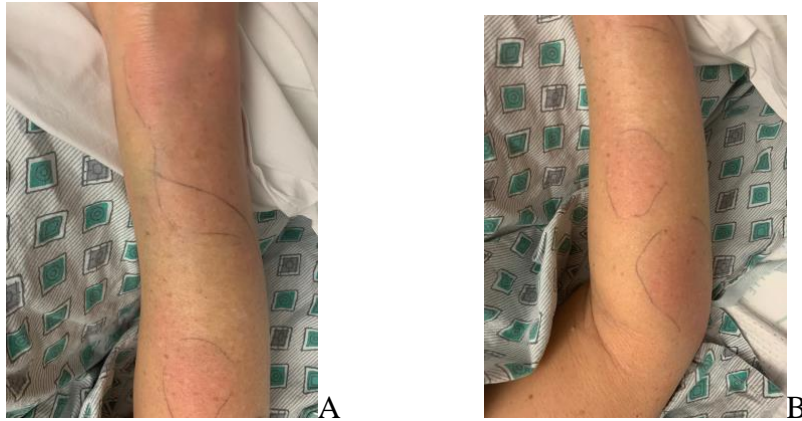


Figure 1. Cutaneous eruptions associated with *Streptococcus dysgalactiae* bacteremia. **A**, Erythematous and tender plaque on the right forearm. **B**, Erythematous and tender plaque on the left forearm