

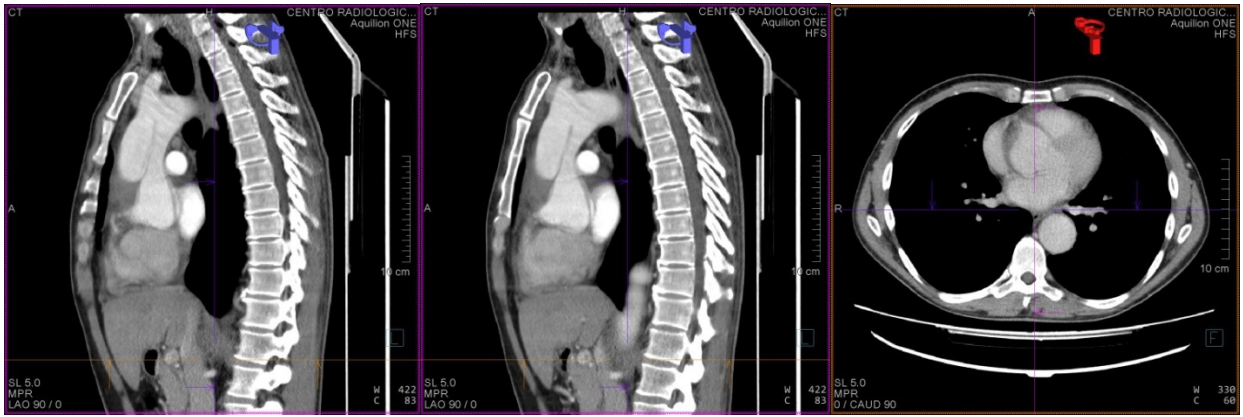

Figure 1. Section of CT scan: A and B shows the aortic root affected by the dissection. C: Transverse section of the aortic root.

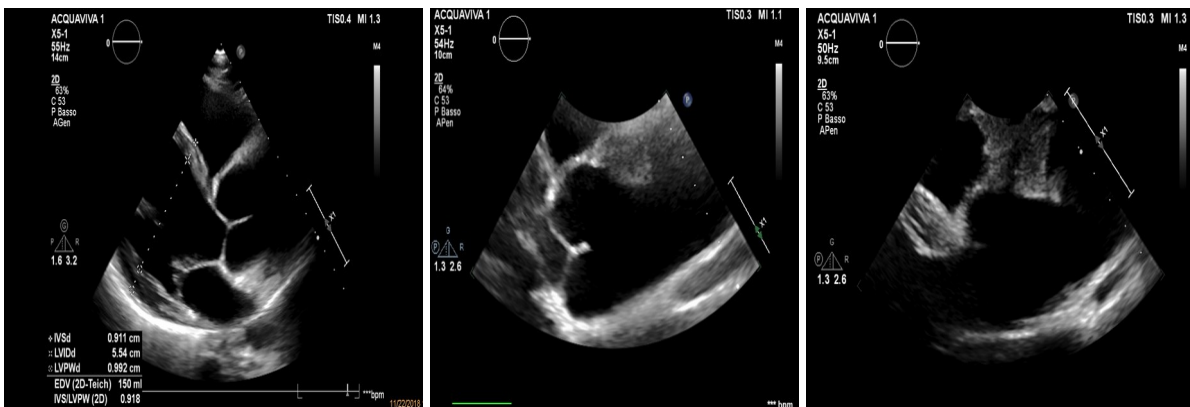


Figure 2.

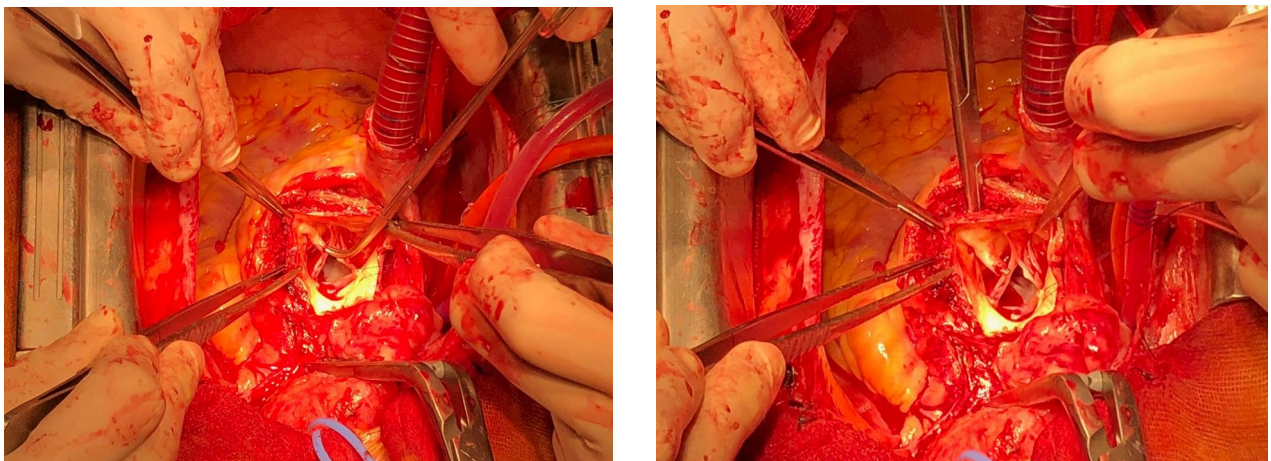


Figure 3. Intraoperative view of aortic root and aortic wall.