

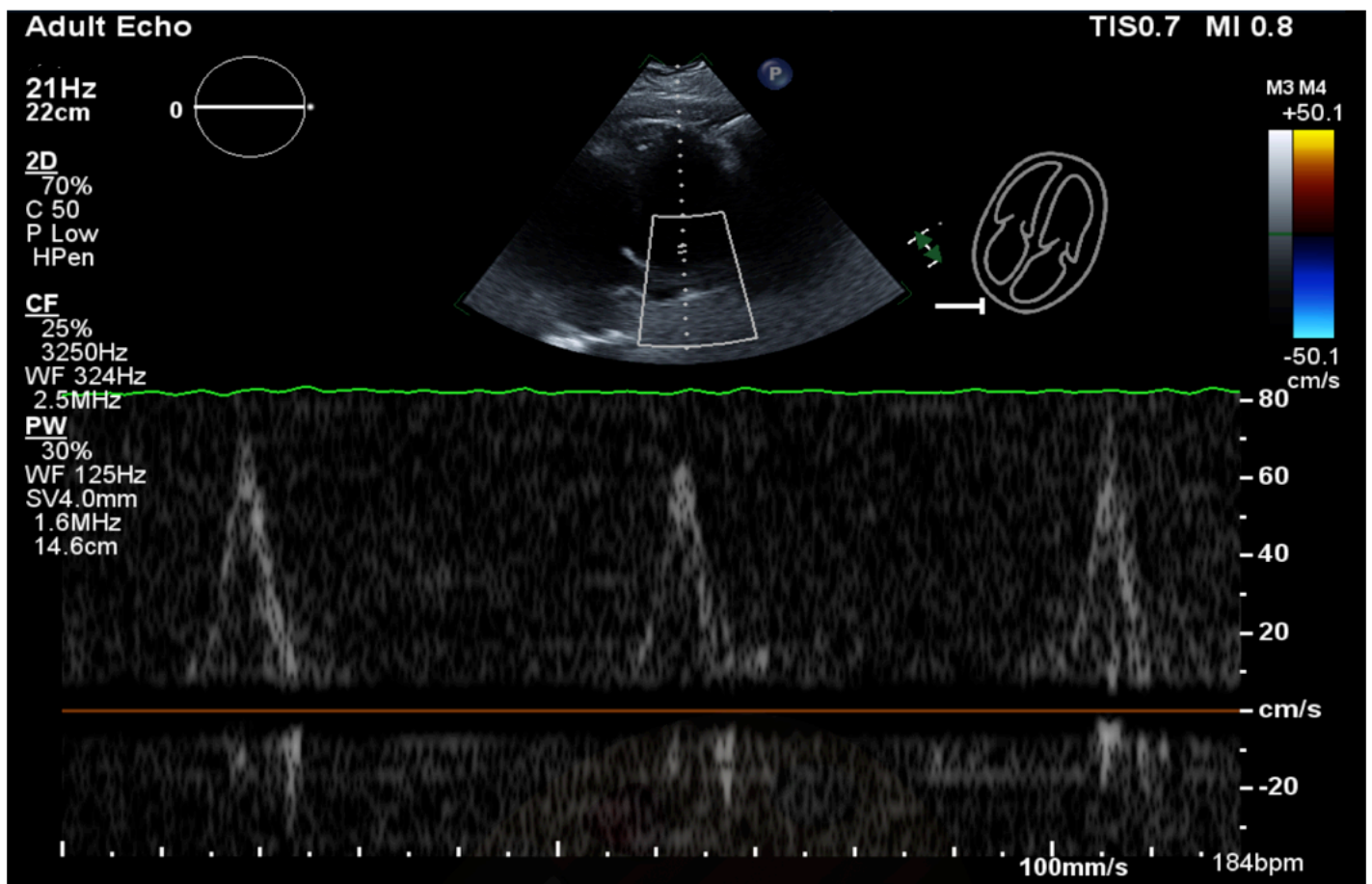Image 1: Pulsed-Wave Doppler of mitral inflow shows rhythmic ventricular filling.

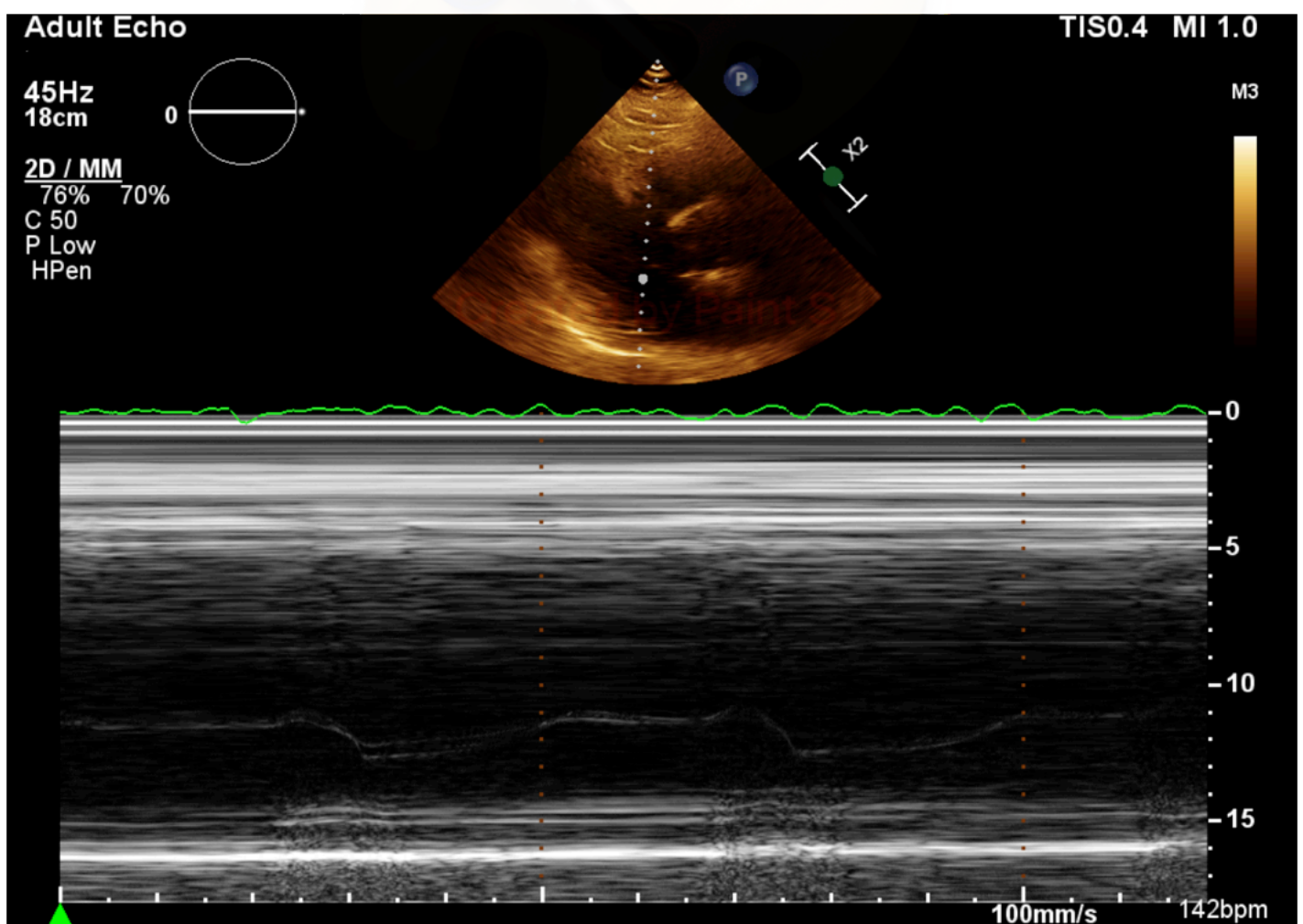


Image 2: M-Mode of the mitral valve leaflets reveals rhythmic opening and closing of valve leaflets.