

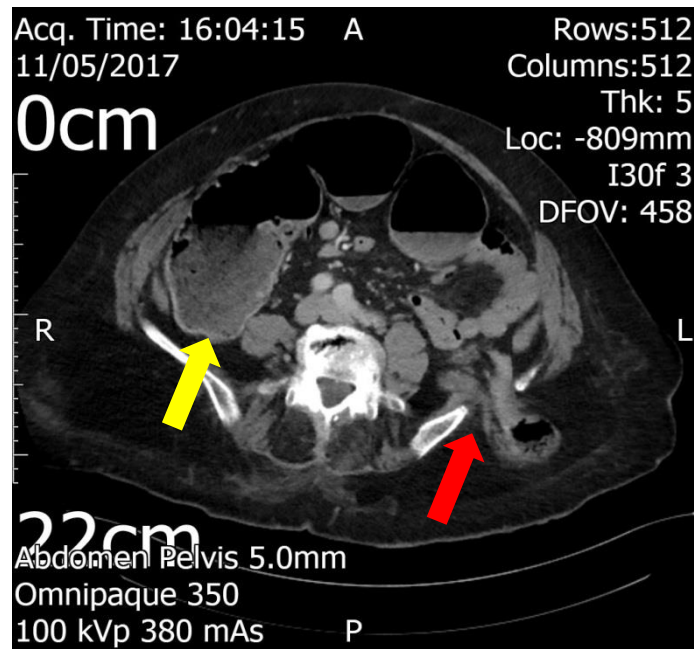Figure 1: Axial view of the preoperative CT scan showing the site of the incarcerated transiliac bone hernia, with part of the descending colon protruding through the defect (red arrow). Note the presence of cecal dilatation (yellow arrow), which in absence of small bowel dilatation, was suggestive of closed loop colonic obstruction and mandated urgent laparotomy

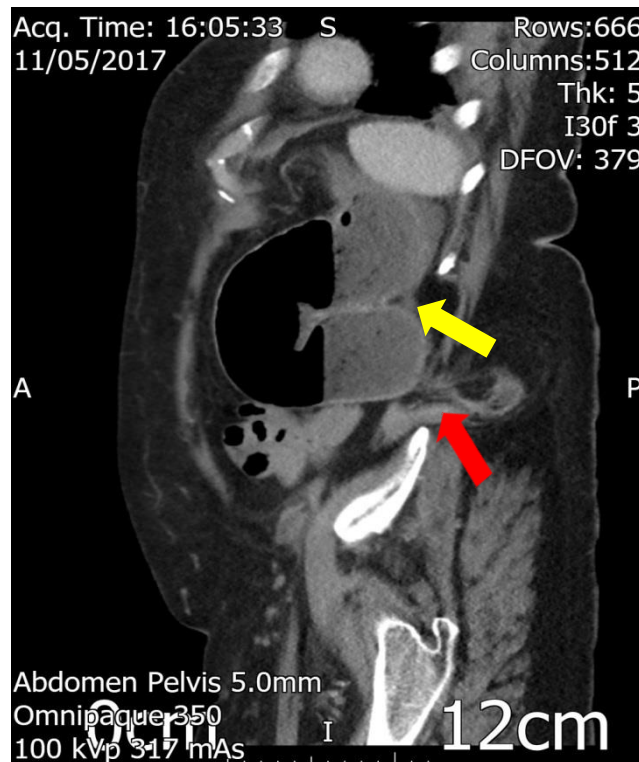


Figure 2: Sagittal view of the preoperative CT scan showing the site of the incarcerated transiliac bone hernia (red arrow), with evident proximal colonic obstruction (yellow arrow)