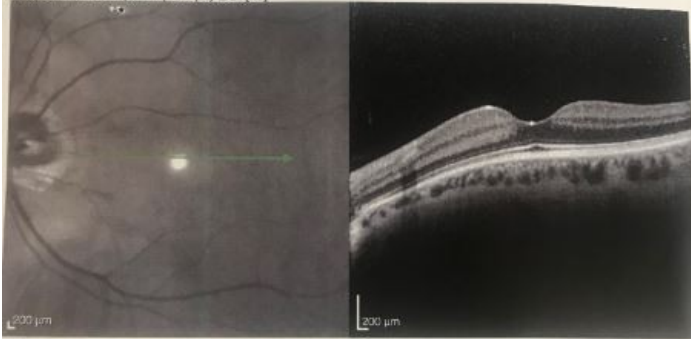


Patient: Bozorgi, Ali  
Patient ID: ---

DOB:  
Exam.:

IR 30° ART + OCT 20° (6.0 mm) ART (26) Q: 24 [HS]



4 30° ART + OCT 20° (6.0 mm) ART (25) Q: 18 [HS]

