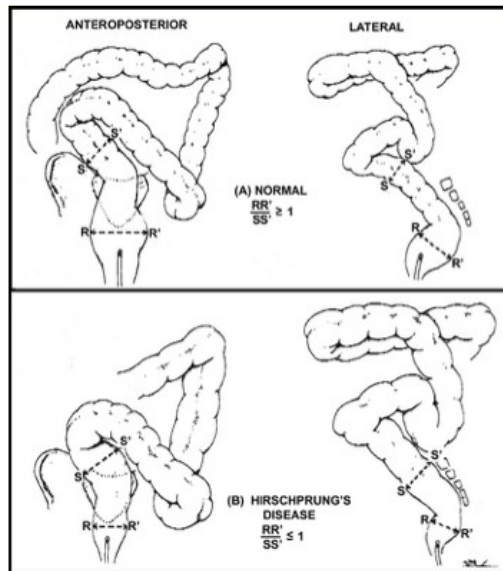


X-ray imaging of the patient with suspected Hirschsprung's disease ( A: Broad-based air-fluid levels in the abdominal radiography of a patient with abdominal distension, B: Anterior/posterior barium enema graphy, C: Lateral barium enema graphy, D: Control X-ray radiography after 24 hours from barium enema application)



**Figure 2-** **A.** Normal RSI measurement. The ratio of the widest diameter (RR') of the rectum to the widest diameter (SS') of the sigmoid colon is greater than or equal to 1. **B.** Anormal RSI: Hirschsprung's disease: Ratio is less than 1