

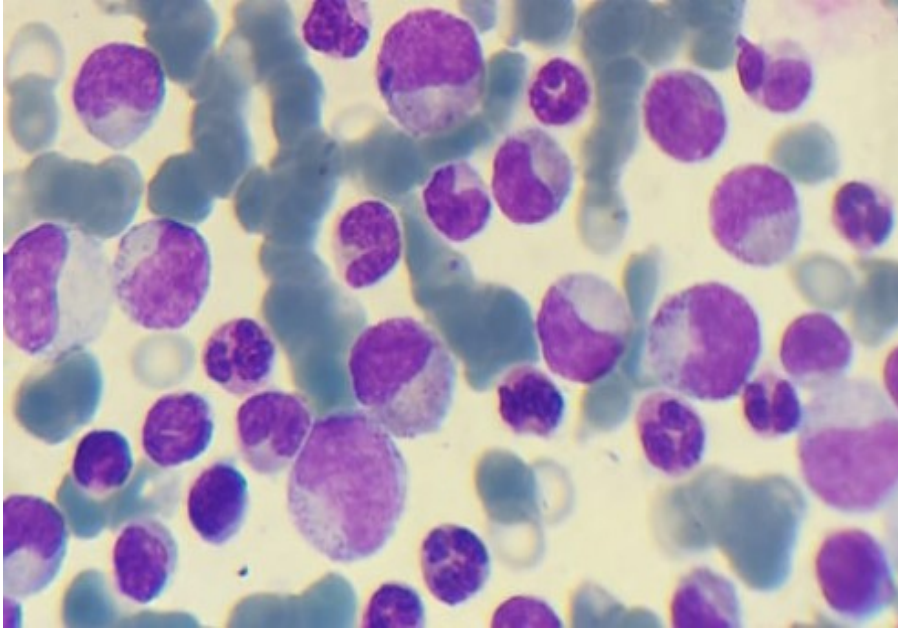Figure 1: Cytological appearance of pediatric chronic myeloid leukemia

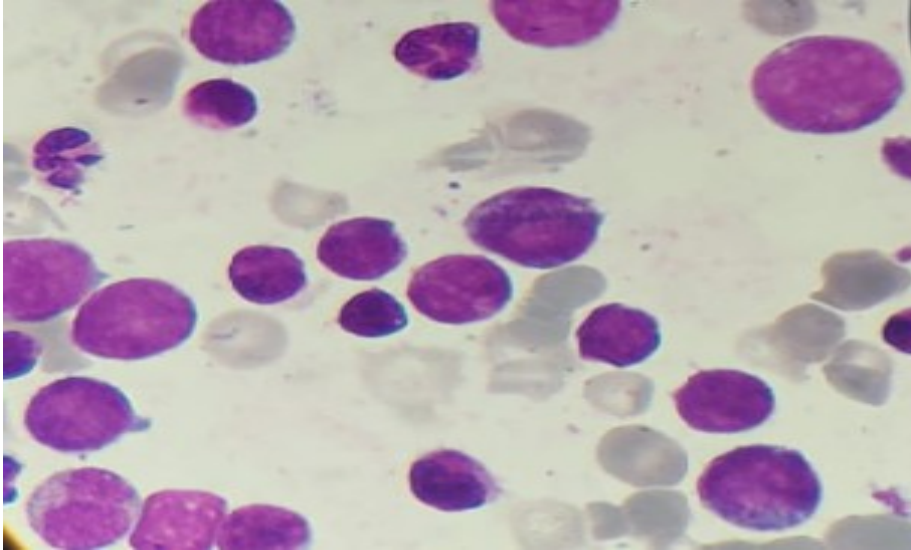


Figure 2: Cytological appearance of CML in blastic phase

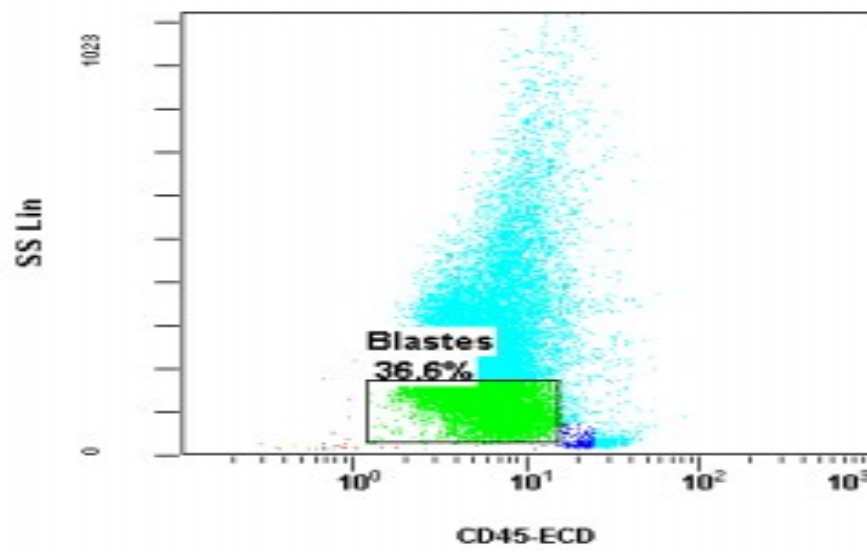


Figure 3 : Biparametric representation of CD45/SS objective blast population estimated at 36%.

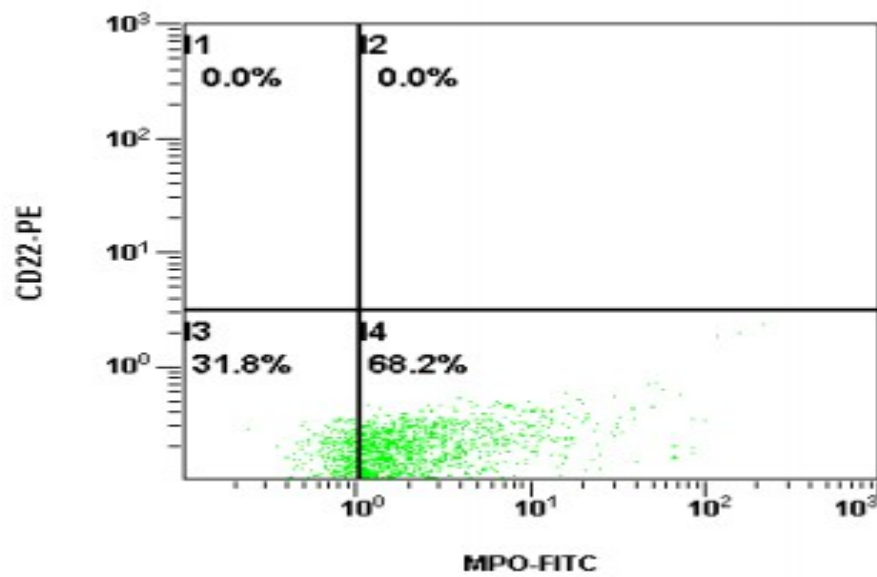


Figure 4 : Bi-parametric histogram shows a positive myeloperoxidase.