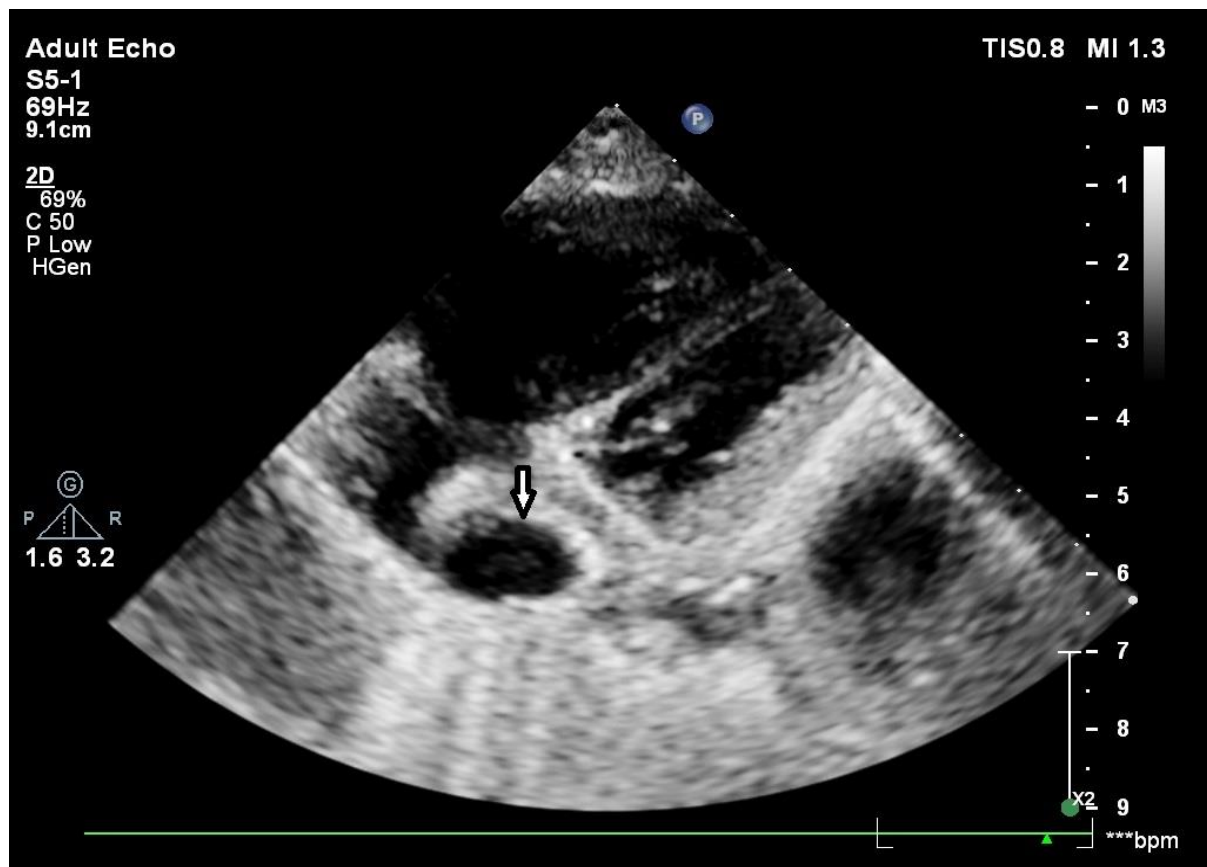
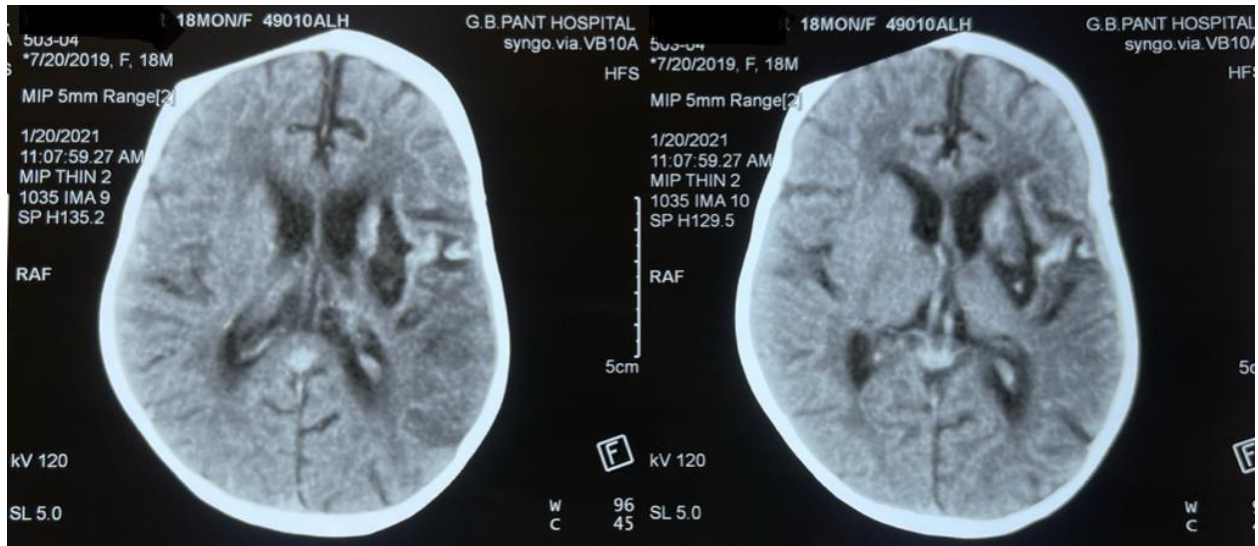
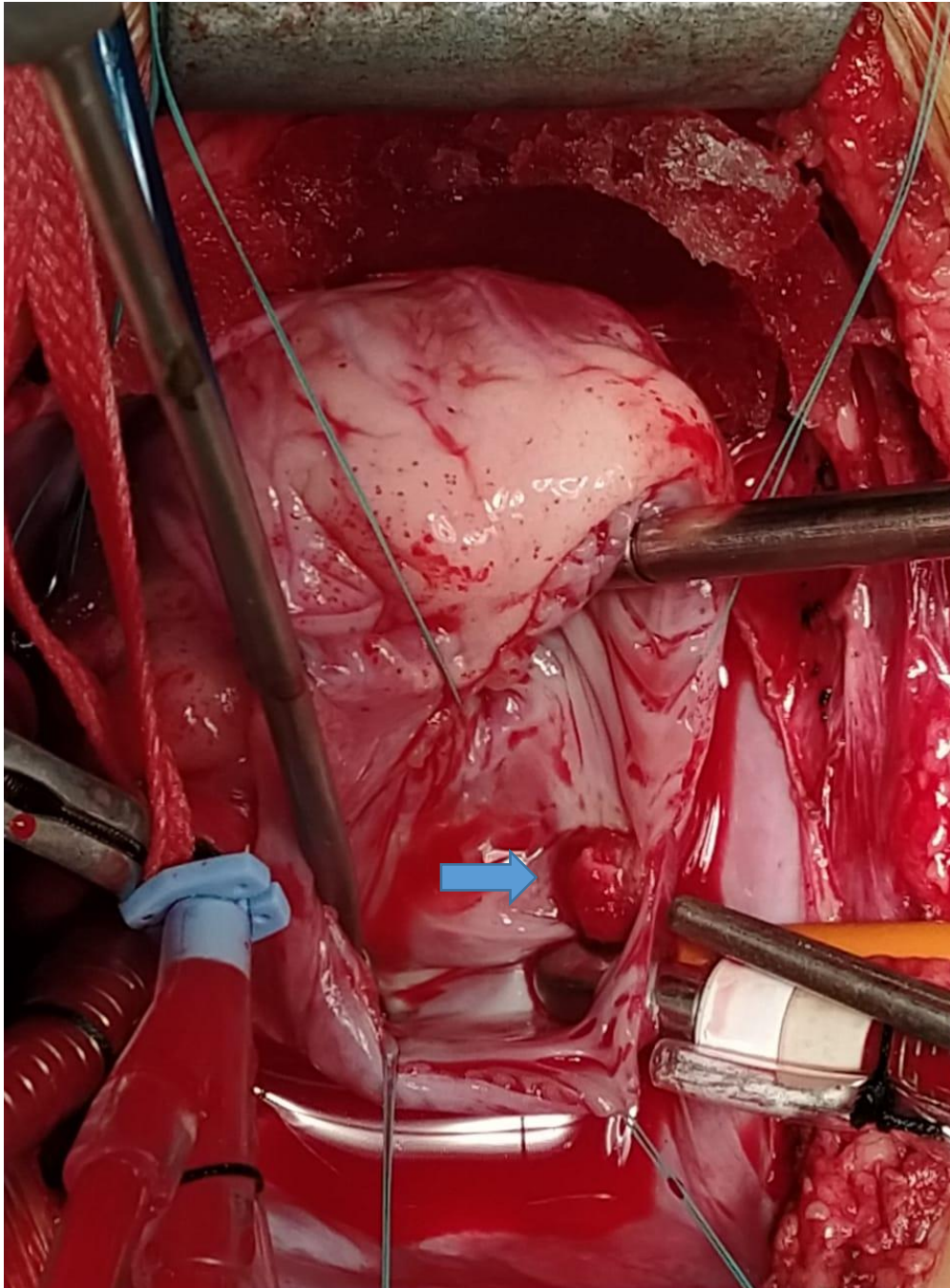


2D-ECHO PSAX view showing right atrial thrombus (white arrow)



NCCT brain showing left gangliocapsular infarct





Intraoperative photo showing thrombus near IVC opening (blue arrow)

