

Lessons from a patient with tetralogy of Fallot, dextrocardia and cardiac arrest

Lin Manxin, Zhu Kailun, Chang Dong, Li Qiang
Xiamen Cardiovascular Hospital, Xiamen University

Corresponding author: Li Qiang

E-mail: liqiang@xmu.edu.cn Tel: +8615359293670

Abstract

We report a rare case with a history of tetralogy of Fallot with dextrocardia, who presented with palpitation and cardiac arrest upon admission. This unusual complex condition and the atypical symptoms obscured the primary cause of his cardiac arrest and posed challenges on his diagnosis and treatment along with concomitant cardiac arrhythmias.

Key words: tetralogy of Fallot; dextrocardia; cardiac arrest; ventricular fibrillation

Clinical Case

The patient was a 43-year-old male with a history of tetralogy of Fallot (TOF) with dextrocardia who underwent surgical repair 20 years ago (previous medical records unavailable). He had suffered from episodes of palpitation for four years before seeking medical help from local hospitals and was prescribed amiodarone and beta-blockers, none of which alleviated his symptoms. He came to our center for further examinations and collapsed during his first visit to the clinic. Medics found that he was pulseless and had developed incontinence. Immediate cardiopulmonary resuscitation was performed and electrocardiogram (ECG) showed ventricular fibrillation (VF) (Figure 1A). He was admitted soon after defibrillation and went through thorough check-up.

The patients had nephrectomy 13 years ago due to trauma to his left kidney. He denied other significant past medical history and denied smoking or alcohol abuse. CBC, myocardial enzymes, and thyroid hormone levels appeared to be normal upon admission, and apart from the elevated creatine level of 141.7 μ mol/L, uric acid level of 569.2 μ mol/L and a slightly lowered potassium level of 3.49mmol/L, serum biochemistry was within normal range. The NT-proBNP level was 1789pg/L (reference range <125pg/L) and the hs-cTnT level was 109.9pg/L, slightly elevated (reference range <100pg/L) but dropped to 77.34pg/L the very next day. ECG showed notched P wave, prolonged PR interval and T wave inversion in Lead V5-6 with reversed limb leads and chest leads placement, which are thought to be related to his TOF and dextrocardia (Figure 1B). Echocardiogram showed dextrocardia, status post VSD repairment, mild regurgitation of the mitral valve and tricuspid valve, significantly enlarged right atrium (RA) and ventricle (RV) with a broadened RVOT of 17mm and an LVEF of 46% (Simpson's). The echo also detected *situs inversus totalis*. His chest X-ray showed right-deviated cardiac silhouette (Figure 2A). Holter was performed but showed no signs of arrhythmia other than 173 premature ventricular contractions (PVC) and 196 premature atrial contractions (PAC).

The patient was a middle-aged man with few cardiovascular risk factors and no family history of cardiovascular diseases. He presented with palpitation rather than chest pain or shortness of breath, and his symptoms weren't related to or aggravated by effort. Since he only had one kidney left and his creatine level had already risen,

the patient refused coronary angiography after a thorough discussion of pros and cons with the attending doctors. Implantable cardioverter-defibrillator (ICD) was then suggested to prevent future episodes of malignant arrhythmias and a single-chamber ICD was implanted successfully on January 25th, 2017 (Figure 2A).

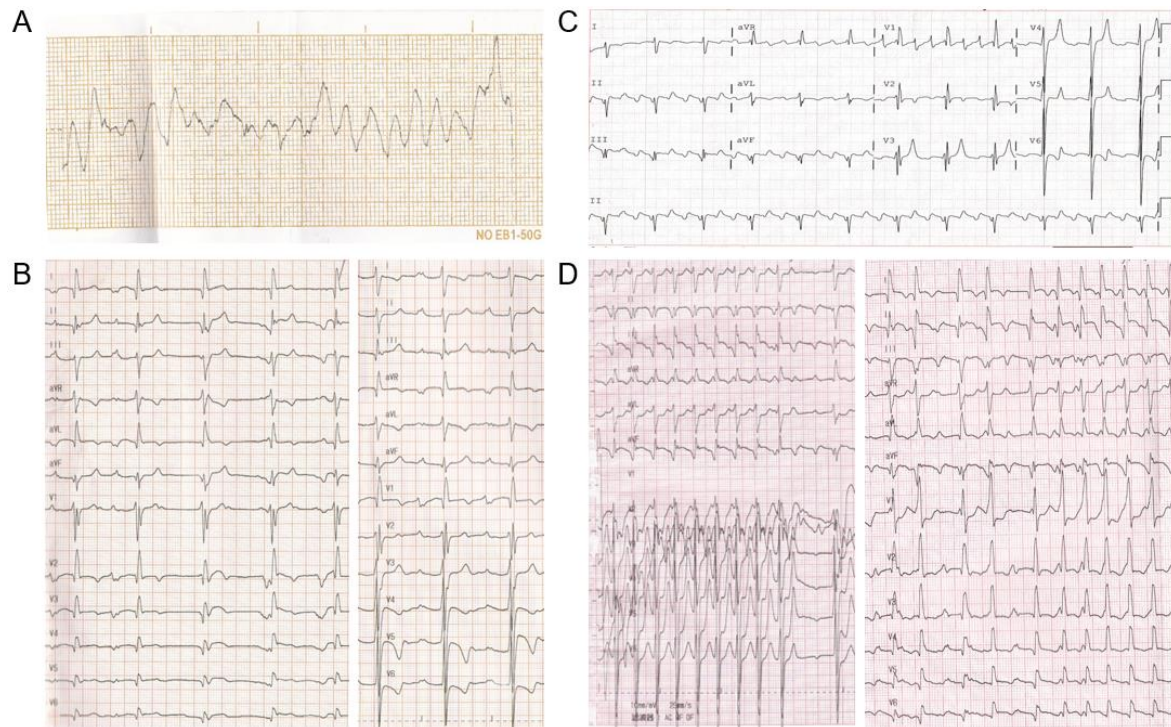


Figure 1: ECGs from this case. **A:** ECG on Jan 18th, 2017 showing ventricular fibrillation before defibrillation. **B:** ECGs upon admission. Left: Normal limb leads and chest leads placement. Right: Reversed limb leads and chest leads placement. **C:** ECG showing AFL. **D:** ECGs on July 30th, 2018. Left: Normal limb leads and chest leads placement. Right: Reversed limb leads and chest leads placement.

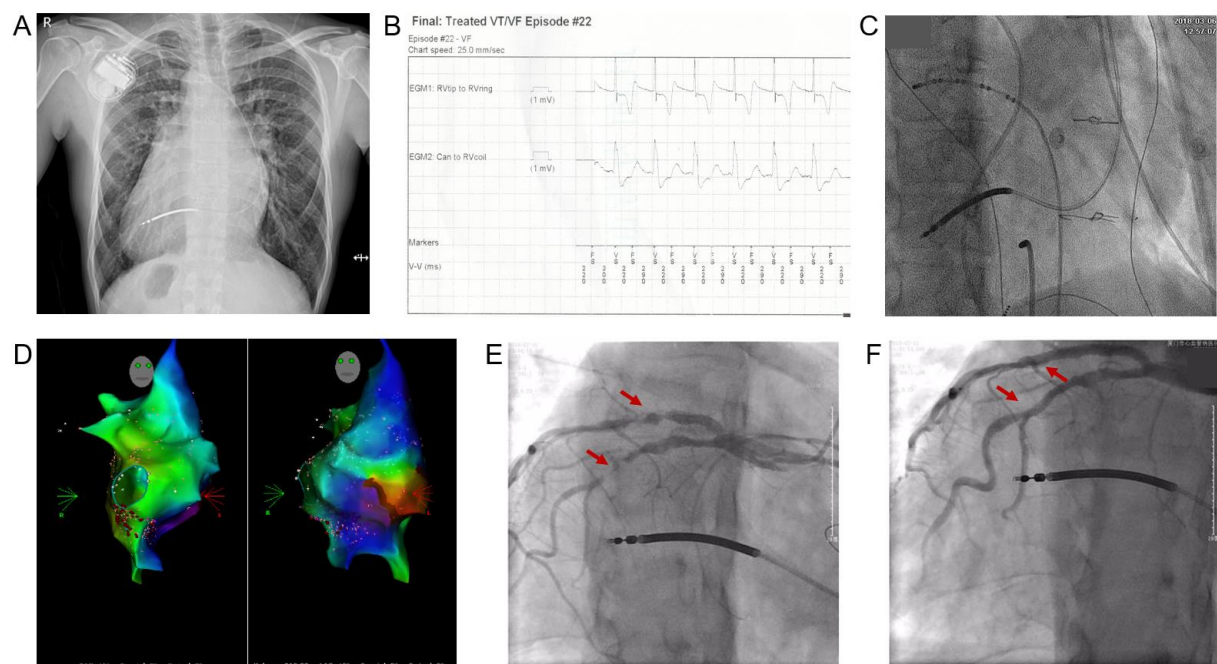


Figure 2: **A:** X-ray post ICD implantation showing right-deviated cardiac silhouette. **B:** Record extracted from the ICD mistaking AF for VF. **C:** Fluoroscopy during electrophysiology study. **D:** Mapping during radiofrequency ablation. **E and F:** Results from the coronary angiography, before (E) and after (F) stent implantation.

For almost 1 year the patients didn't experience any symptoms while taking bisoprolol after discharged from the hospital. However, he developed palpitation, chest tightness and asthenia on January 2nd and March 2nd of 2018 and his ICD discharged. He then came in for ICD programming and testing, which revealed episodes of 'VF' with a rate of >222bpm, which is later confirmed to be atrial flutter (AFL) with T wave oversensing (Figure 2B). The ECG he brought in from another hospital was consistent with atrial flutter, too (Figure 1C).

Electrophysiology study was then performed on March 6th and confirmed the presence of cavo-tricuspid isthmus dependent atrial flutter (AFL). Linear ablation of the tricuspid annulus isthmus was performed successfully despite the unique structure of his heart due to surgical repair of tetralogy of Fallot and dextrocardia (Figure 2C and 2D). Excited mapping confirmed complete bidirectional isthmus block. Warfarin was then prescribed.

However, 4 months after the procedure, the patient developed paroxysmal palpitation and chest tightness with perspiration that resolved after 10 minutes. The symptoms sometimes radiated to his left shoulder and aggravated for one week before he sought medical help on July 30th, 2018. The ECG upon admission showed atrial flutter with ST elevation in Lead II and aVF, ST depression in Lead V1-2 and T wave inversion in most limb leads (with limb leads and chest leads placement reversed). The emergency hs-cTnT level was 1522pg/L (reference range <100pg/L) and the NT-proBNP level was 10872pg/L (reference range <125pg/L). All the evidence pointed to acute coronary syndrome. Dual antiplatelet therapy was prescribed and coronary angiography was performed, discovering a 90% stenosis in proximal left anterior descending artery (LAD) and a 90-95% stenosis in proximal left circumflex artery (LCX). A *Firebird2* (3.5×23mm) stent was implanted in the LAD and a *Partner* (2.75×24mm) stent was implanted in the LCX, respectively (Figure 2E and 2F). The patient then received strict secondary prevention treatment of coronary heart disease and experienced no cardiovascular events to date.

Discussion

Much can be learned from this rare and complex case. Tetralogy of Fallot (TOF) is an uncommon structural heart disease that makes up 7-10% of all congenital heart diseases, and is characterized by four major features: right ventricular outflow tract (RVOT) obstruction, ventricular septal defect (VSD), deviation of the origin of the aorta to the right so that it overrides the VSD, and right ventricular hypertrophy. Tetralogy of Fallot with concomitant dextrocardia and *situs inversus* is extremely rare. There are only a few reports on this combination and was first described in 1952 by Scragg and Denny [1]. These structural abnormalities can cause distinctive changes in ECGs and echocardiograms. ECG in TOF with dextrocardia may show right atrial enlargement and ventricular hypertrophy, including right axis deviation, prominent R waves anteriorly and S waves posteriorly, abnormal T wave patterns and a qR pattern in the right sided chest leads. In this case, the patient was a middle-aged man with few cardiovascular risk factors. His ECG showed notched P wave, prolonged PR interval and T wave inversion in Lead V5-6 that are thought to be related to his TOF and dextrocardia. The initial echocardiogram also didn't demonstrate any focal wall motion abnormalities and the global hypokinesis detected by the echocardiogram was expected to be the result of cardiac arrest.

Tracing back his lab results, his LDL-C level ranged from 2.14 to 2.99 mmol/L, and his HDL-C level ranged from 0.45 to 1.08 mmol/L. Moreover, his serum troponin levels were within normal range during his first two visits. He was not considered of high risk for coronary heart disease and his symptoms were masked by the coexisting atrial flutter. Even so, the attending doctors should have ruled out coronary heart disease first when dealing with patients with prior cardiac arrest.

Acute myocardial infarction, cardiomyopathy and malignant arrhythmia are the common causes for cardiac arrest, with ischemic heart disease being the most common cause [2]. A series of diagnostic tests should be performed to investigate the primary cause of the cardiac arrest following successful resuscitation, including laboratory tests, ECG and imaging studies. Physicians should be especially alert for signs of ST-elevation, ST-depression, abnormal T waves or new left bundle branch block. Abnormalities of conduction intervals, electrical axis and QT interval may provide extra clues to the etiology. There has been evidence that coronary angiography is strongly and independently associated with survival in patients that experienced previous out-of-hospital cardiac arrest without ST-elevation, regardless of whether PCI was performed[3], even though in patients without ST-elevation, performing coronary angiography after neurological recovery is also justifiable [5]. Physicians can never be too cautious when looking for the primary cause of the cardiac arrest.

Declaration of Conflicting Interests

The authors declared no potential conflicts of interest with respect to the research, authorship, and/or publication of this article.

Funding

This work was supported by research grant No. 3502ZZ20174005 from Huimin Project of Xiamen Municipal Bureau of Science and Technology.

Reference

- [1] Scragg, J. N. and M. Denny (1952). "Dextrocardia, tetralogy of Fallot, and situs inversus; report of a case." S Afr Med J **26**(52): 1025-1028.
- [2] Davies, M. J. (1981). "Pathological view of sudden cardiac death." Br Heart J **45**(1): 88-96.
- [3] Vadeboncoeur, T. F., et al. (2018). "Association between coronary angiography with or without percutaneous coronary intervention and outcomes after out-of-hospital cardiac arrest." Resuscitation **127**: 21-25.
- [4] Elfwen, L., et al. (2018). "Coronary angiography in out-of-hospital cardiac arrest without ST elevation on ECG-Short- and long-term survival." Am Heart J **200**: 90-95.
- [5] Spoormans, E. M., et al. (2020). "The role of coronary angiography in out-of-hospital cardiac arrest patients in the absence of ST-segment elevation: A literature review." Neth Heart J **28**(Suppl 1): 108-114.