

Figure 1

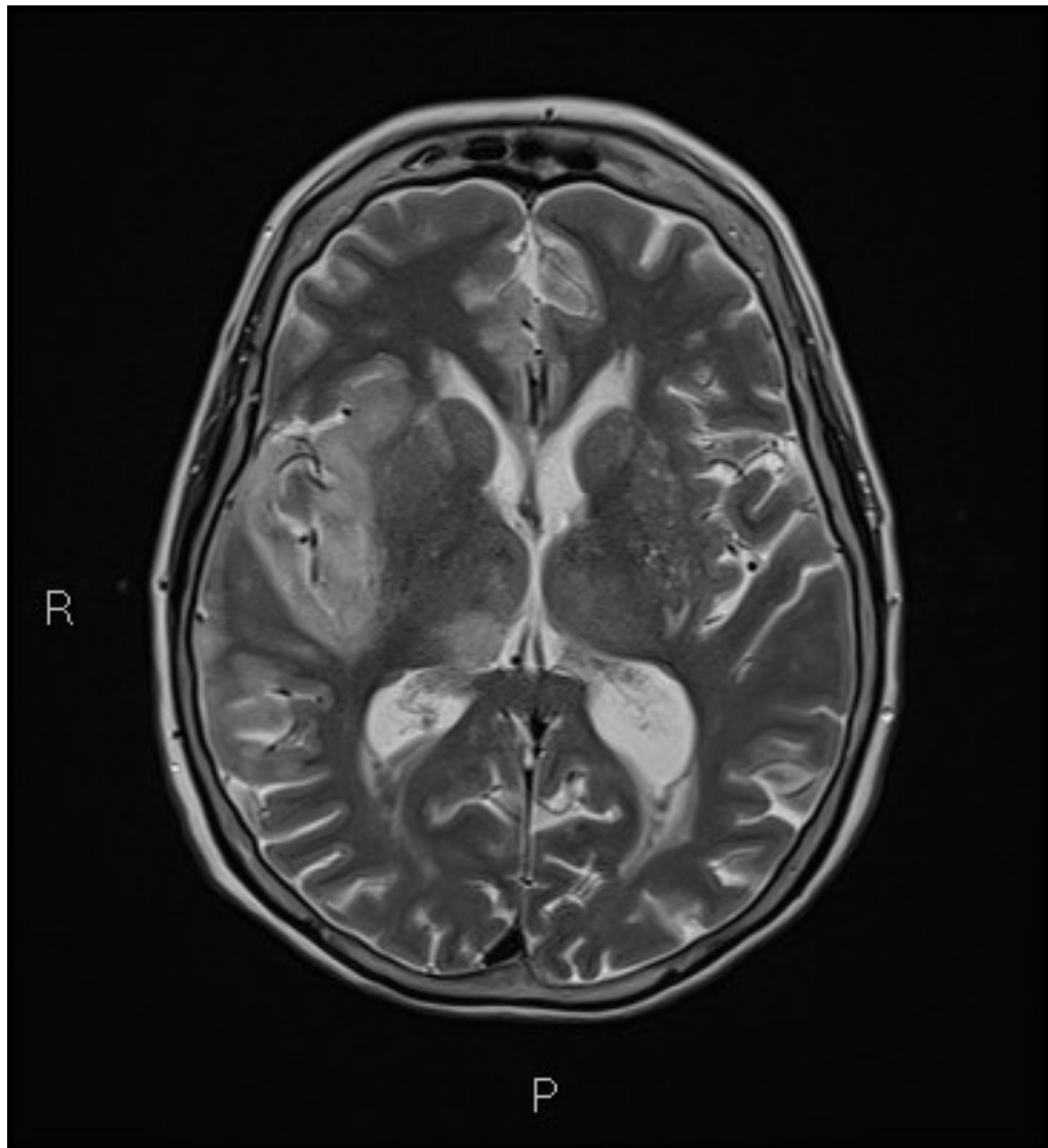


Fig. 1 Magnetic Resonance Imaging (MRI) demonstrating generalized oedematous changes of the right temporal lobe with moderate intensity restricted diffusion seen involving the gyri of the right temporal lobe and right insular regions.